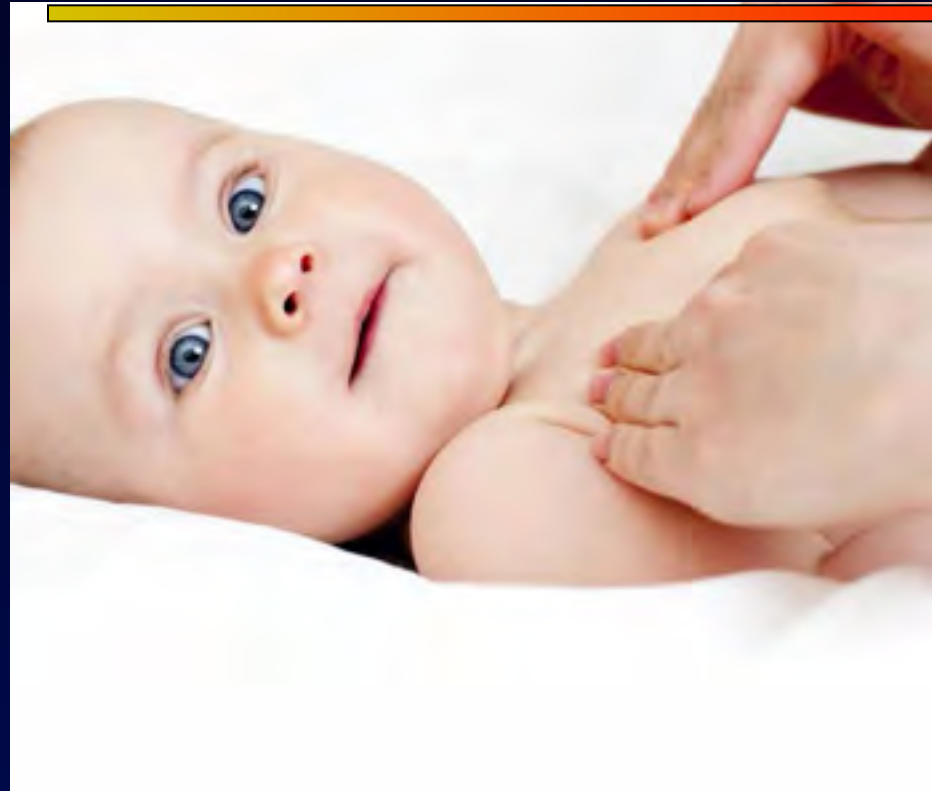

Aortic Arch Abnormalities



Norman H Silverman MD, D Sc
(Med.). FACC, FAHA.

Stanford University & Lucile
Packard Children's Hospital

E mail: norm.silverman@stanford.edu



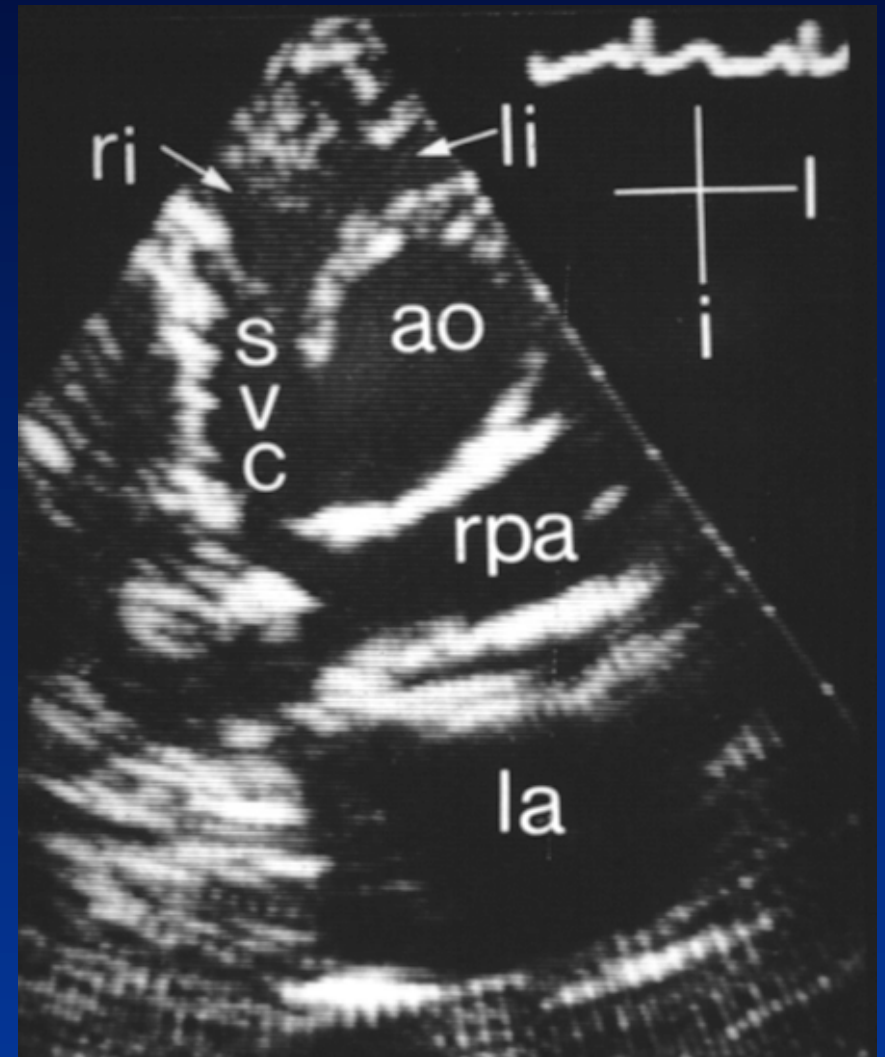
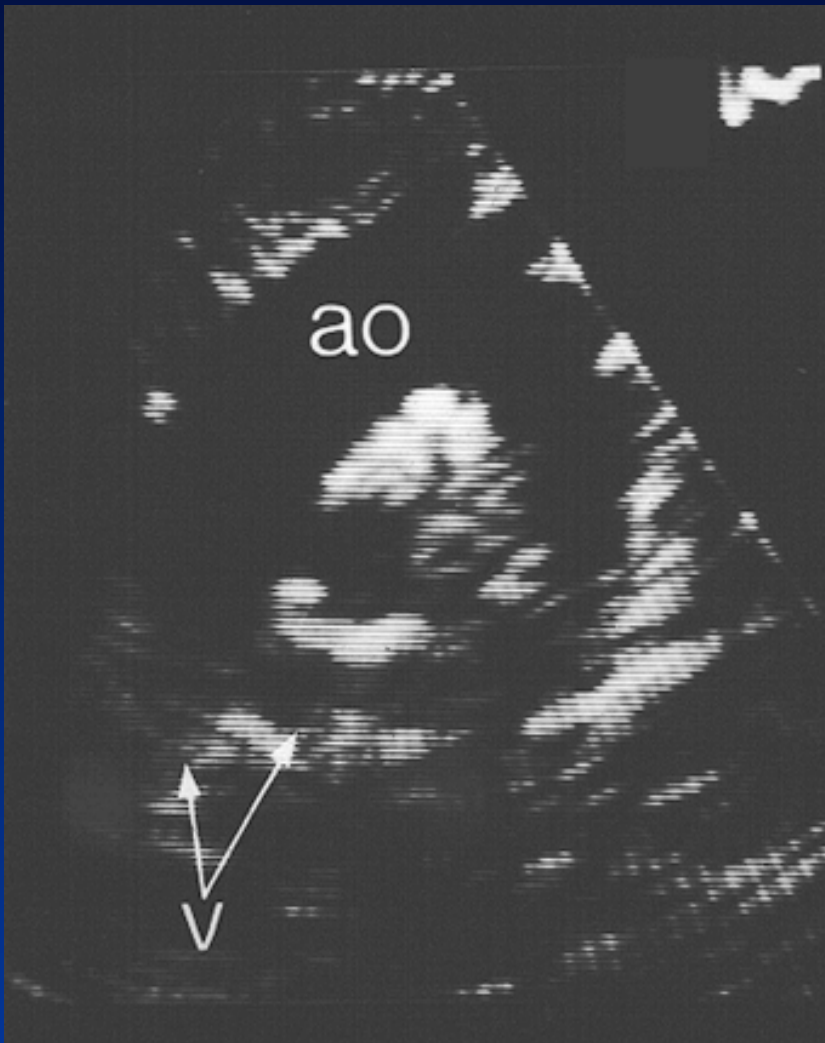
Abnormalities

- **Supravalvar Aortic Stenosis**
- **The Aortic Root in Marfan's Syndrome**
- **Interruption**
- **Hypoplasia**
- **High Aortic Arch**
- **Arch Laterality**
- **Coarctation**
- **Vascular Rings**

Examination Technique

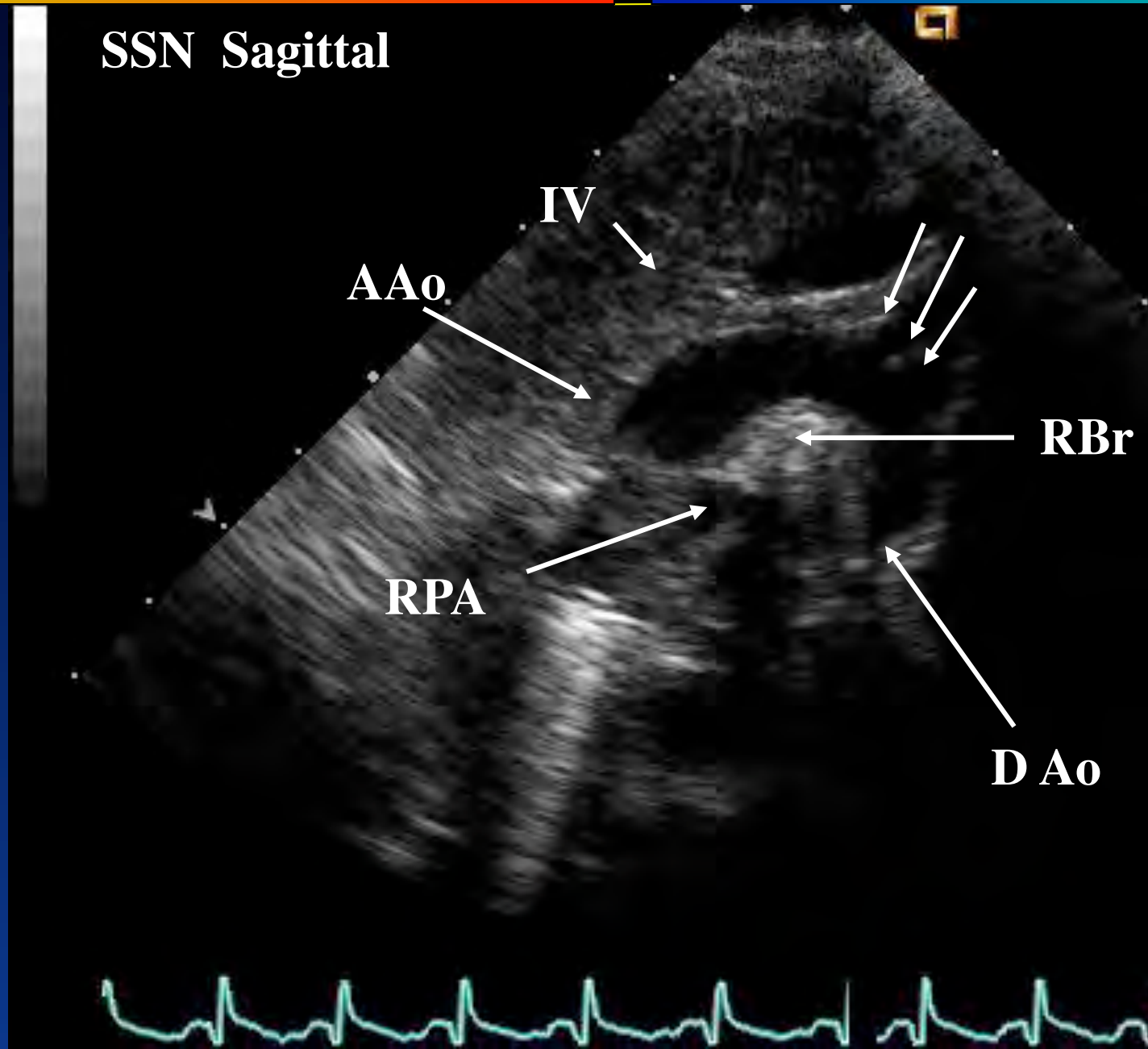
- A variety views should be used including :-
- Suprasternal coronal and sagittal imaging,
- Parasternal and
- Subcostal views of the aorta and its relations.
- The Imaging should be complemented by various Doppler modalities including Color flow imaging.

Normal Aortic Arch Echo



Normal Aortic Arch

SSN Sagittal

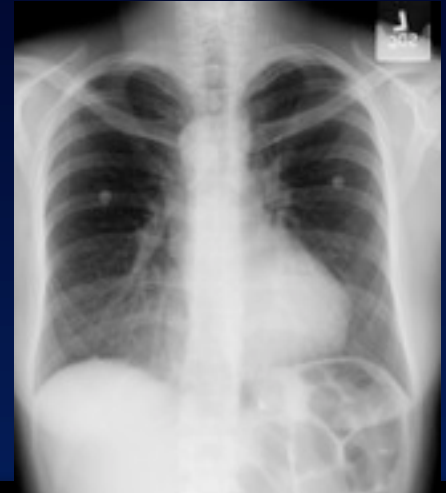
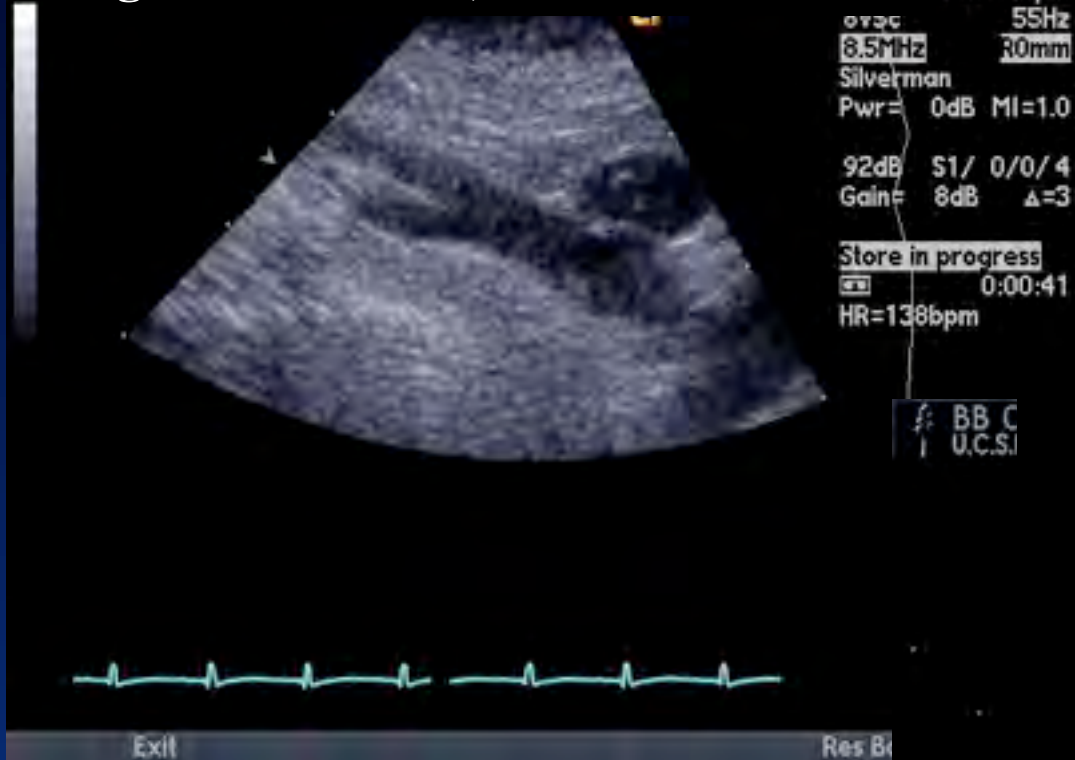
Aortic Arch Laterality

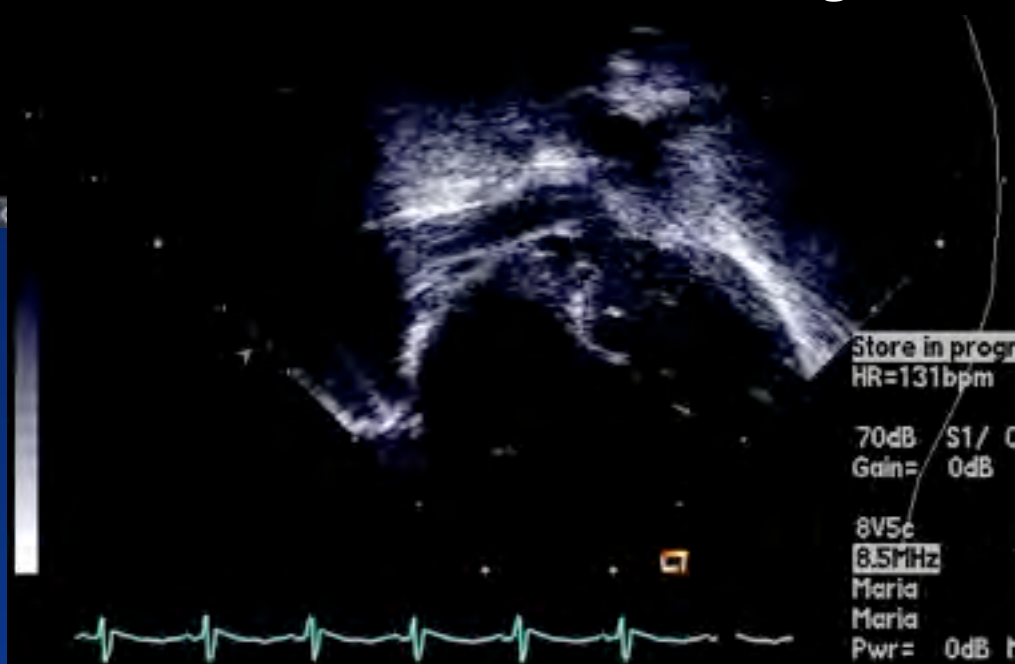
- Transducer alignment
 - The arch direction follows the plane of the array
- Innominate Artery
 - The innominate artery always bifurcates on the opposite side to the aortic arch.
 - Lack of bifurcation may indicate that there is an anomalous subclavian artery
- Tracheal Rings or Esophagus
 - The descending aorta can be recognized by the examiner either to the left (in left aortic arch) or to the right (in right aortic arch)

Innominate Artery Shows Arch Position

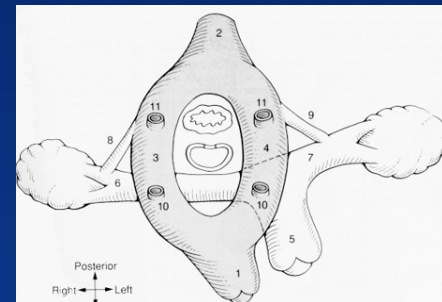
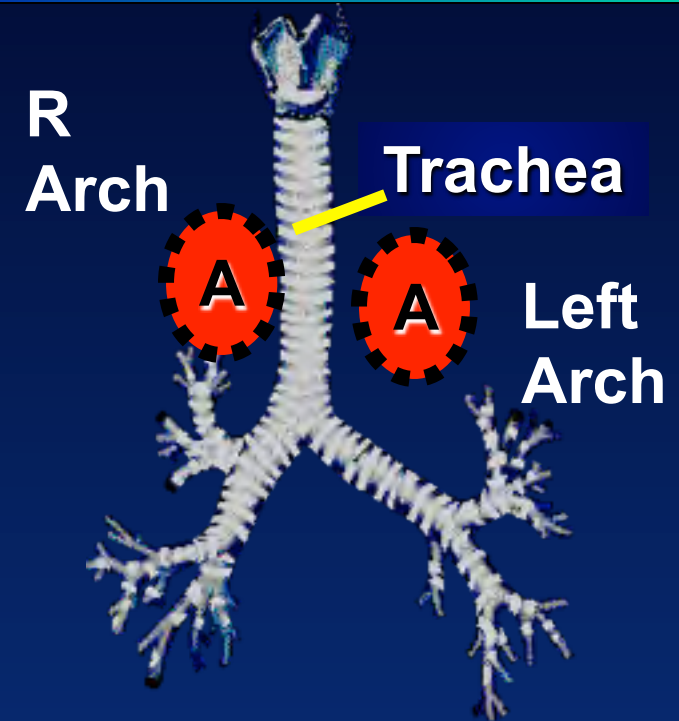
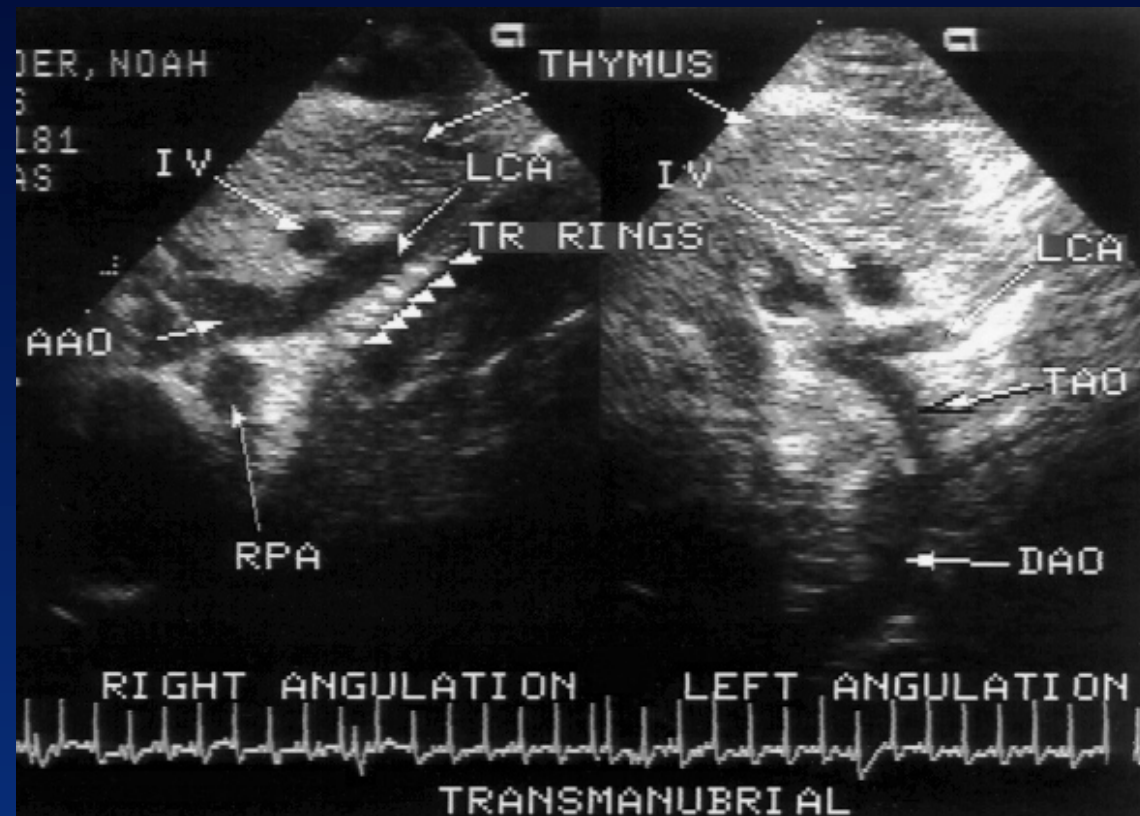
Right Innominate, therefore left arch



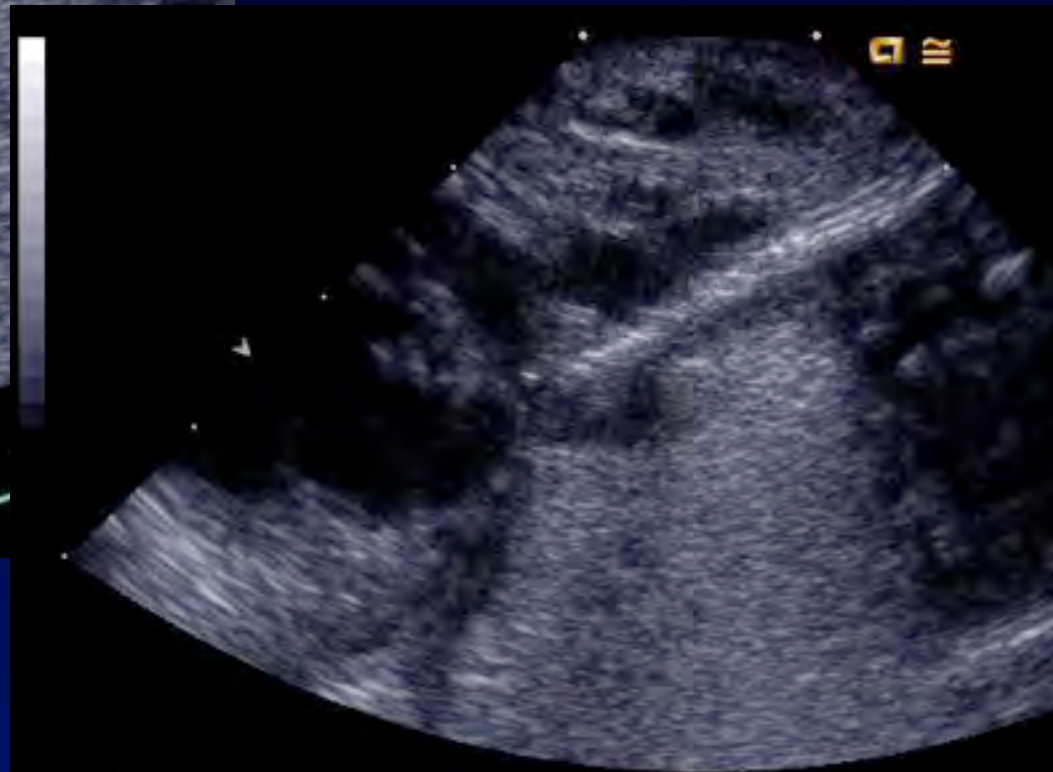
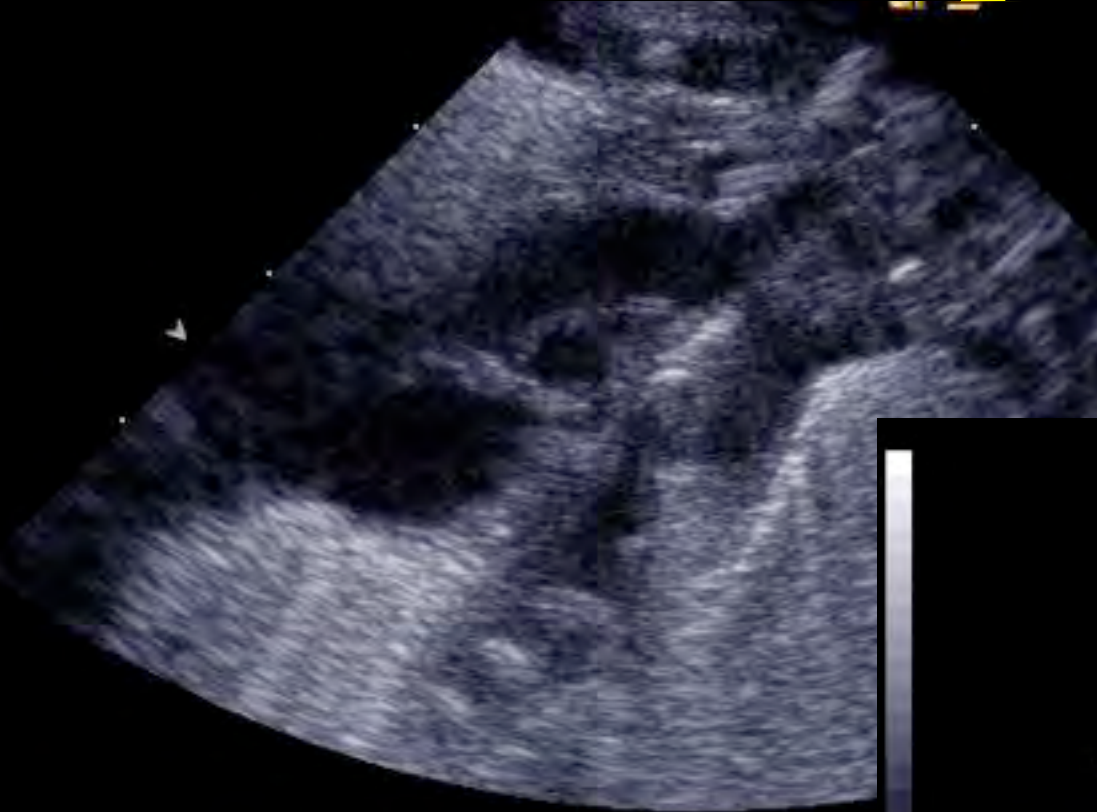
Left innominate, therefore right arch



Arch Laterality

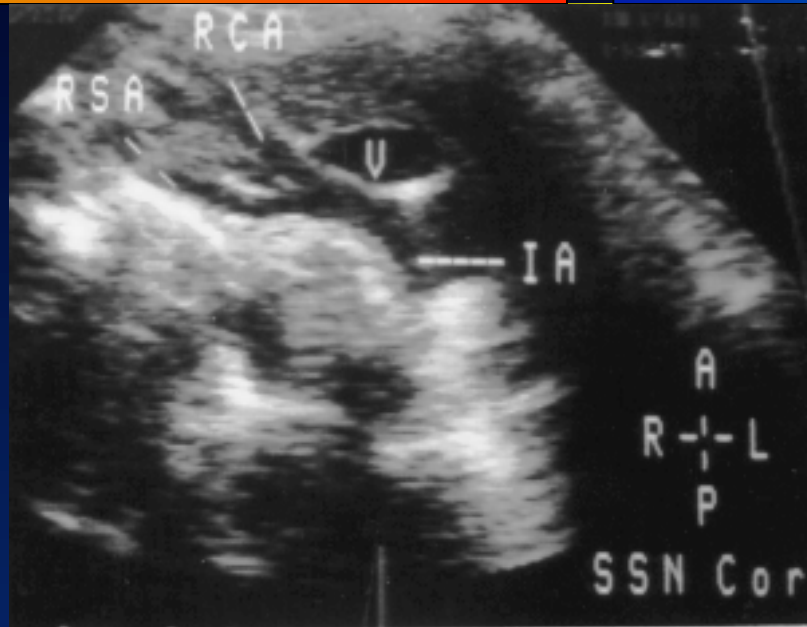


Tracheal Rings

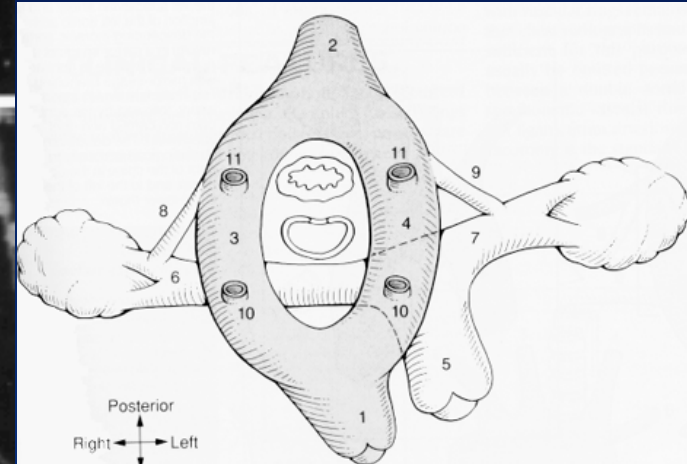
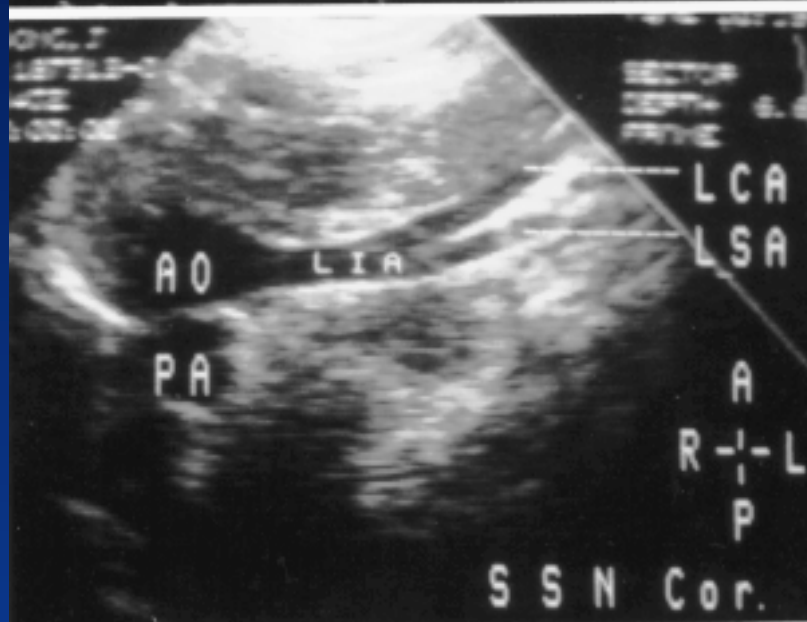


Arch Laterality

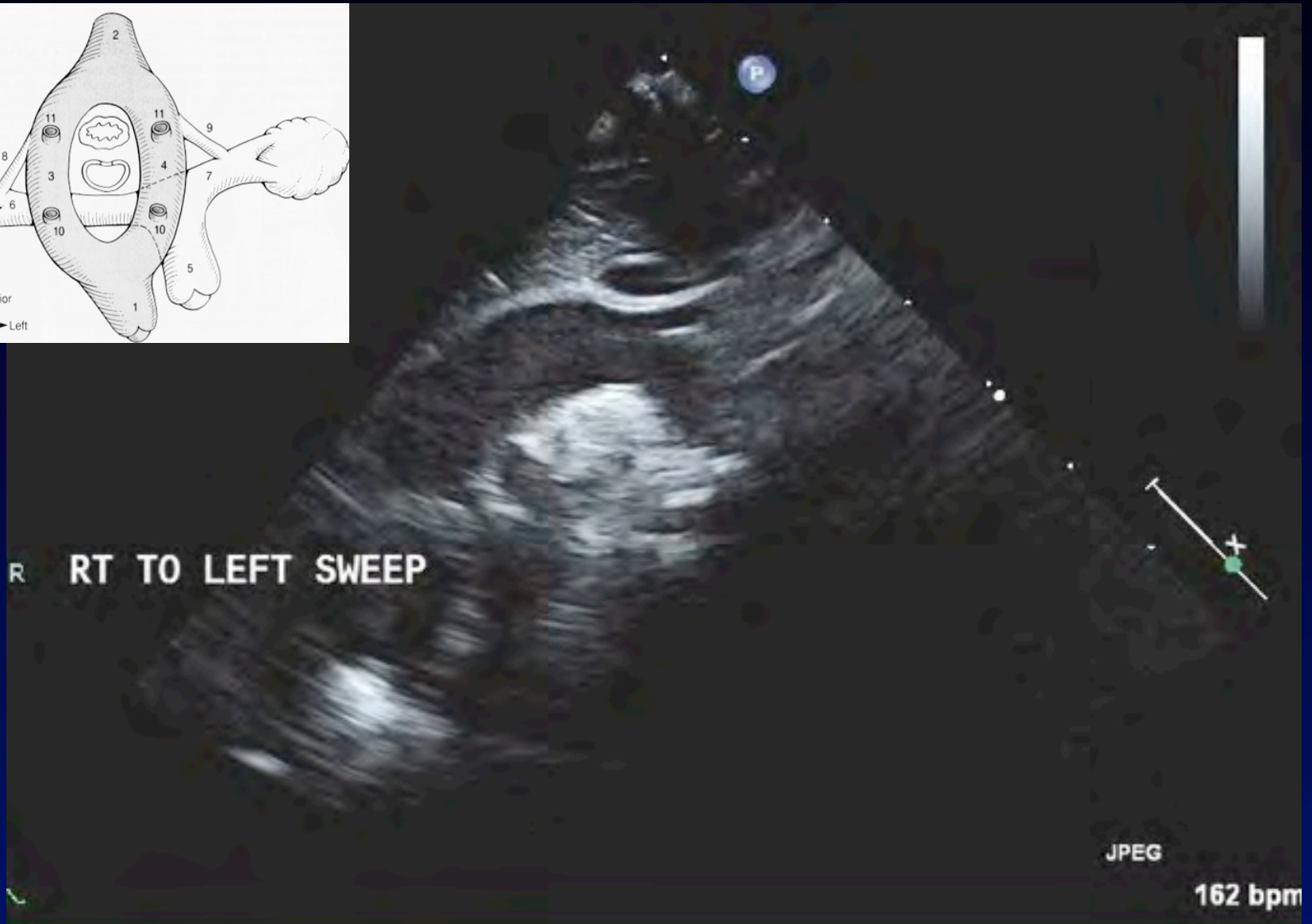
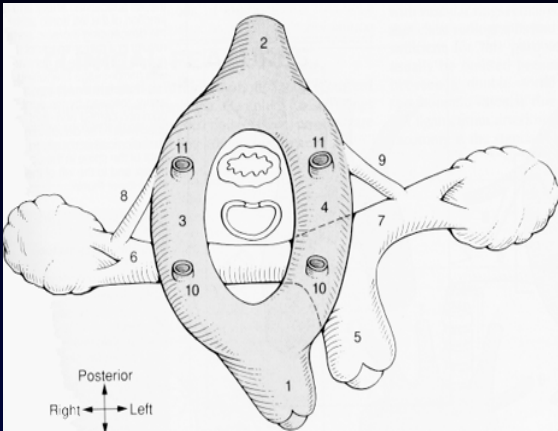
Left Arch



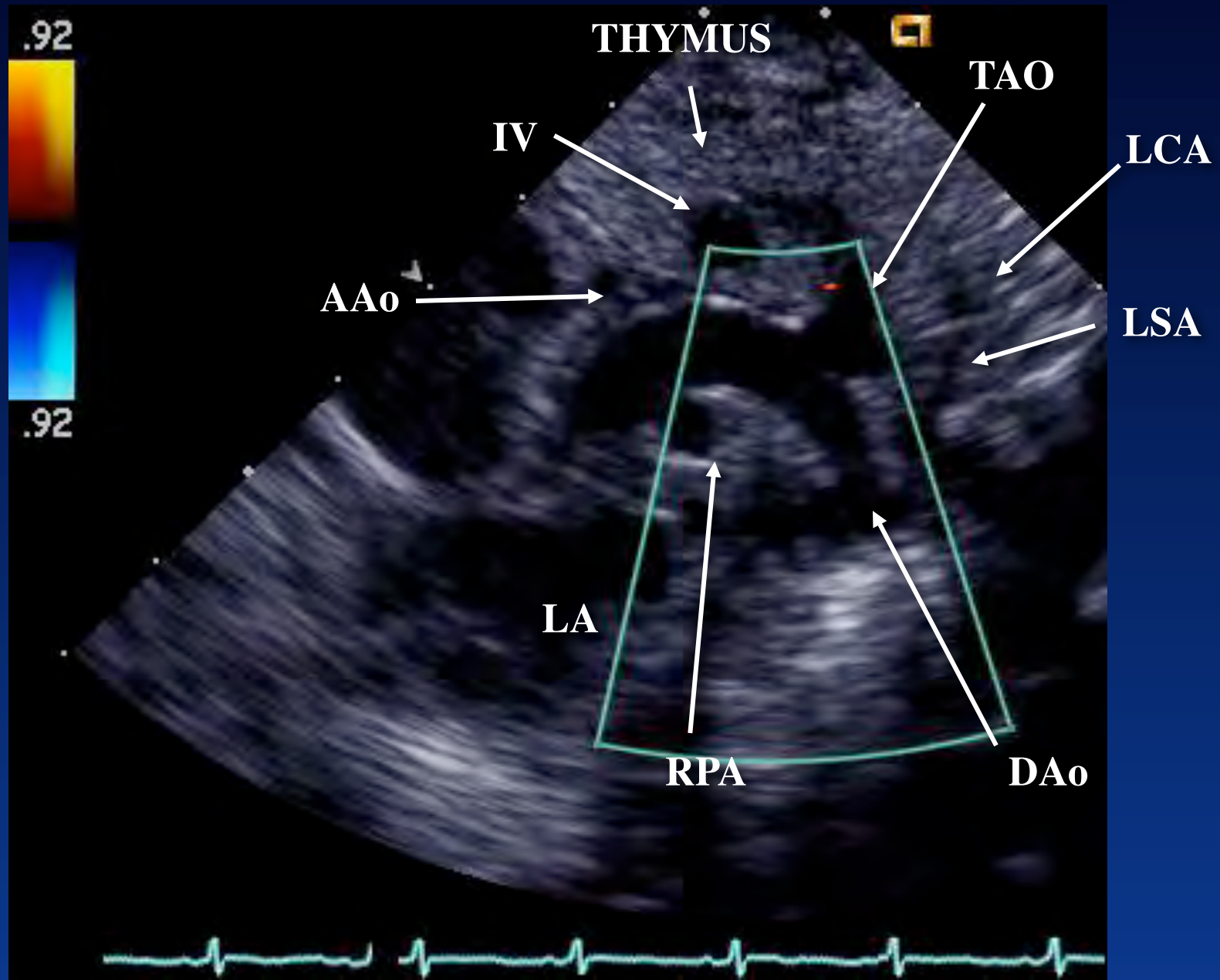
Right Arch



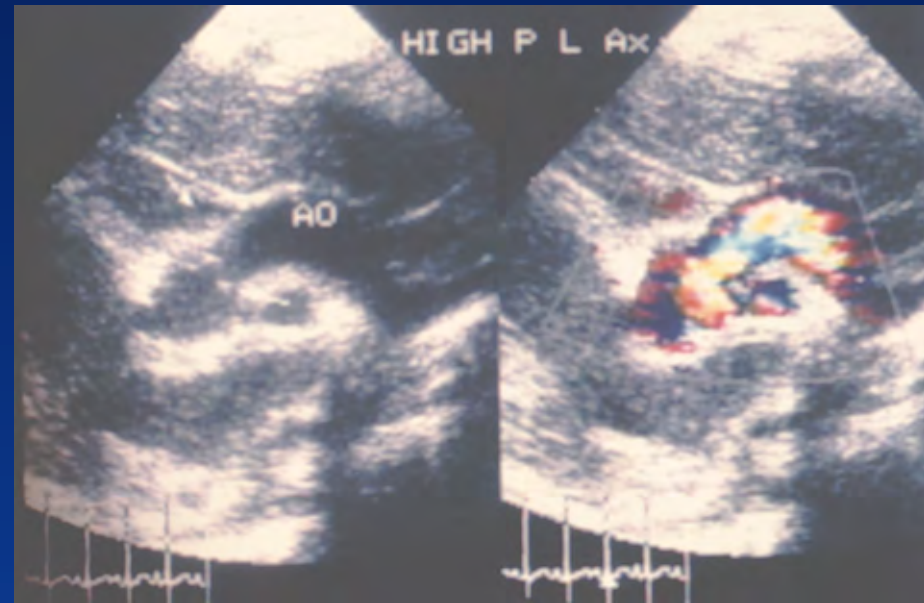
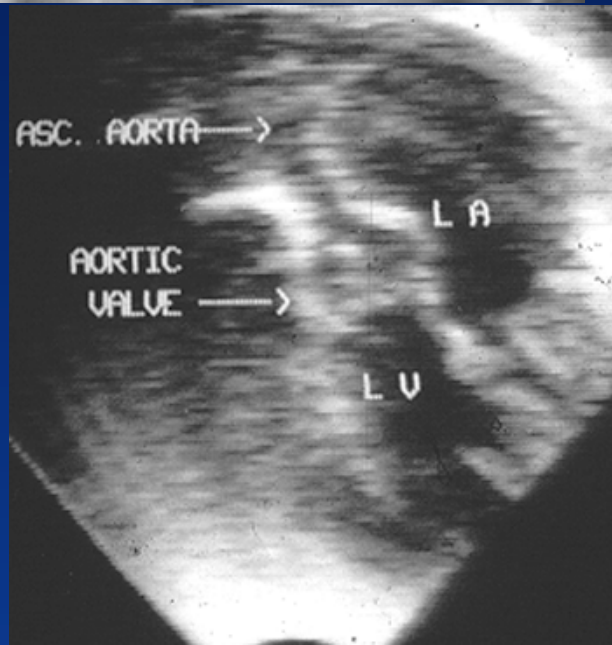
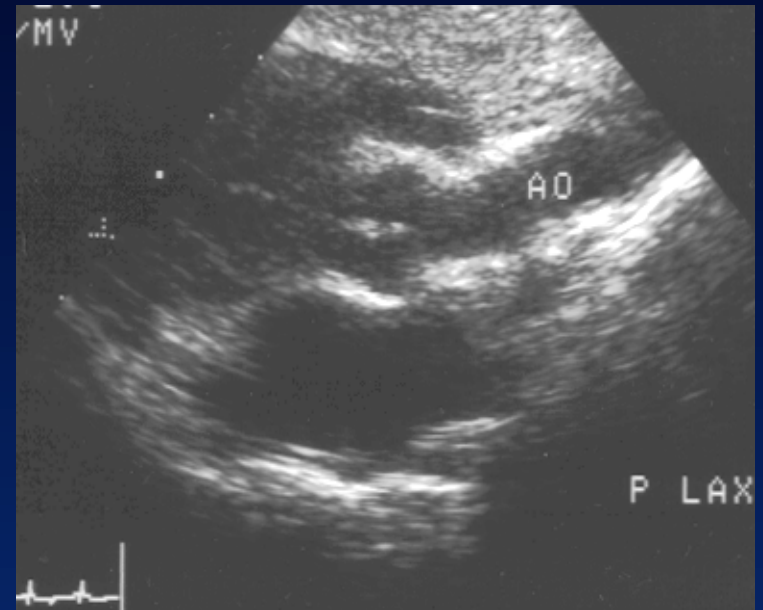
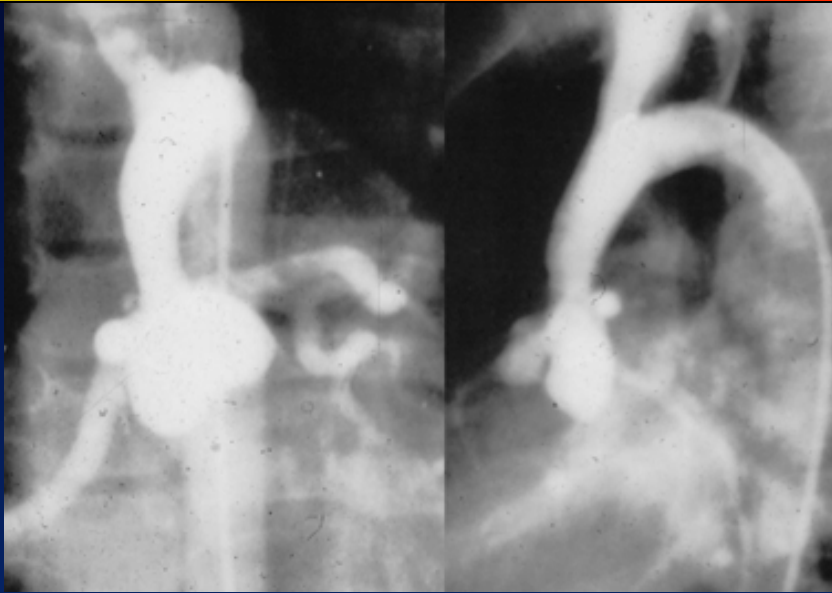
Routine Arch Sweep



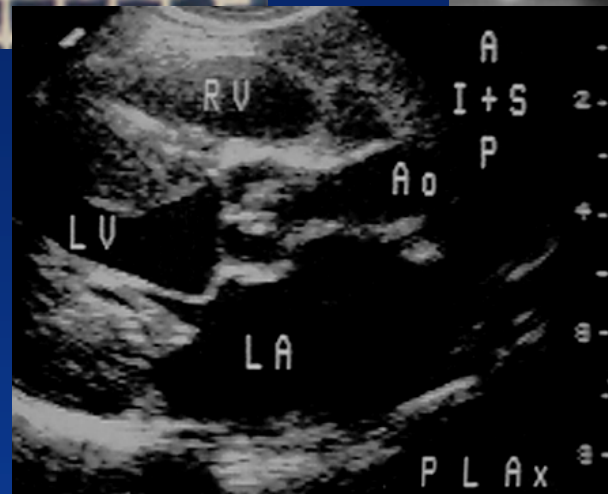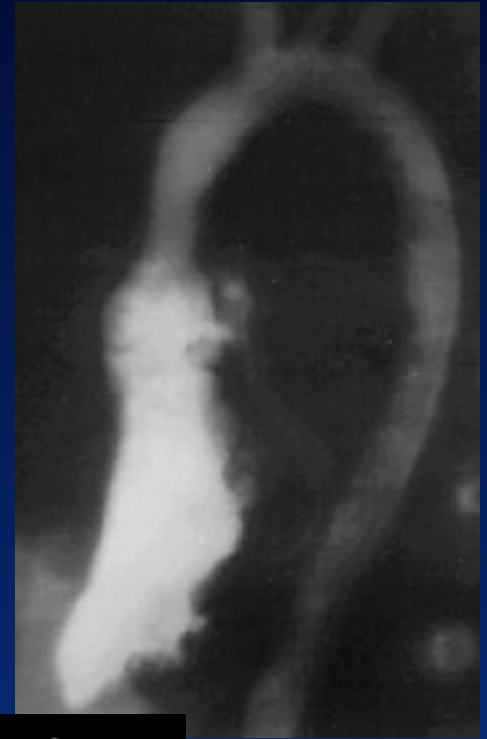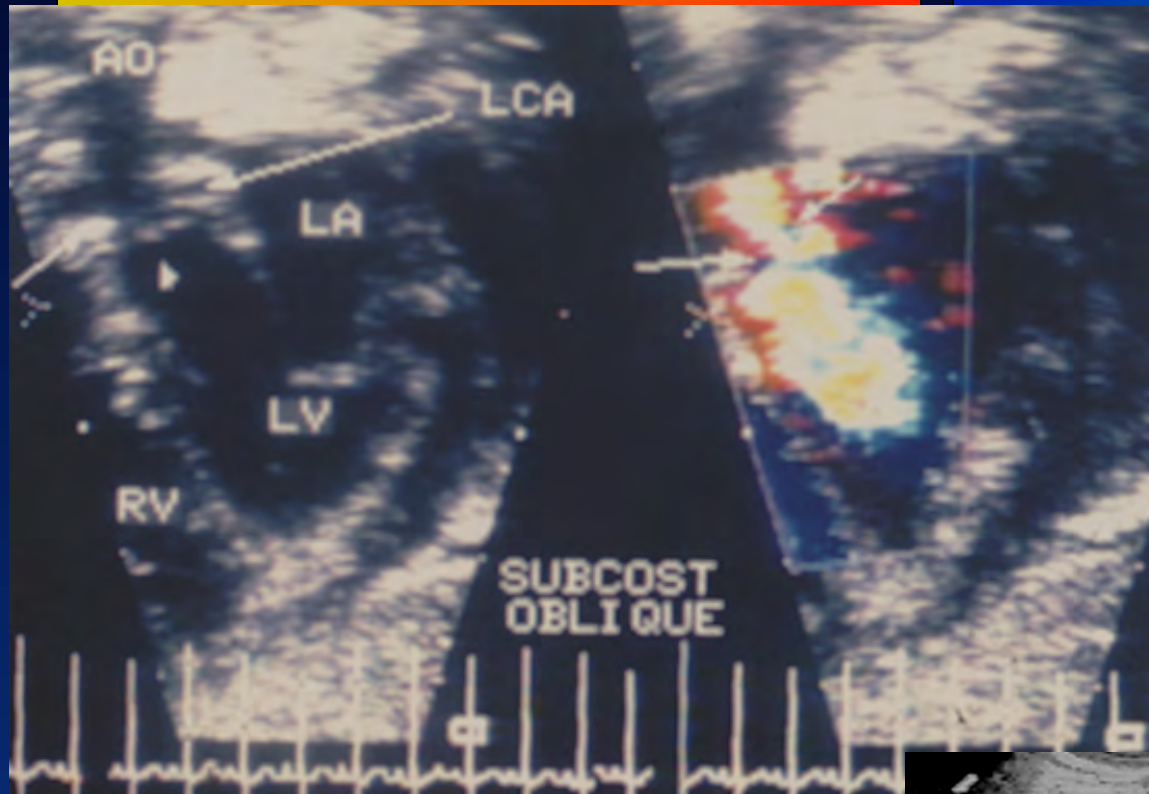
Normal Aorta: Color Imaging



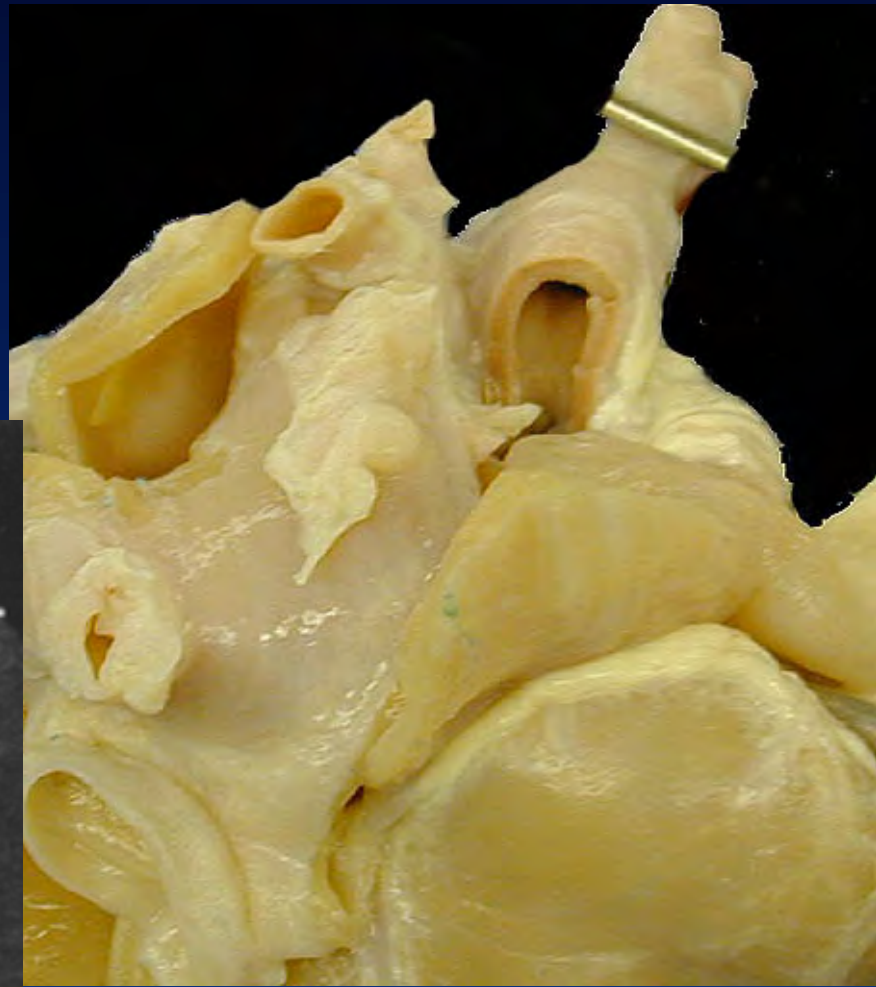
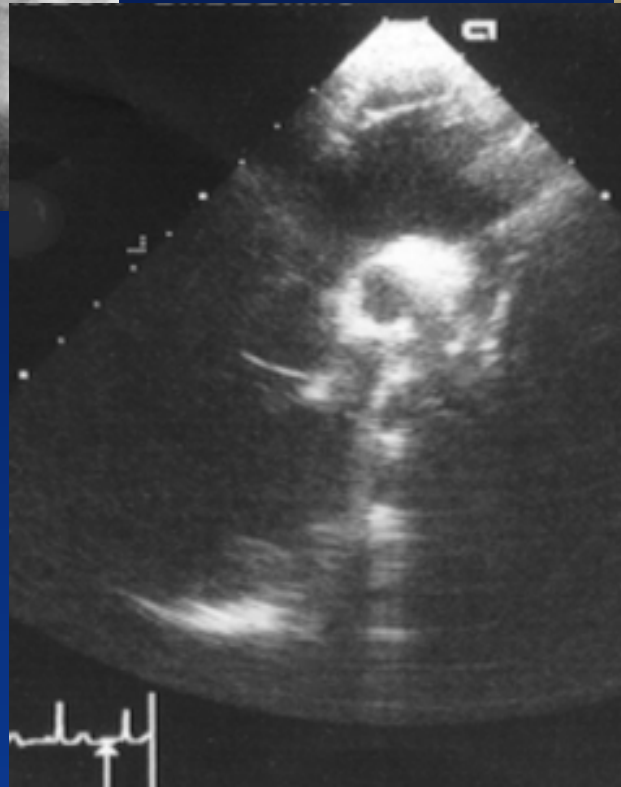
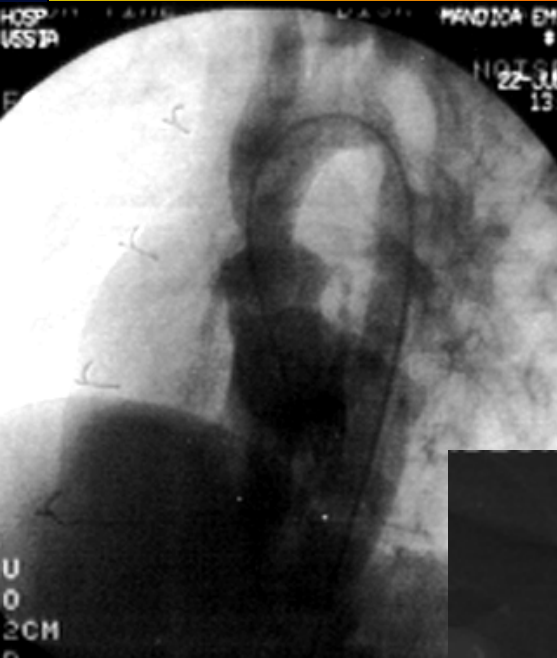Supravalvular Aortic Stenosis



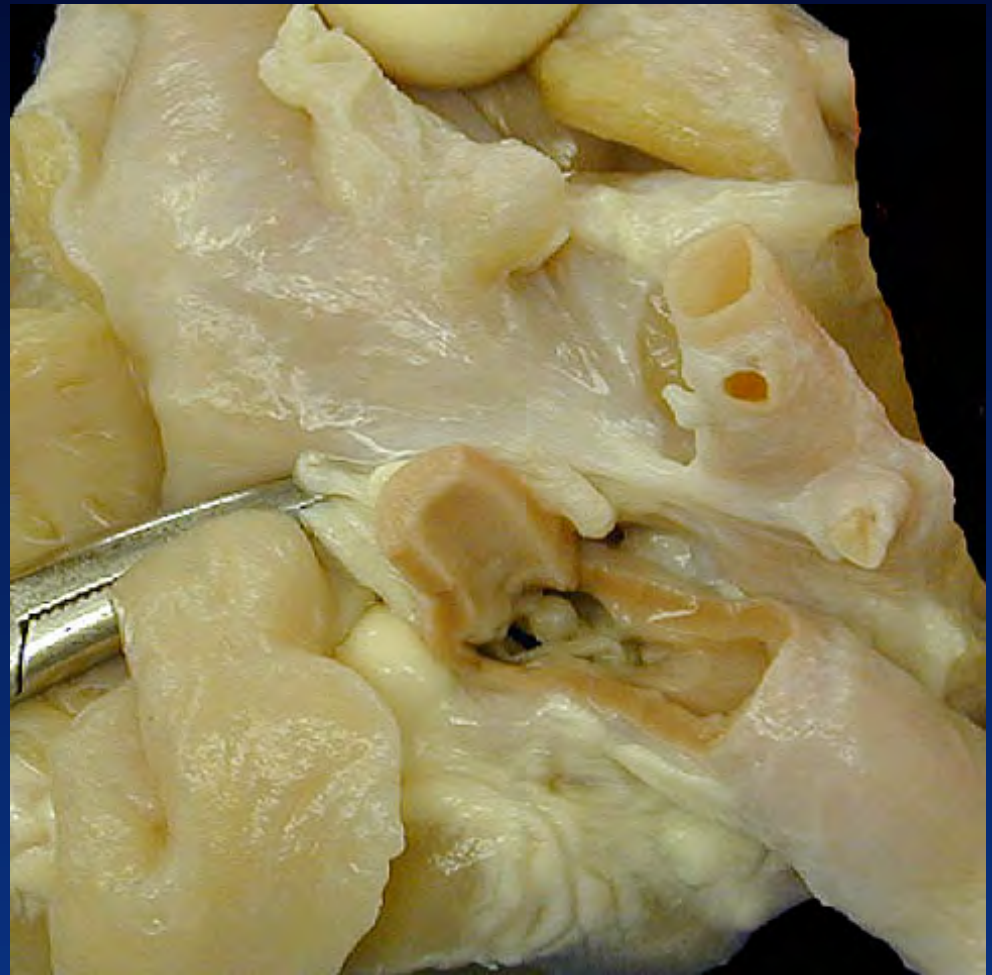
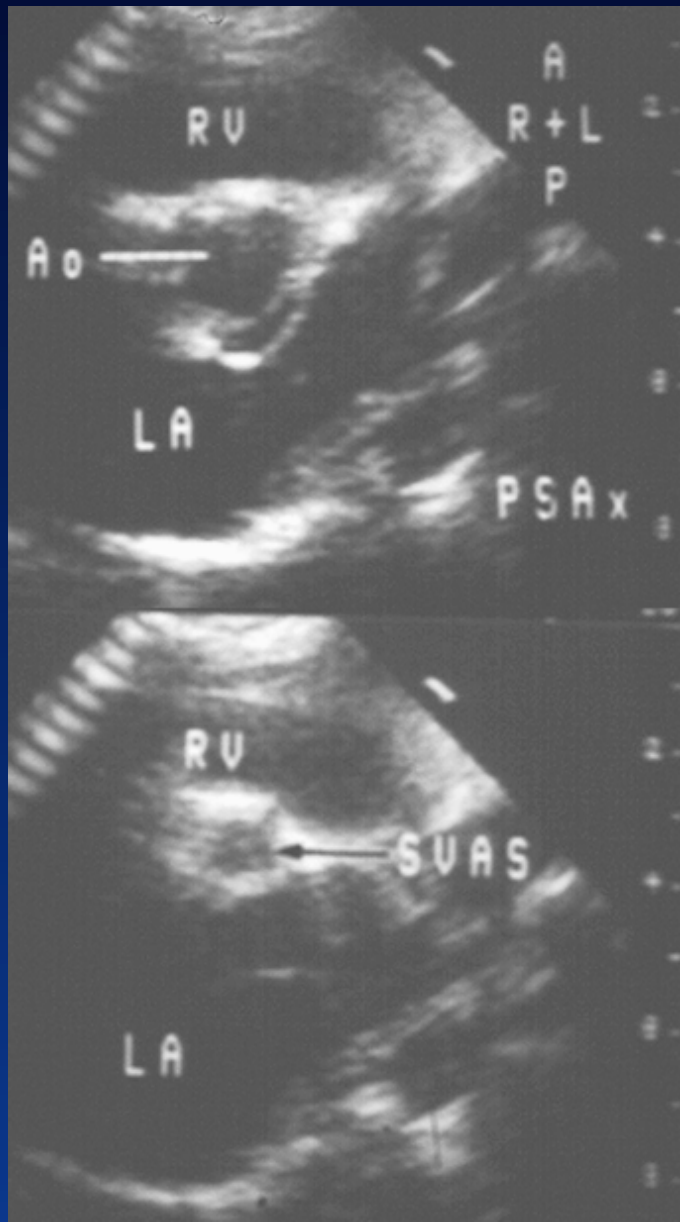
Supravalvular Aortic Stenosis



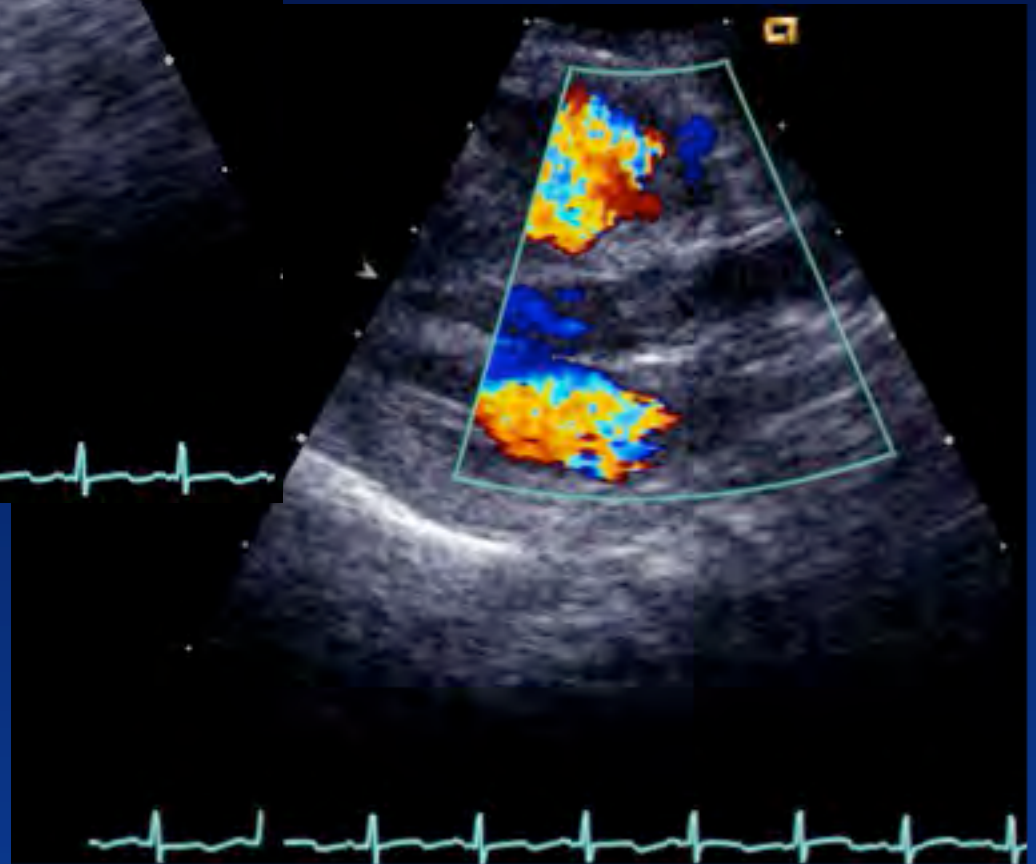
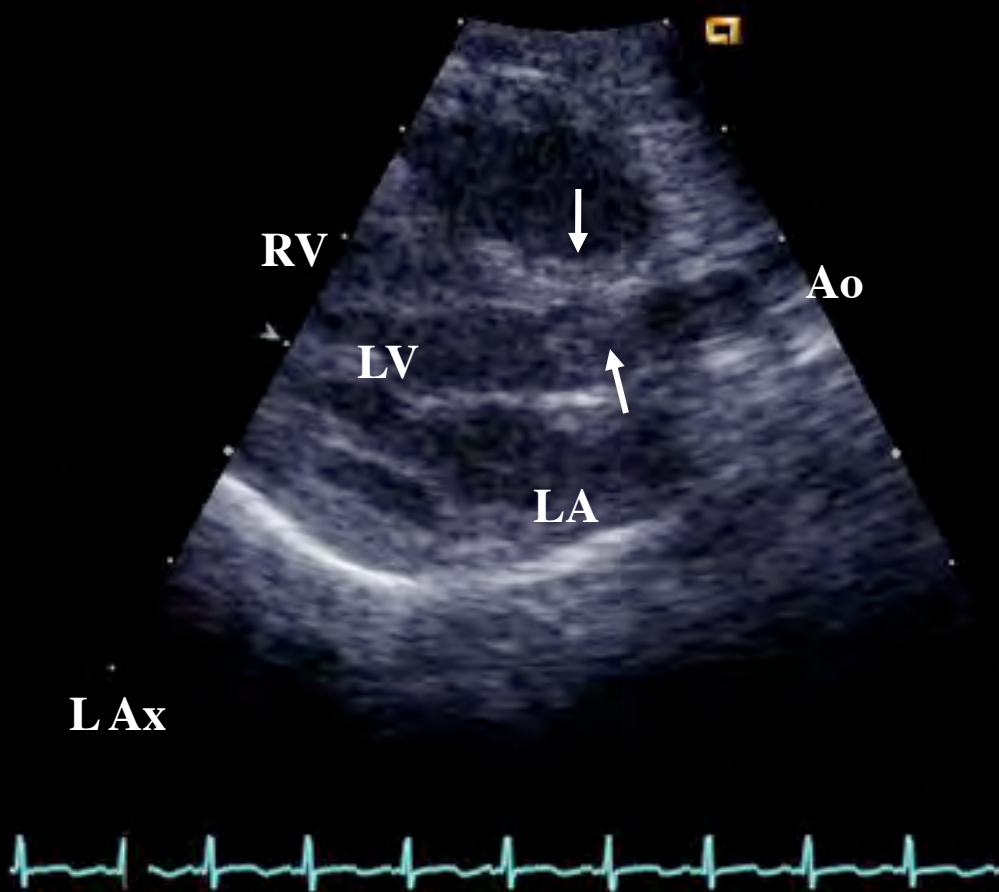
William's Syndrome



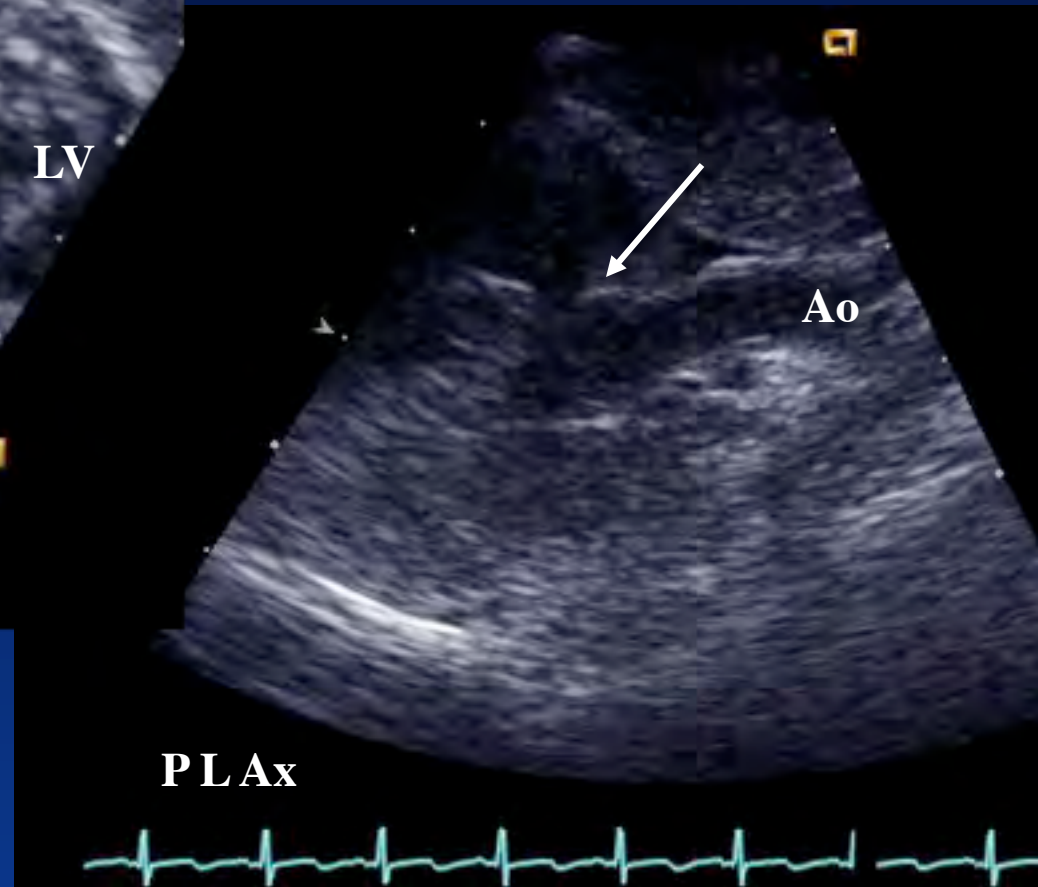
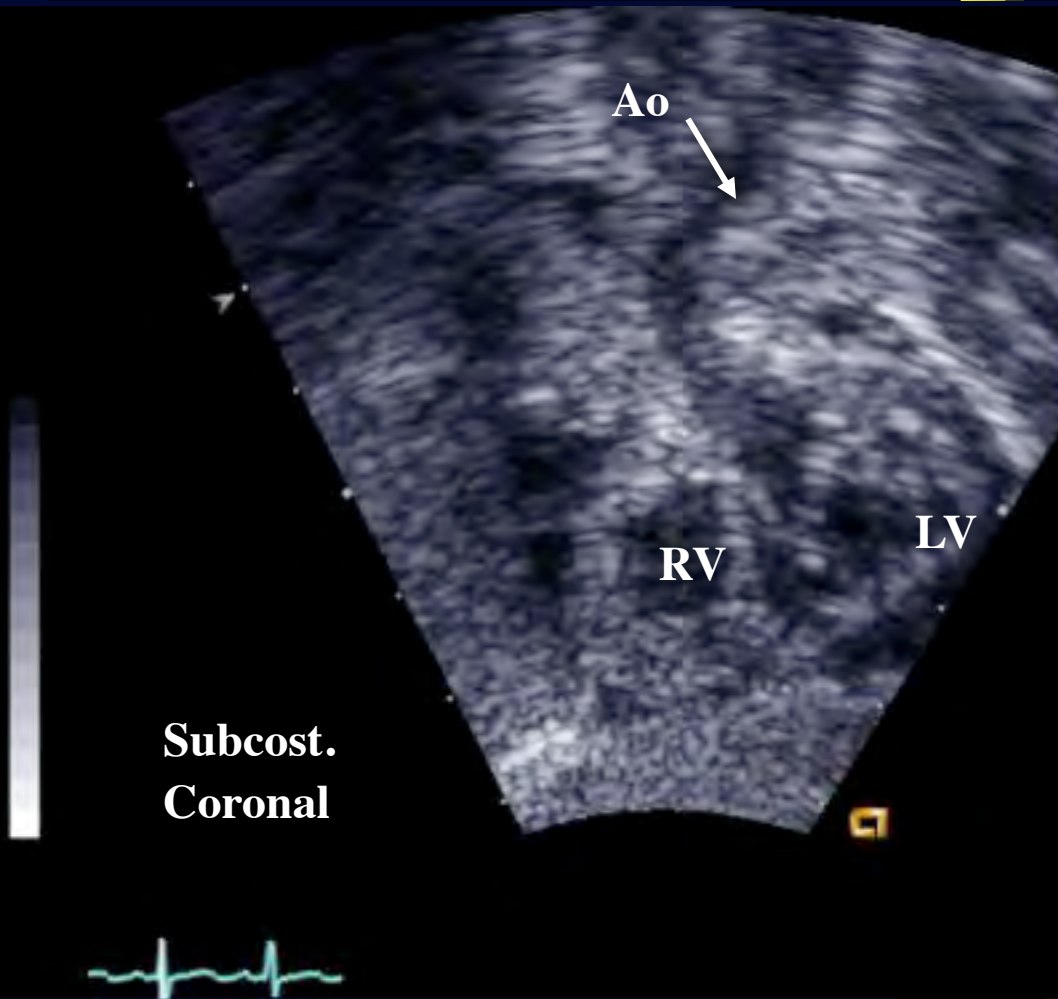
William's Syndrome



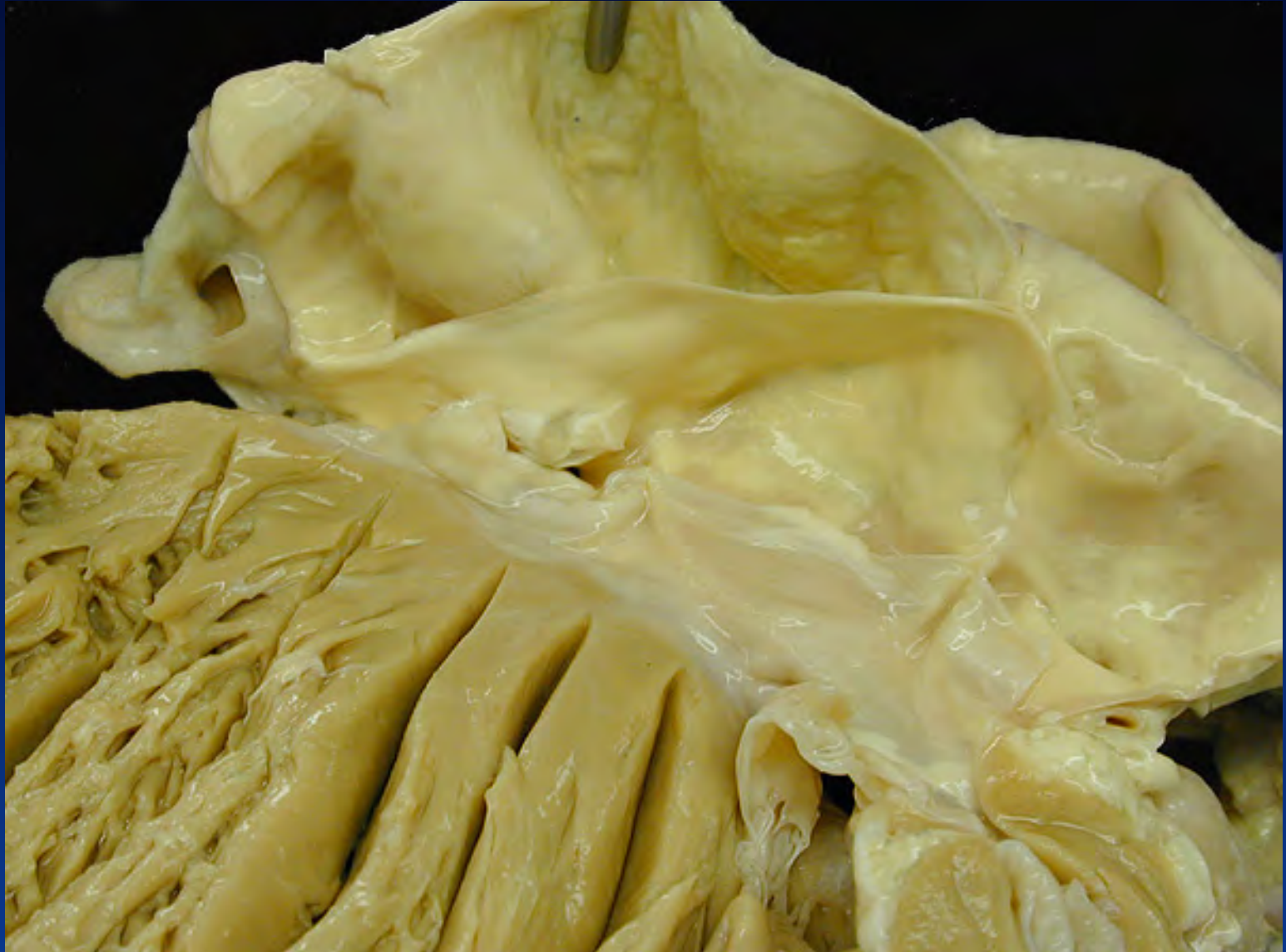Supravalvular Aortic Stenosis



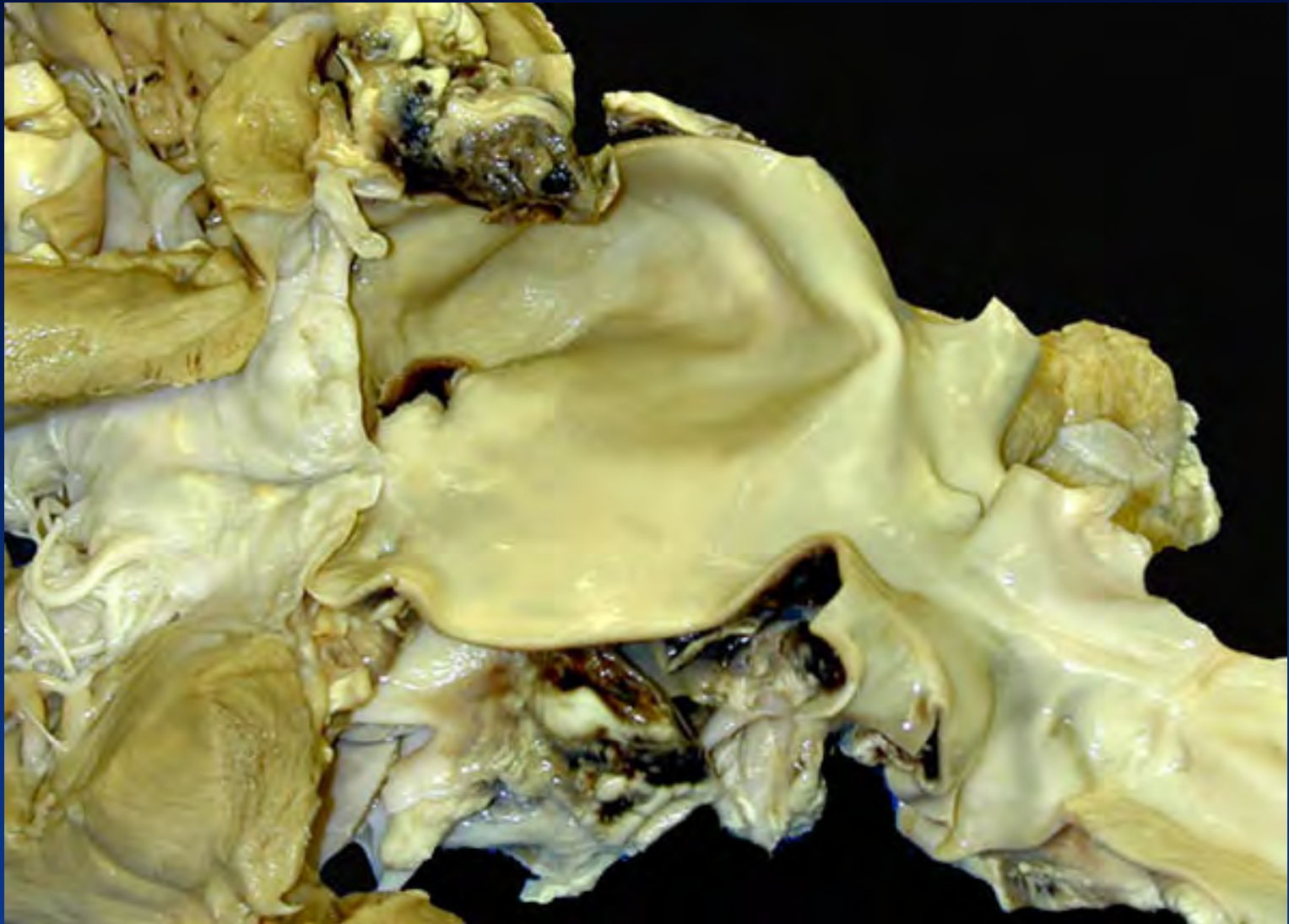
Supravalvular Aortic Stenosis



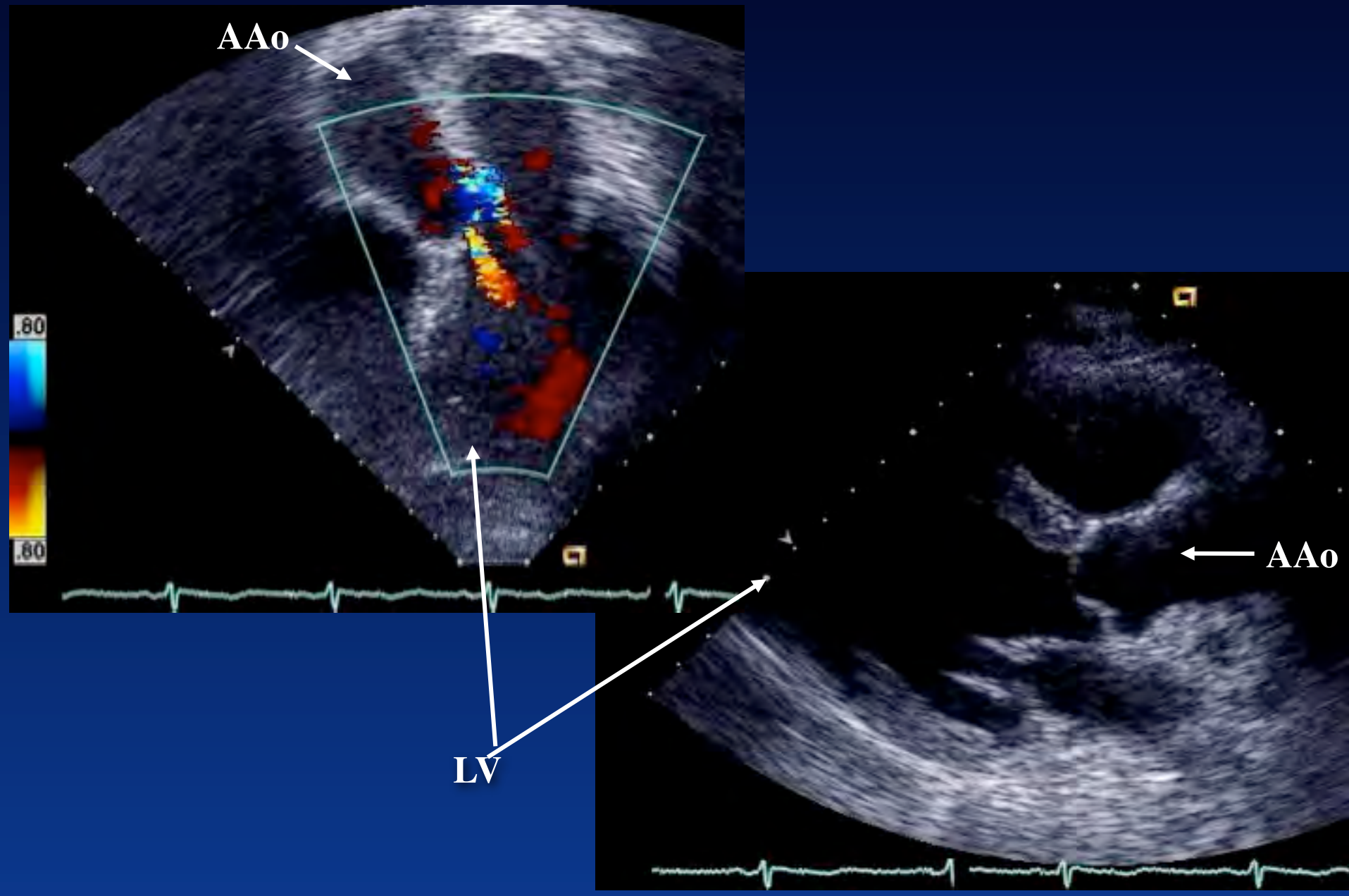
Bicuspid Aortic Valve & Multiple Dissections



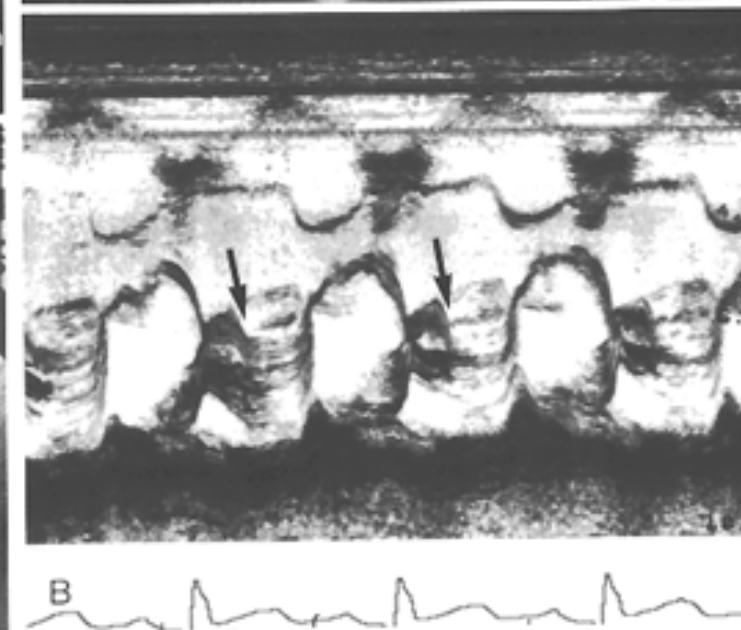
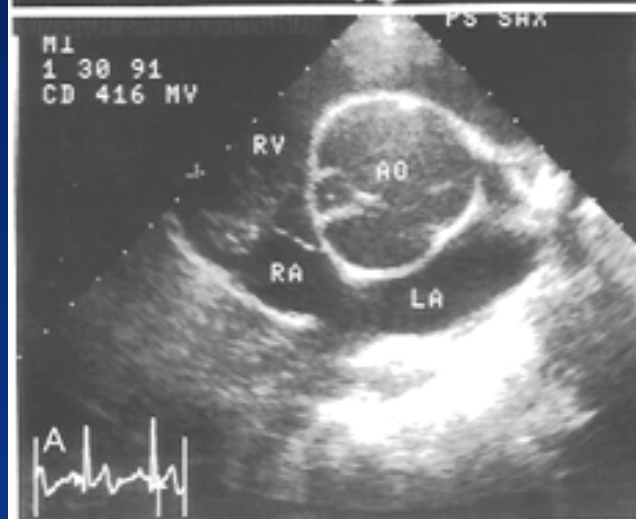
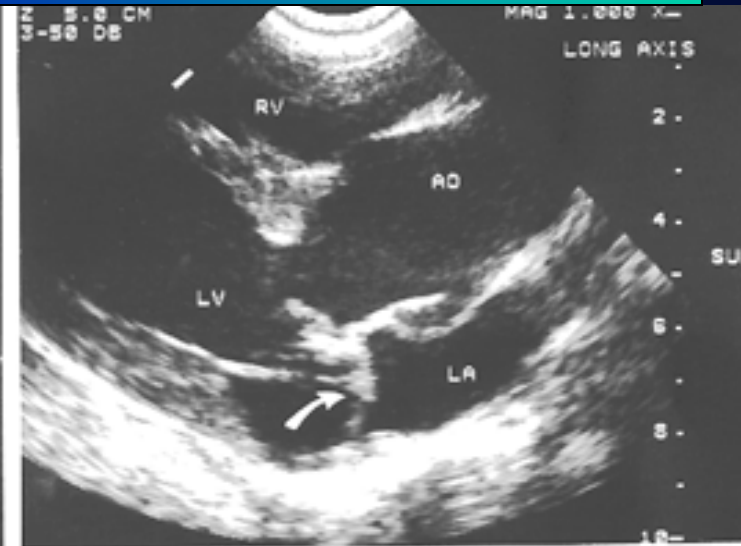
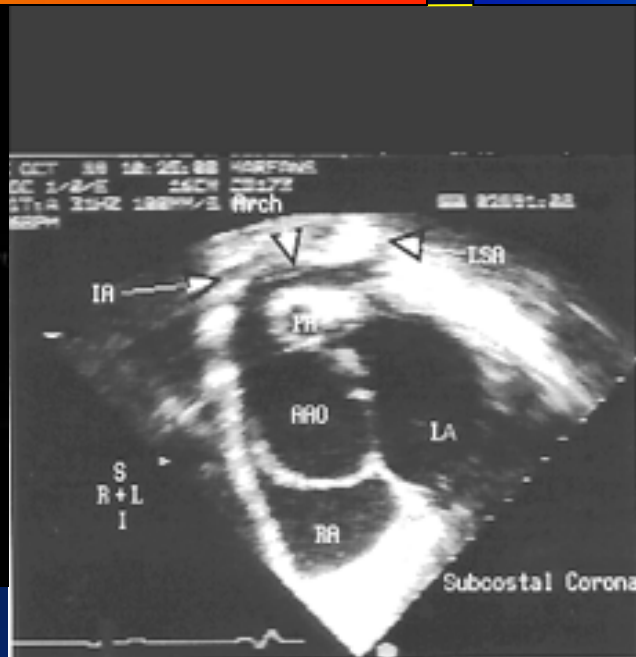
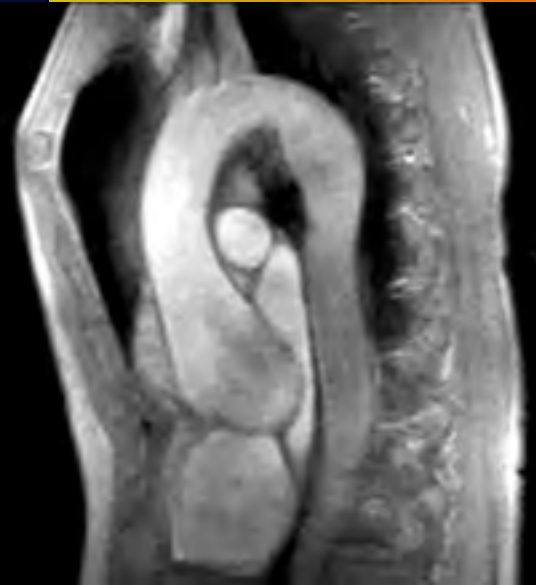Aortic Dissection, Coarctation & Bicuspid Aortic Valve



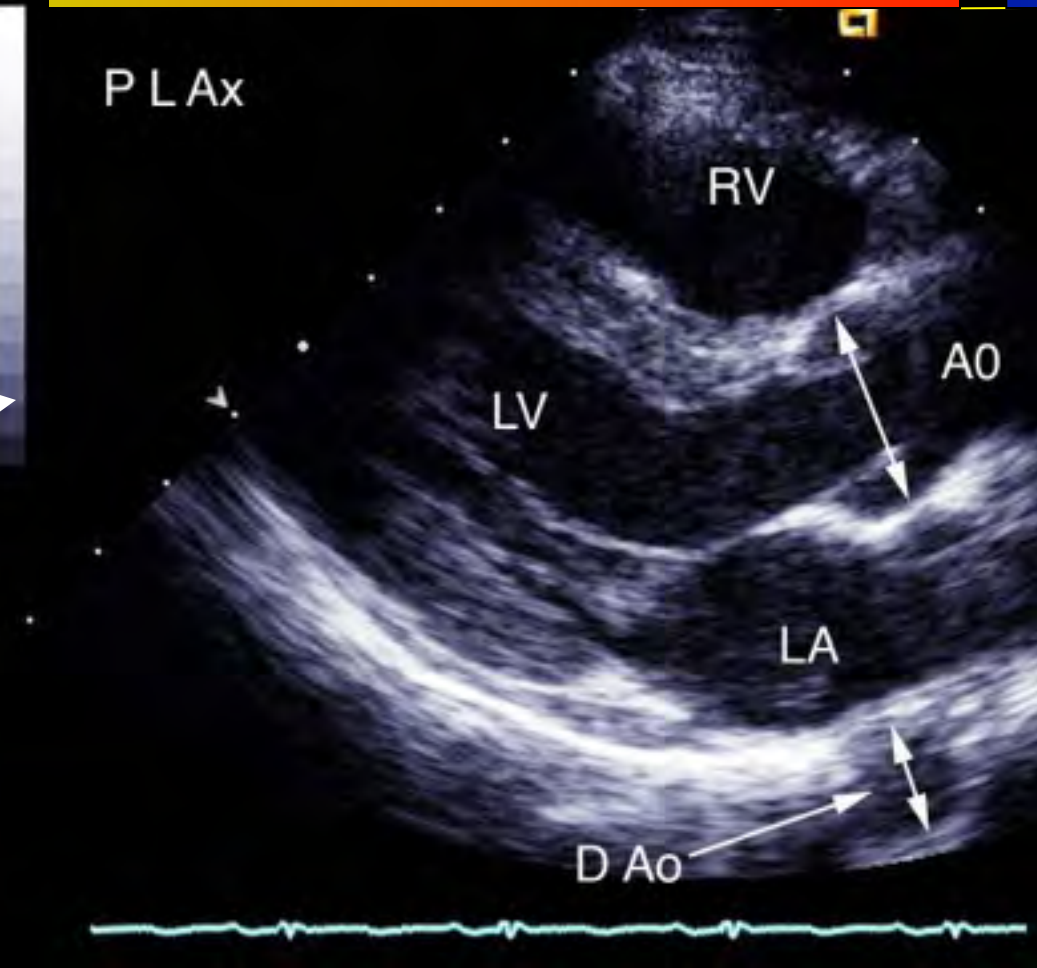
Bicuspid Aortic Valve: Post Stenotic Dilatation



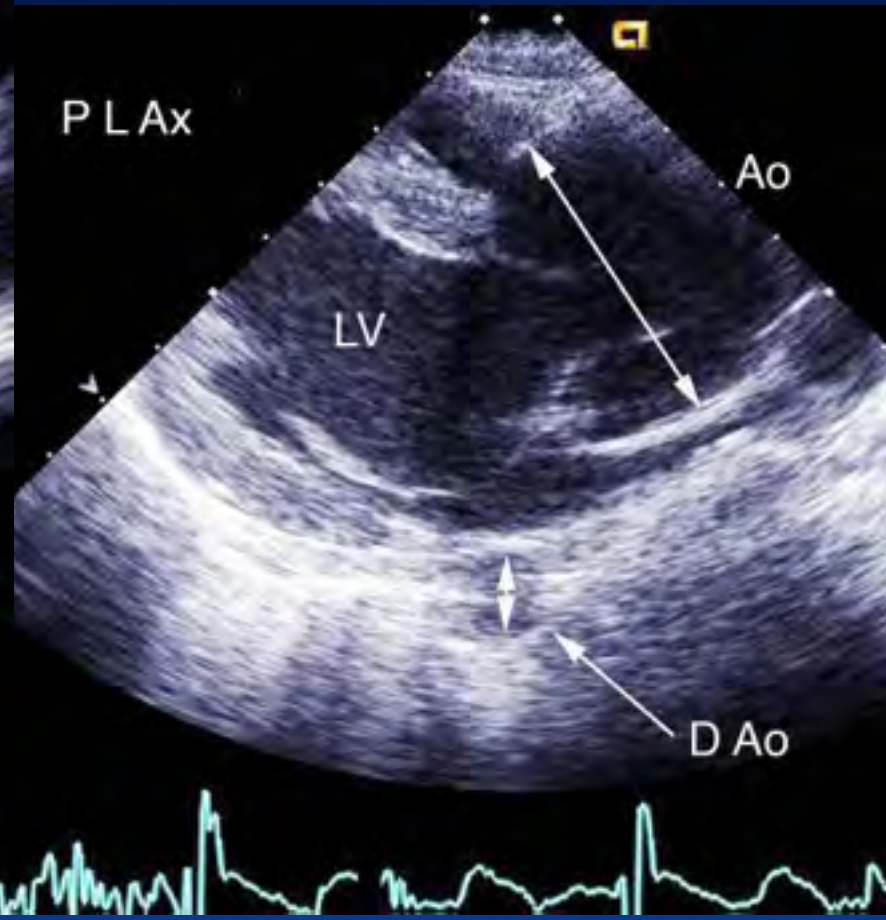Marfan's Syndrome



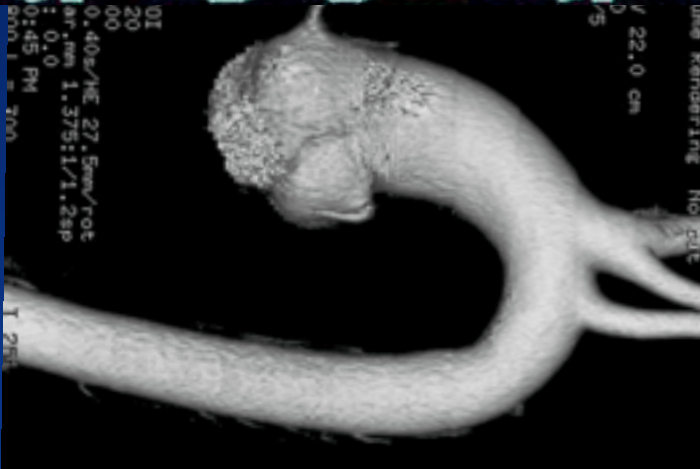
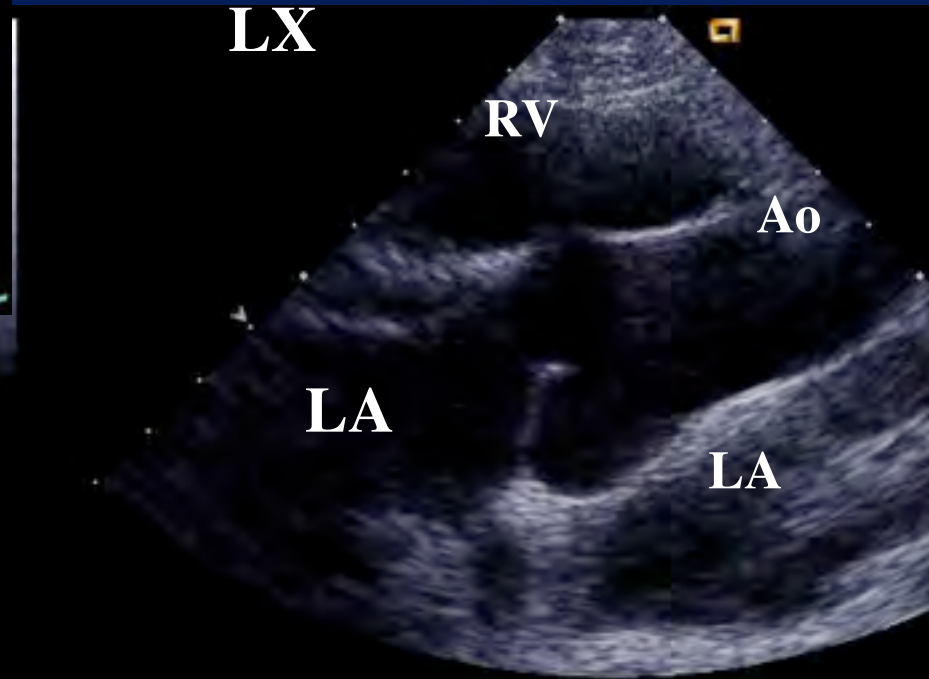
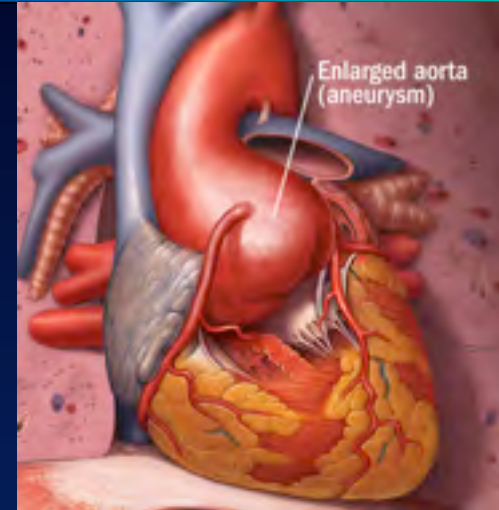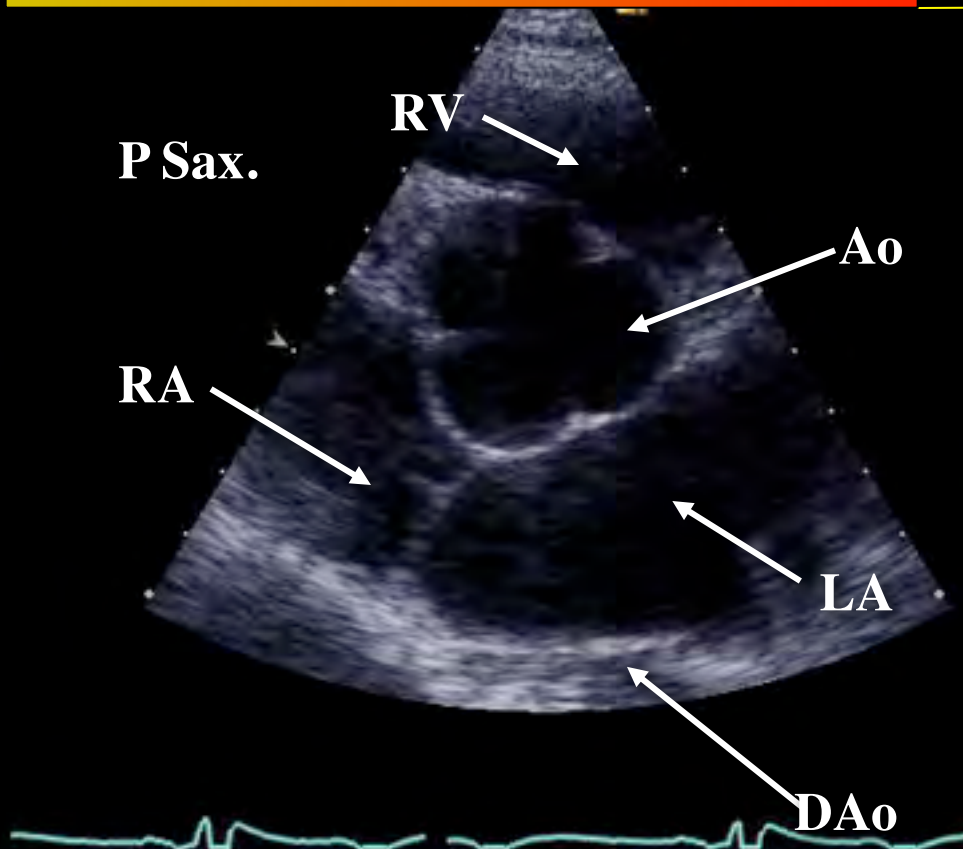
Marfan's Syndrome



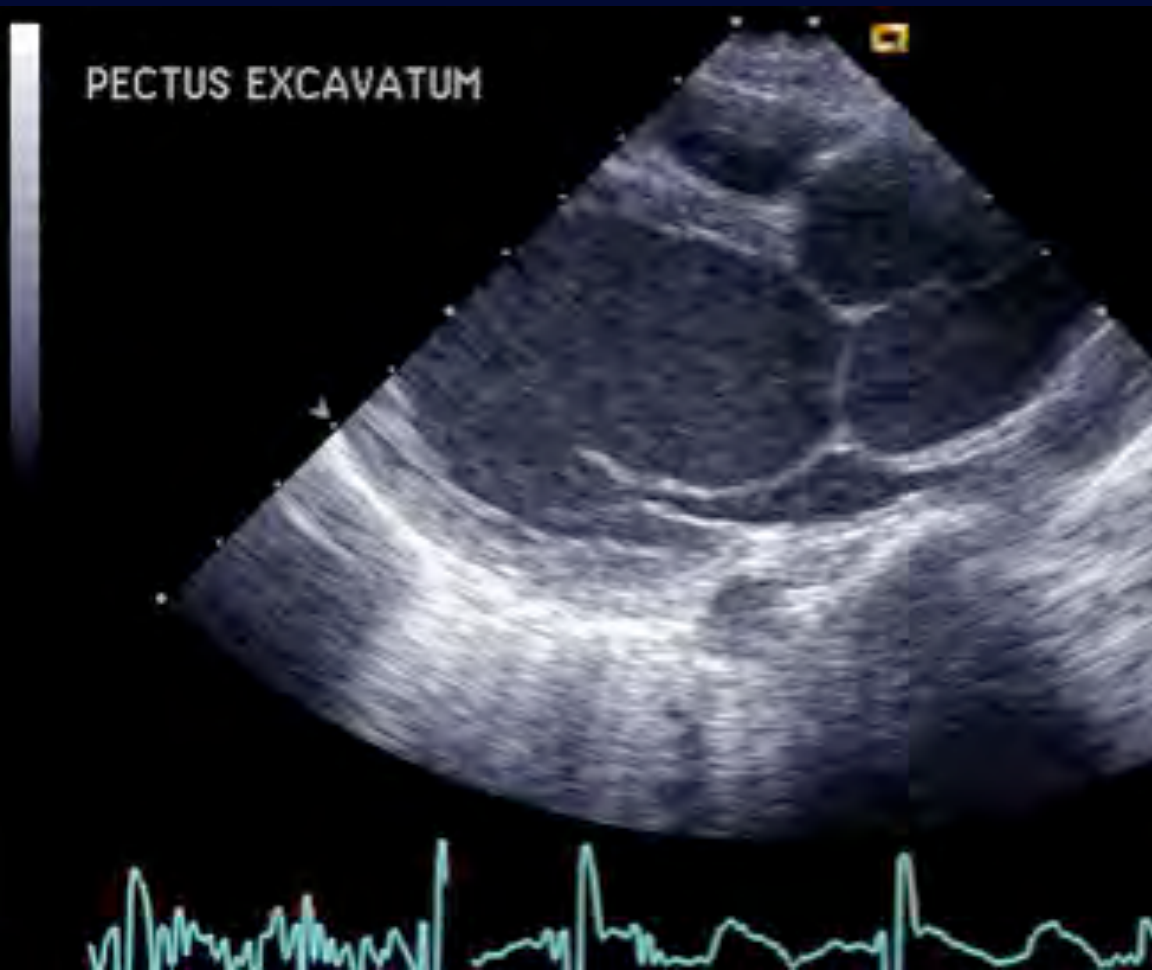
Mariska Kemna



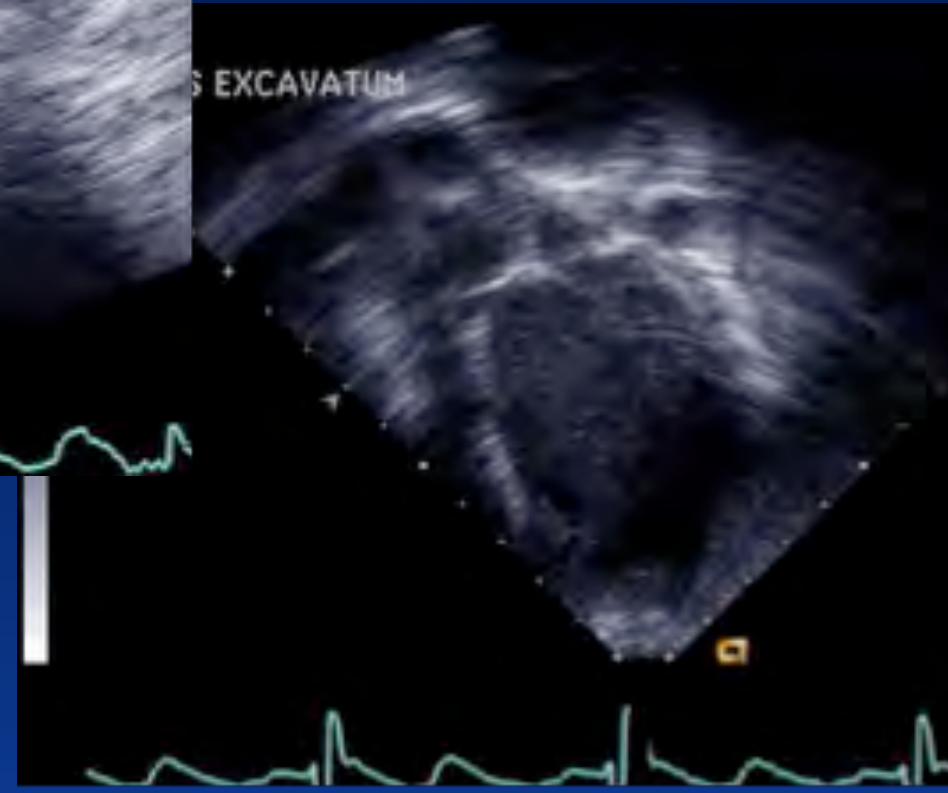
Marfan's Syndrome: Dilated Aortic Root



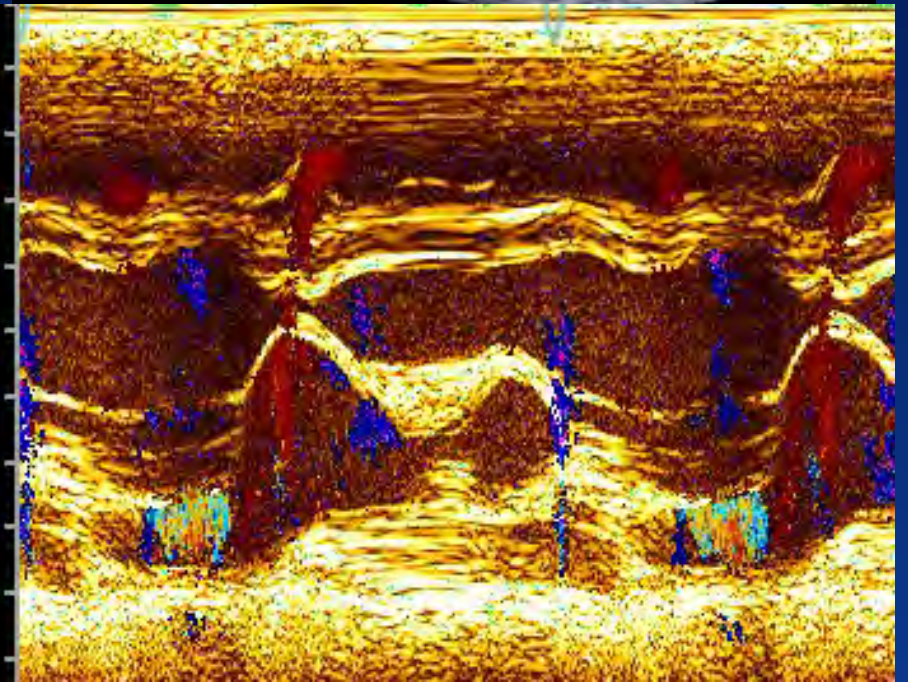
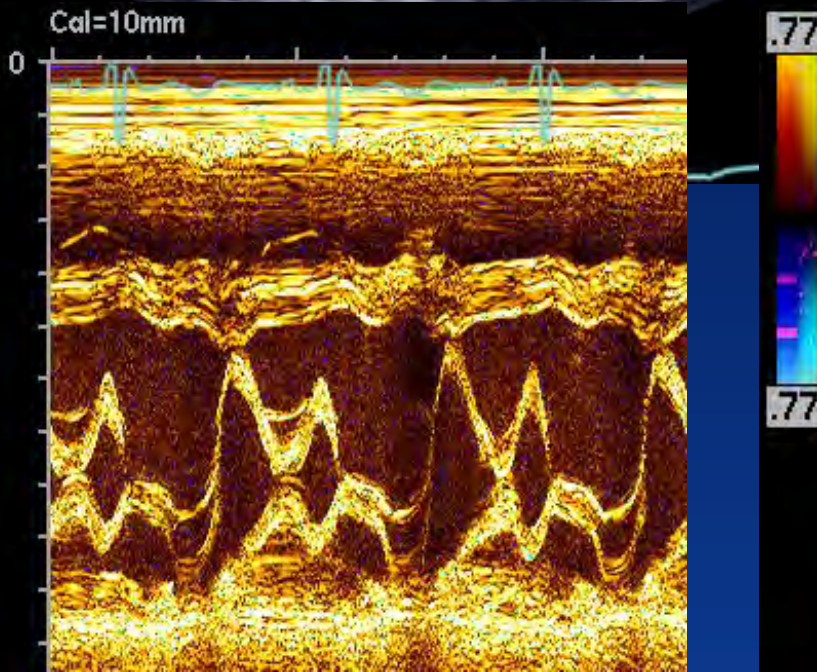
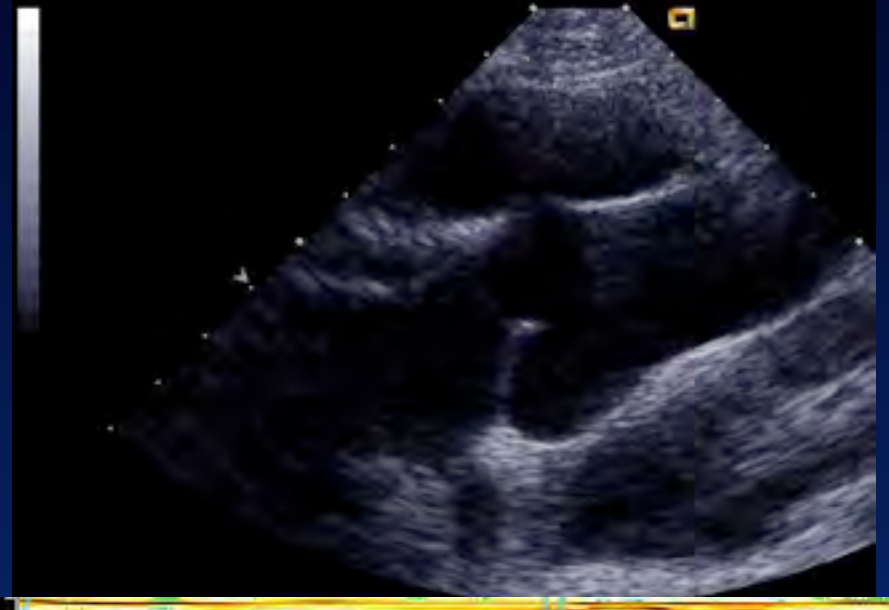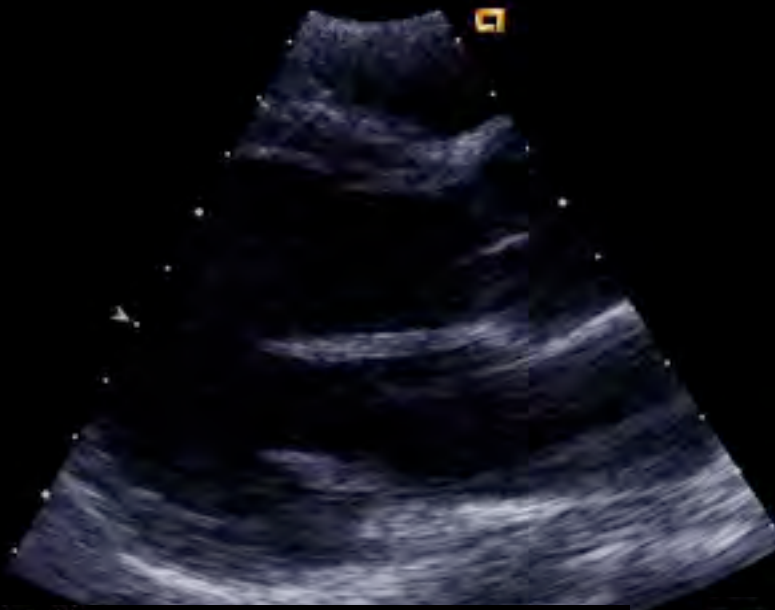Marfan's Syndrome: Dilated Aortic Root



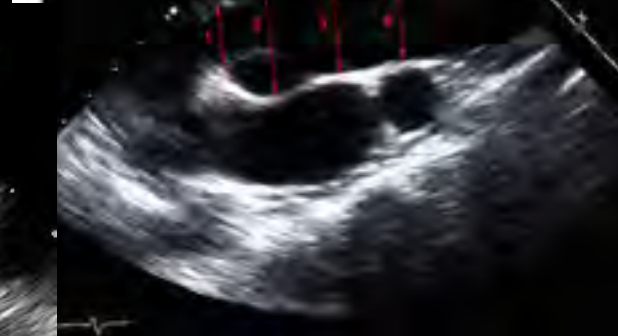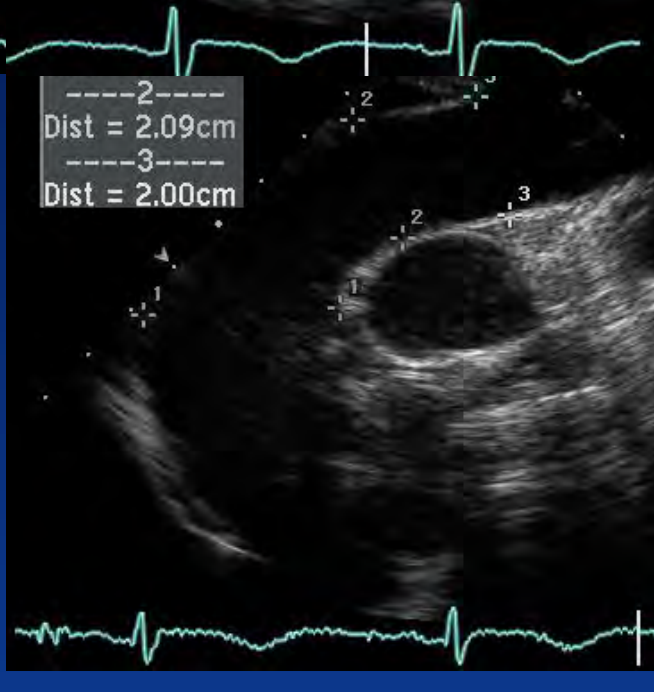
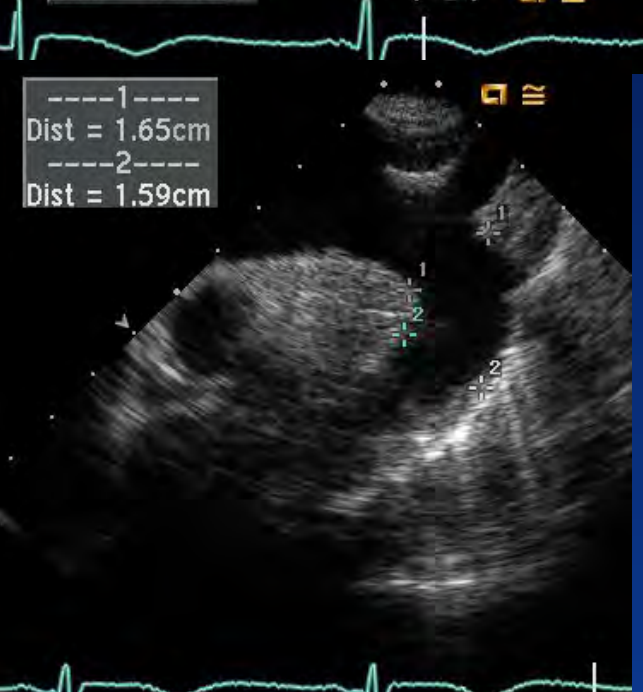
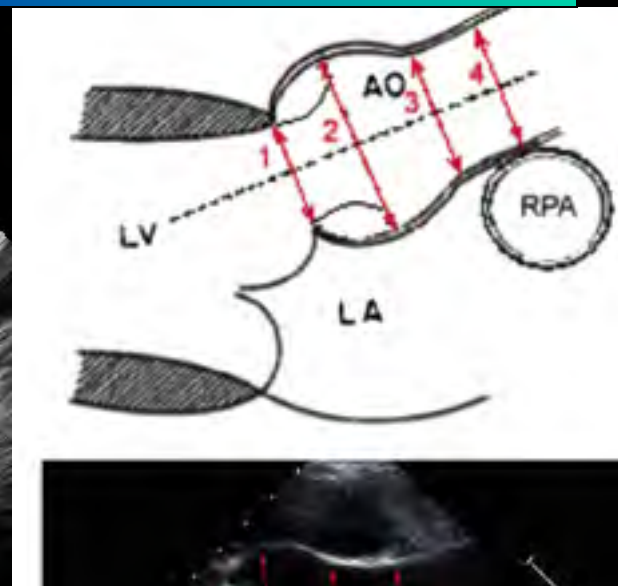
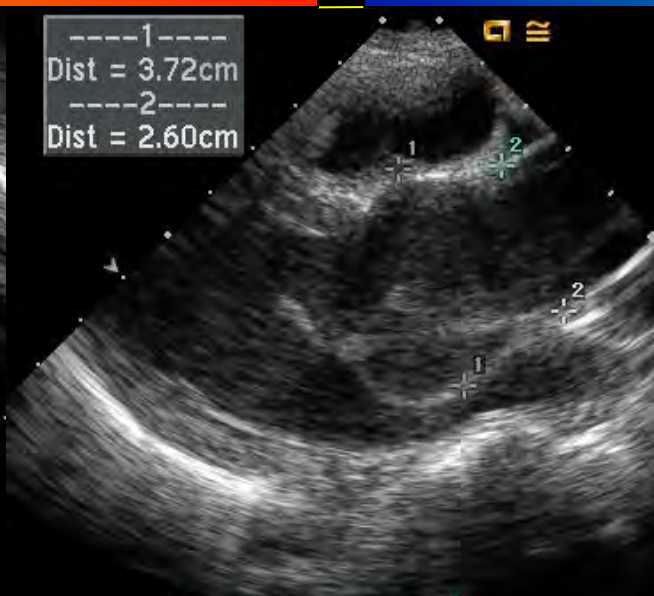
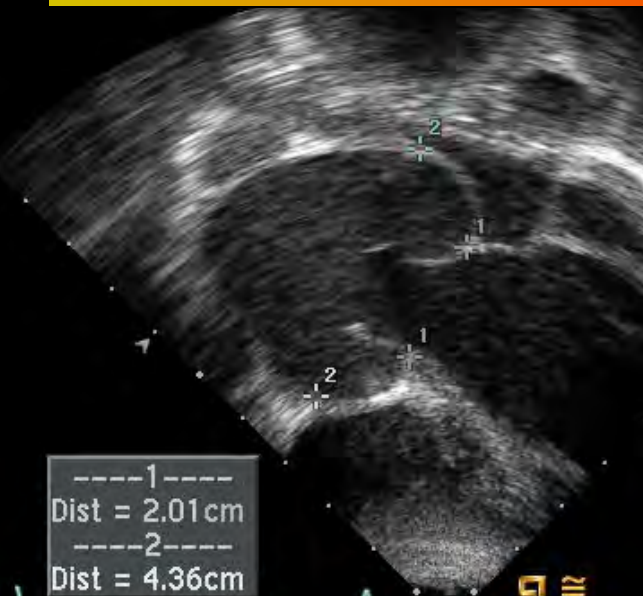Aortic Regurgitation



Marfan's Syndrome: Dilated Aortic Root



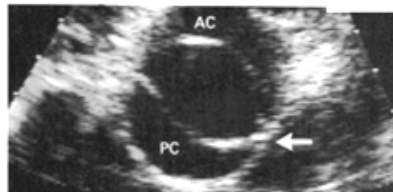
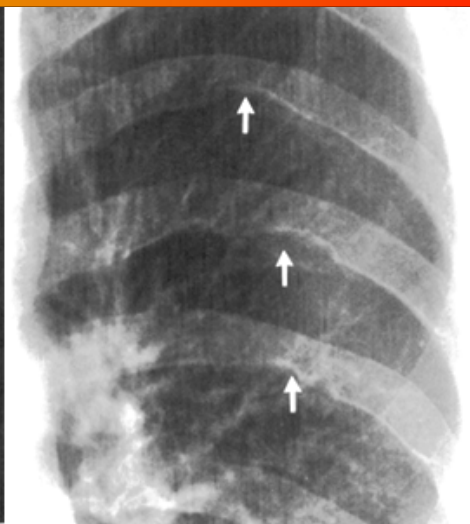
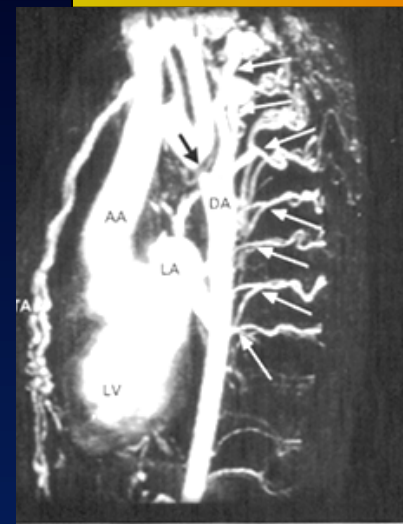
Marfan's Syndrome: Dilated Aortic Root



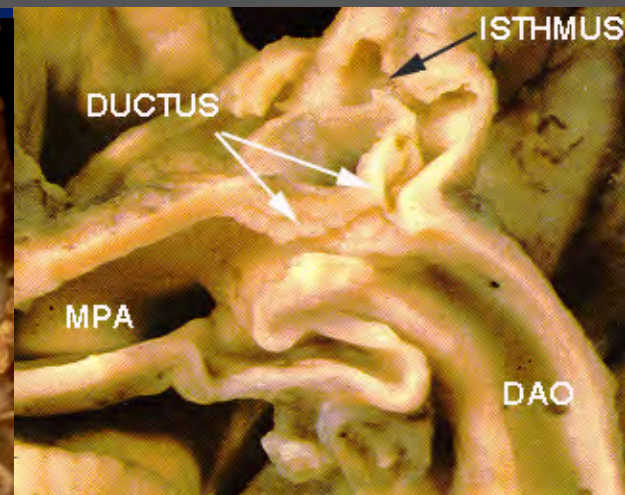
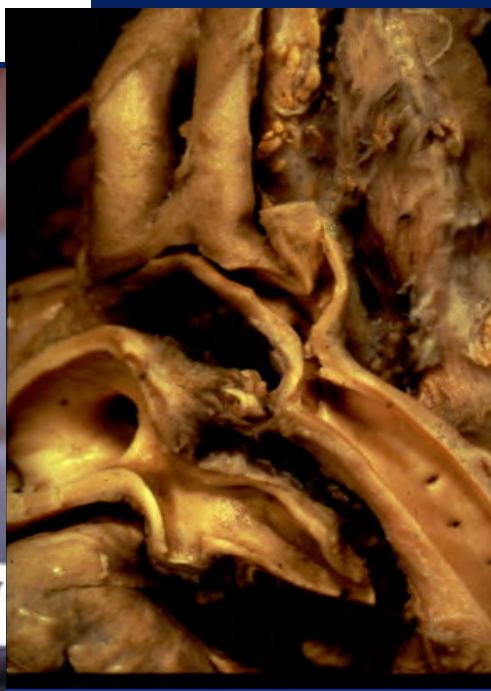
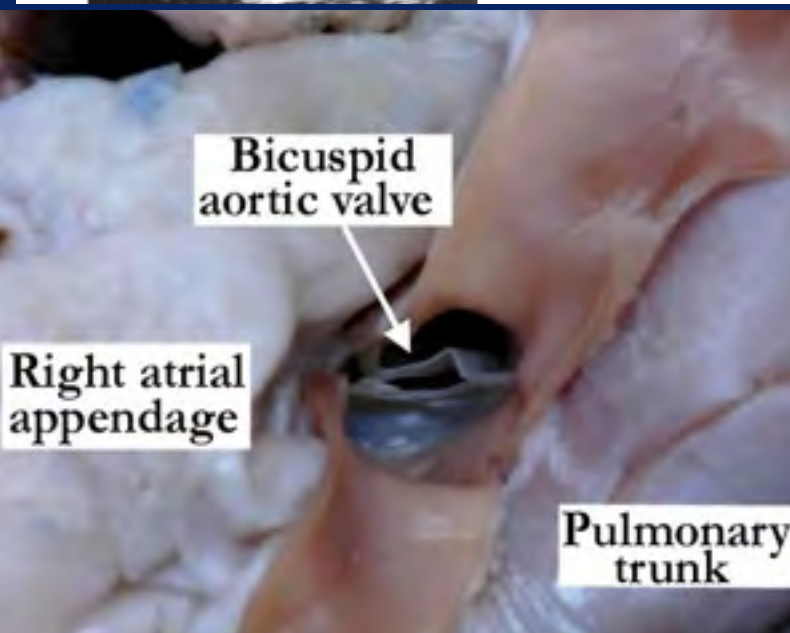
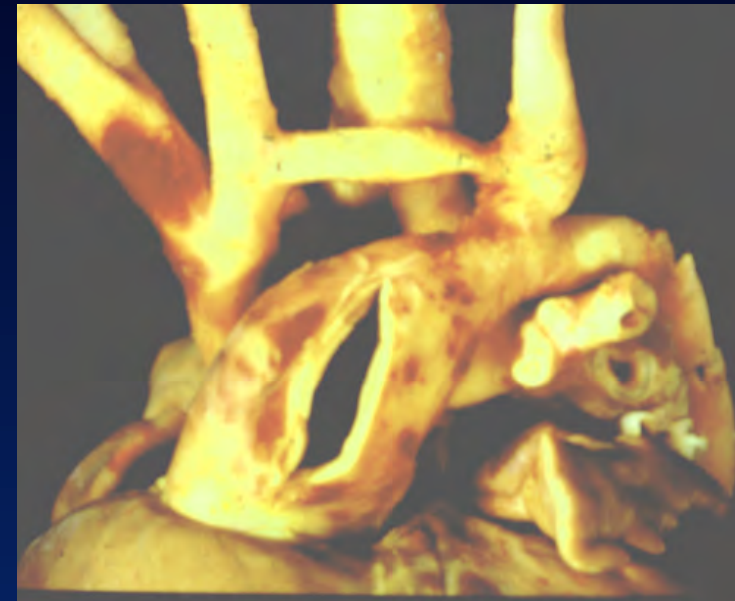
Elif Seda Selamet Tierney,

J Am Soc Echocardiogr 2013;

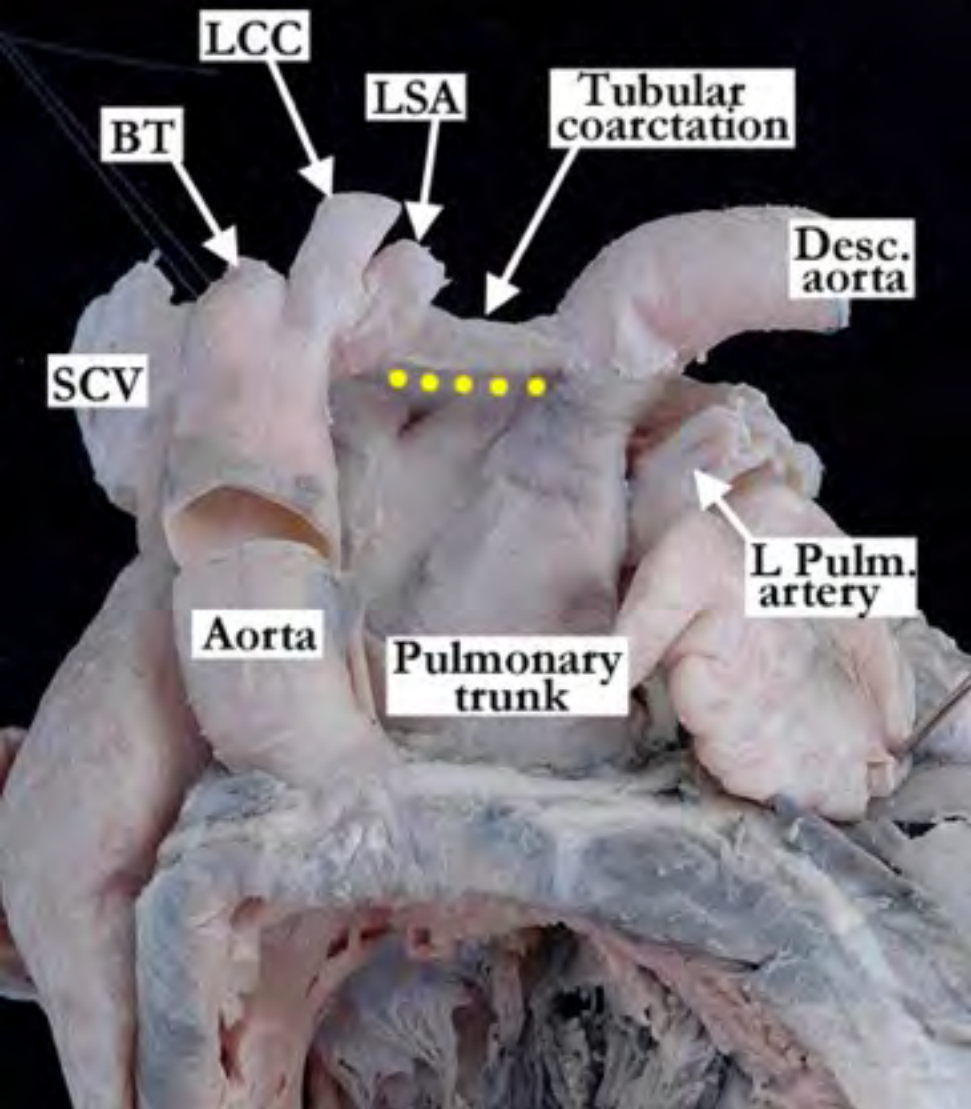
Coarctation



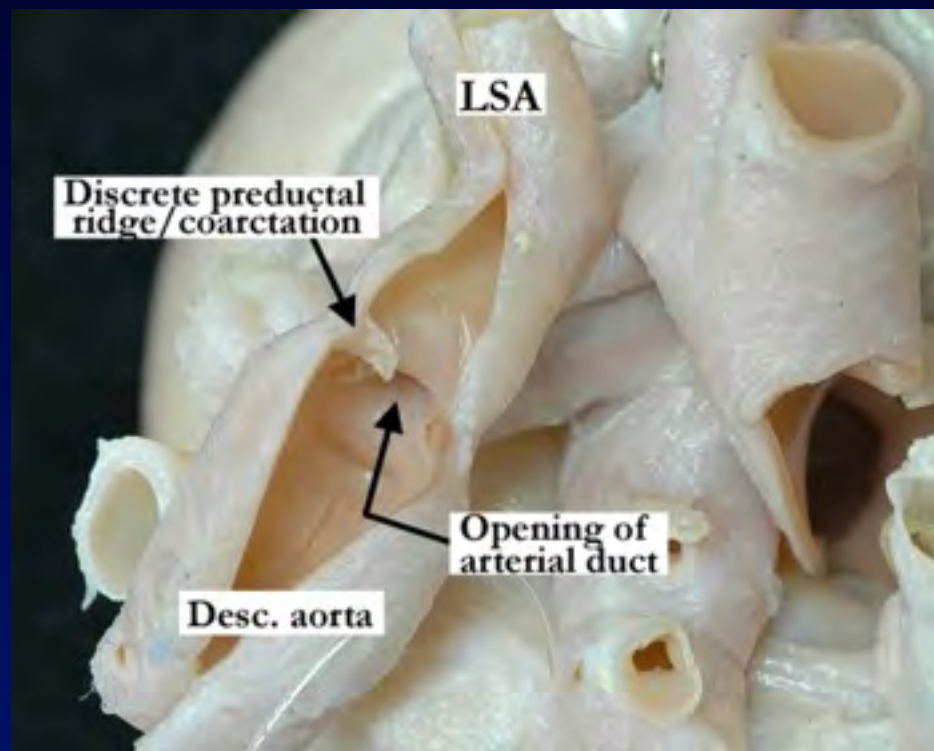
Bruce CJ, Breen JF
NEJM
342, 249, 2000



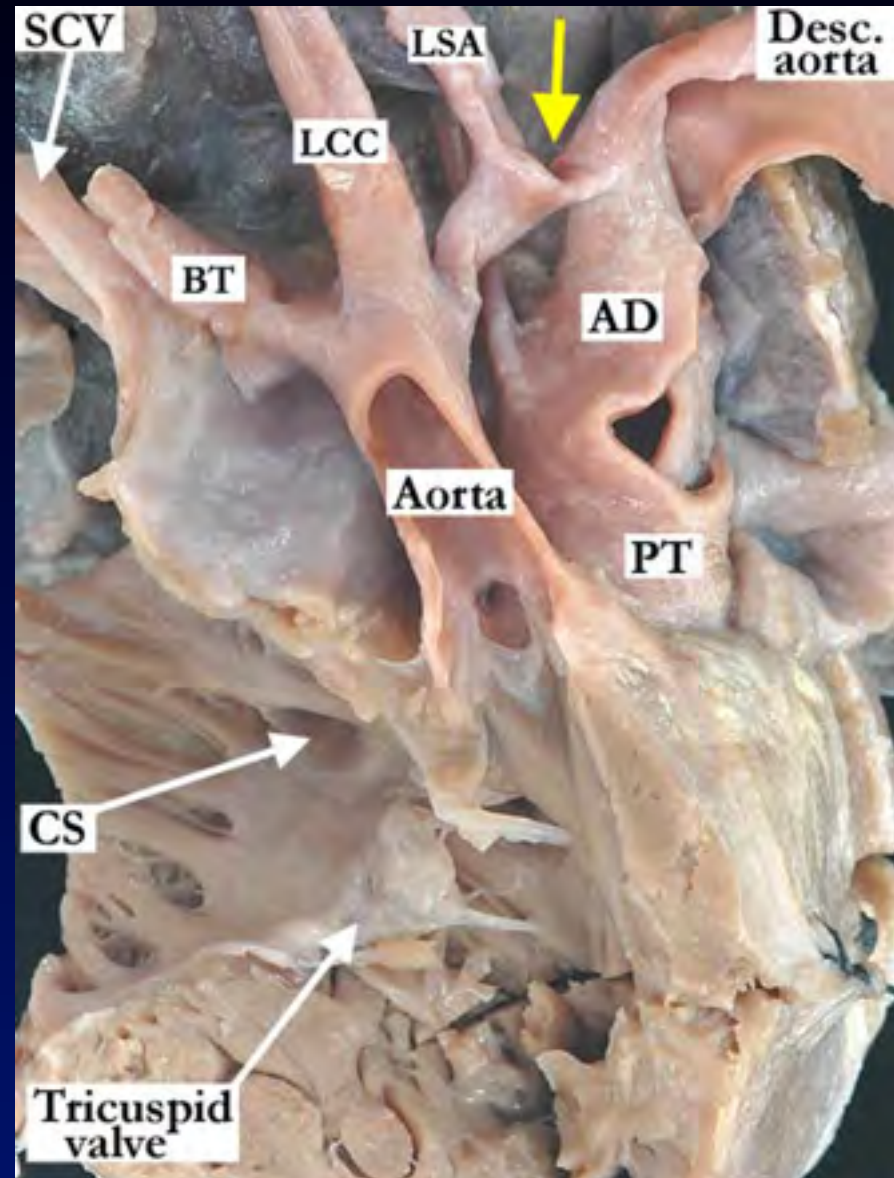
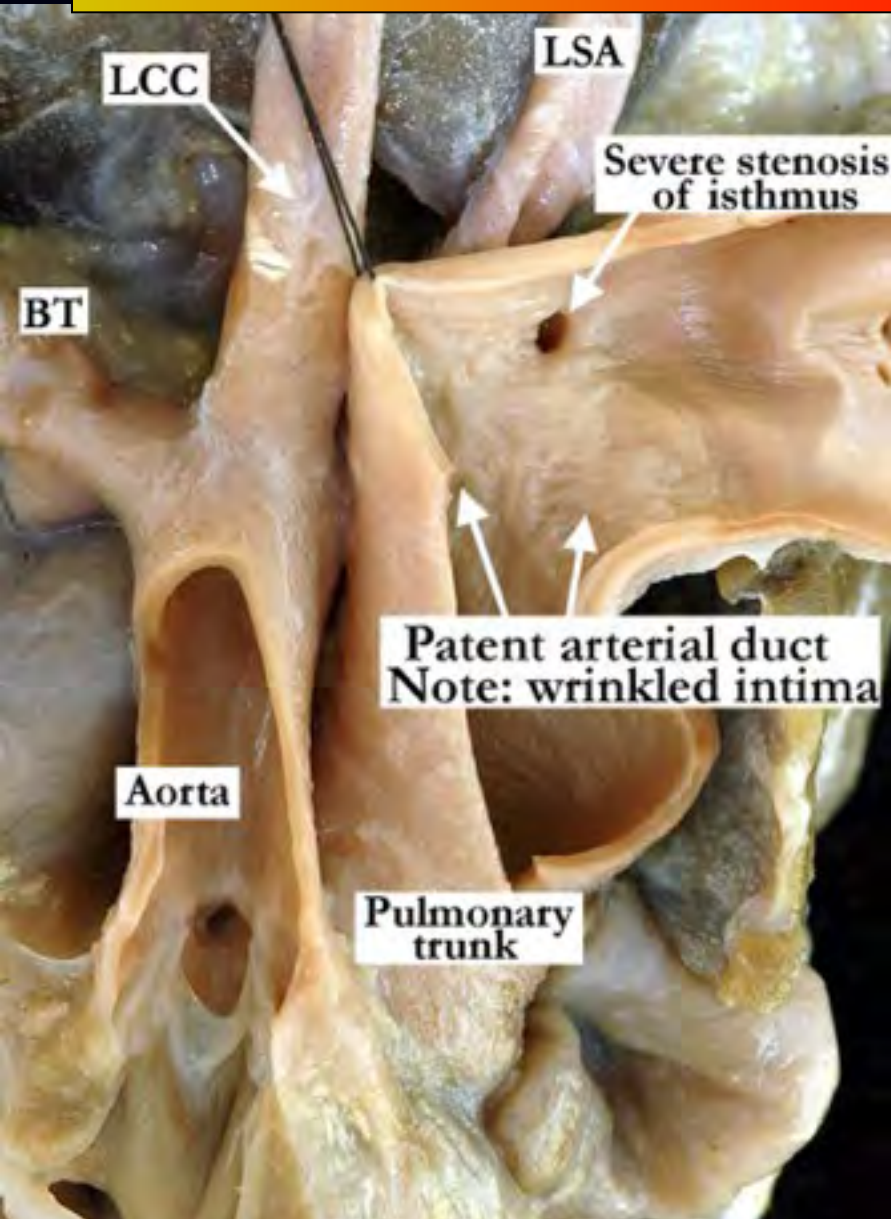
Coarctation



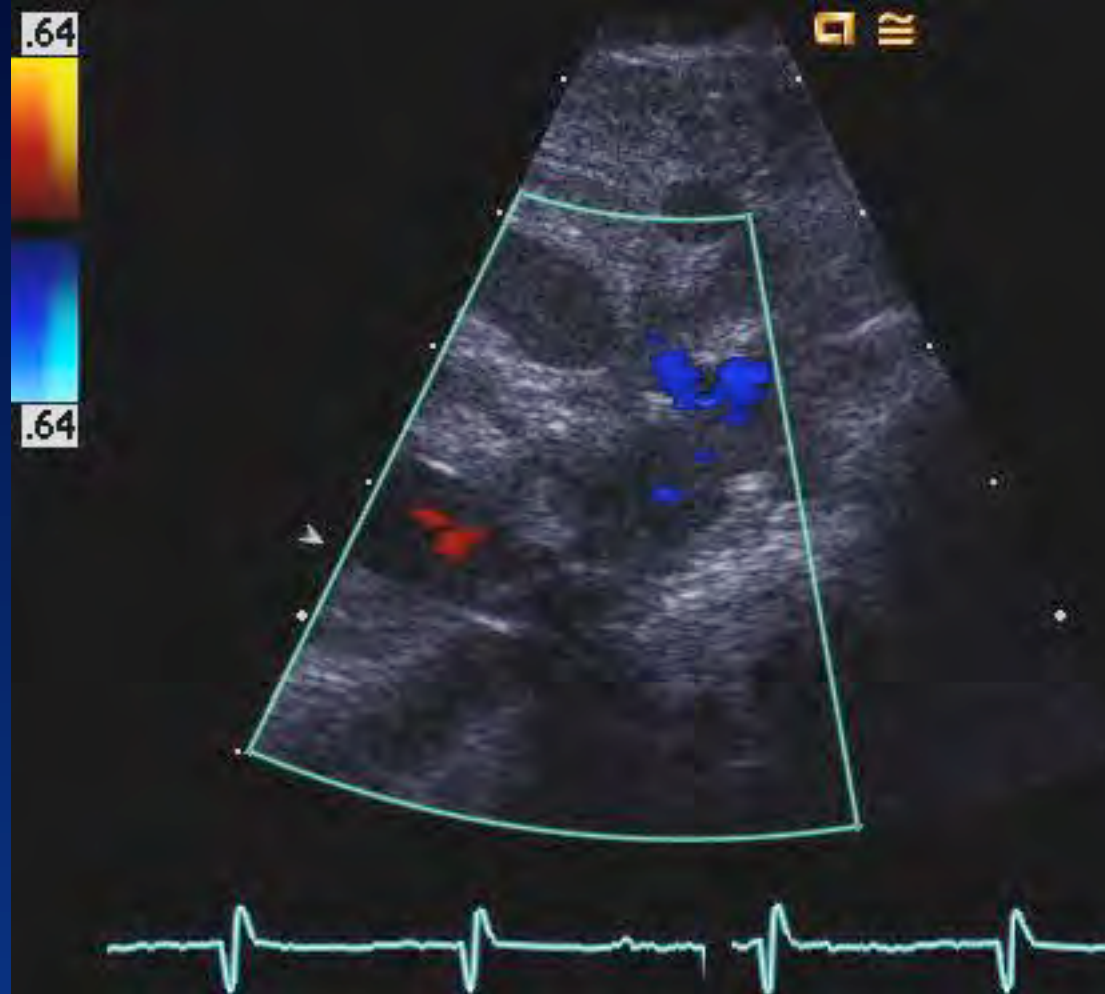

Courtesy Diane Spicer



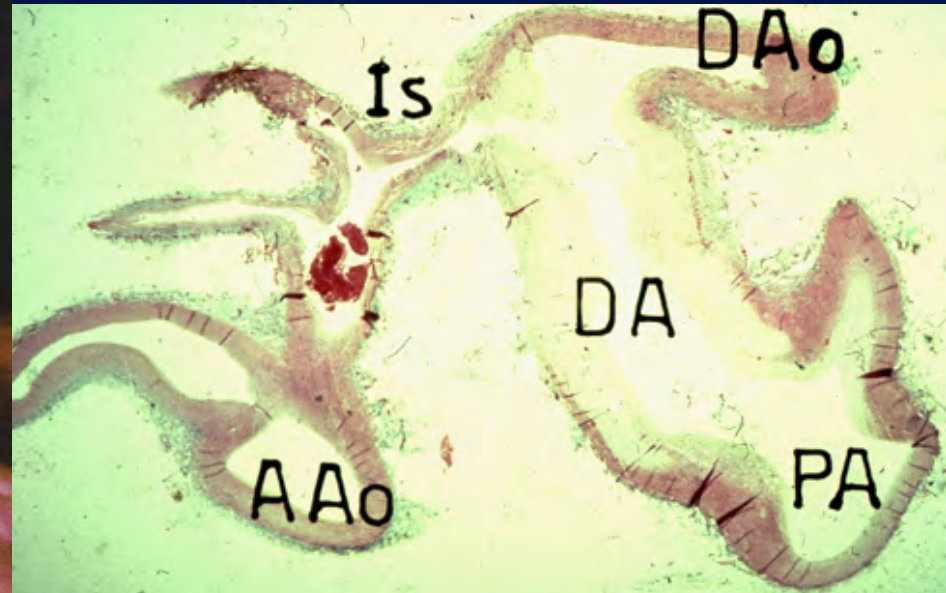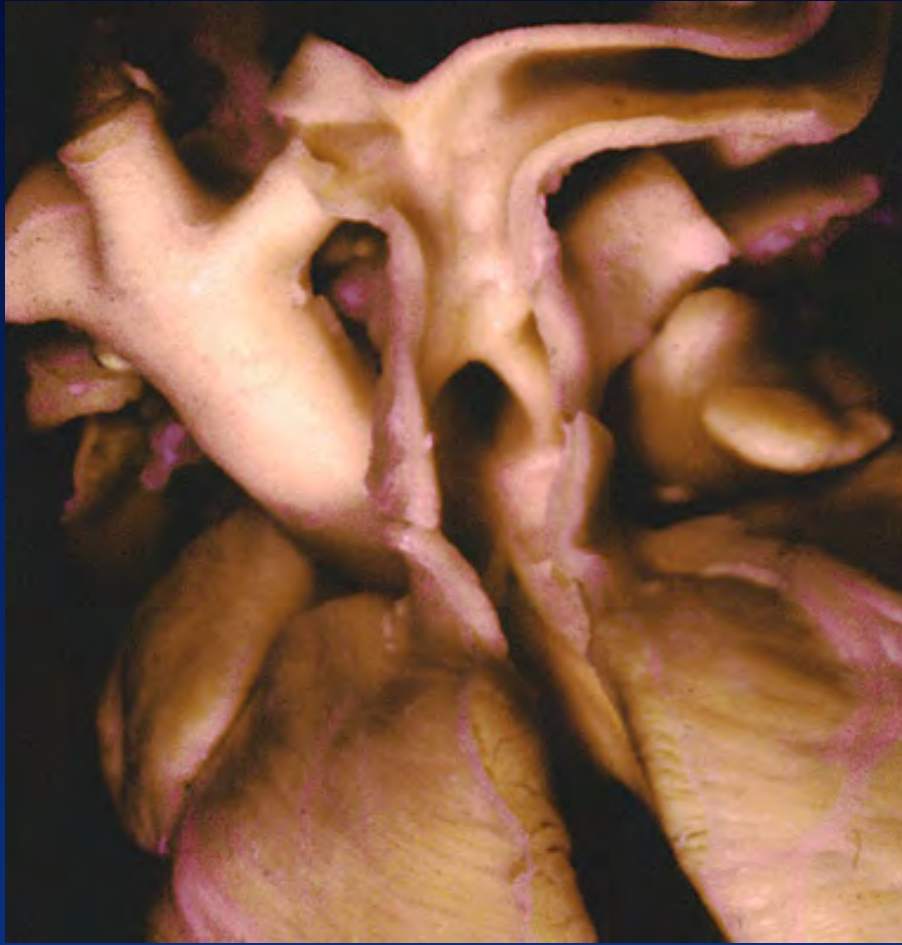Coarctation



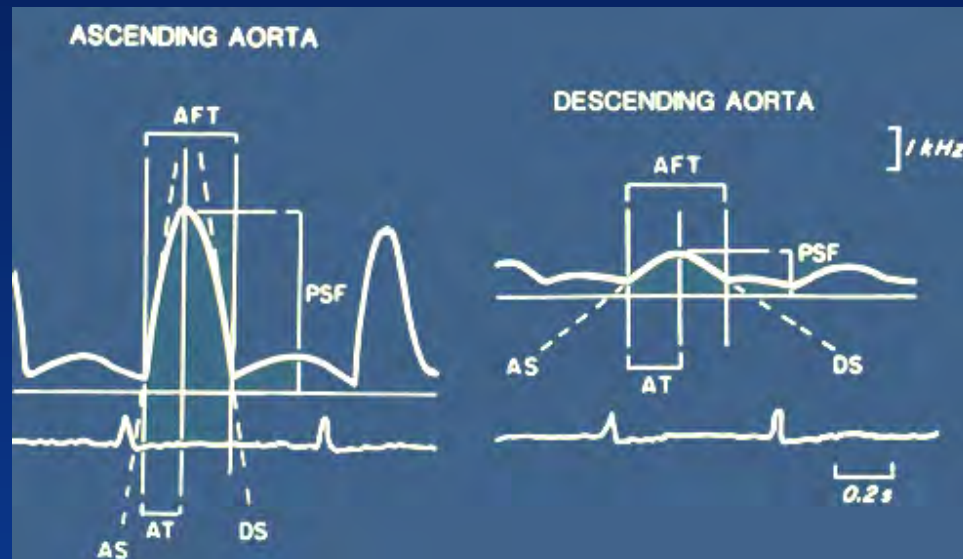
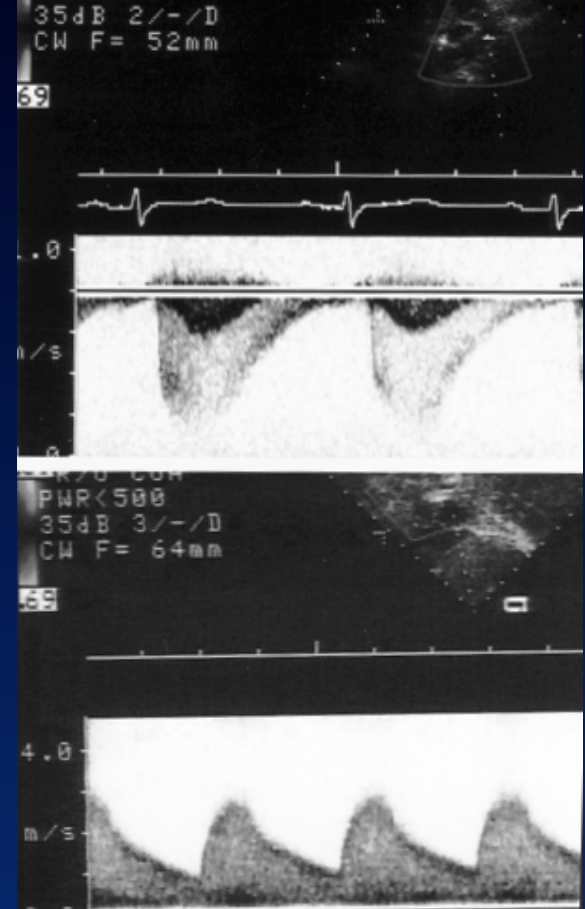
Pathological Varieties of Coarctation & Techniques of Display



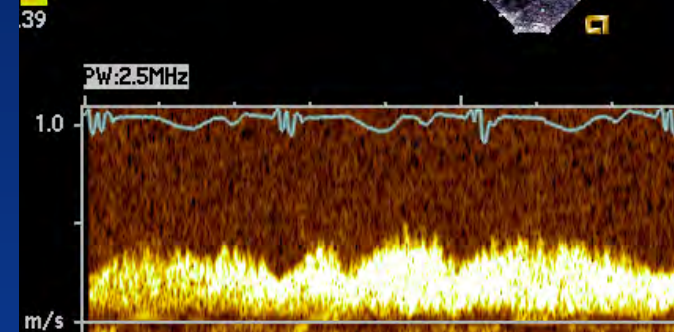
DUCTUS SLING IN COARCTATION



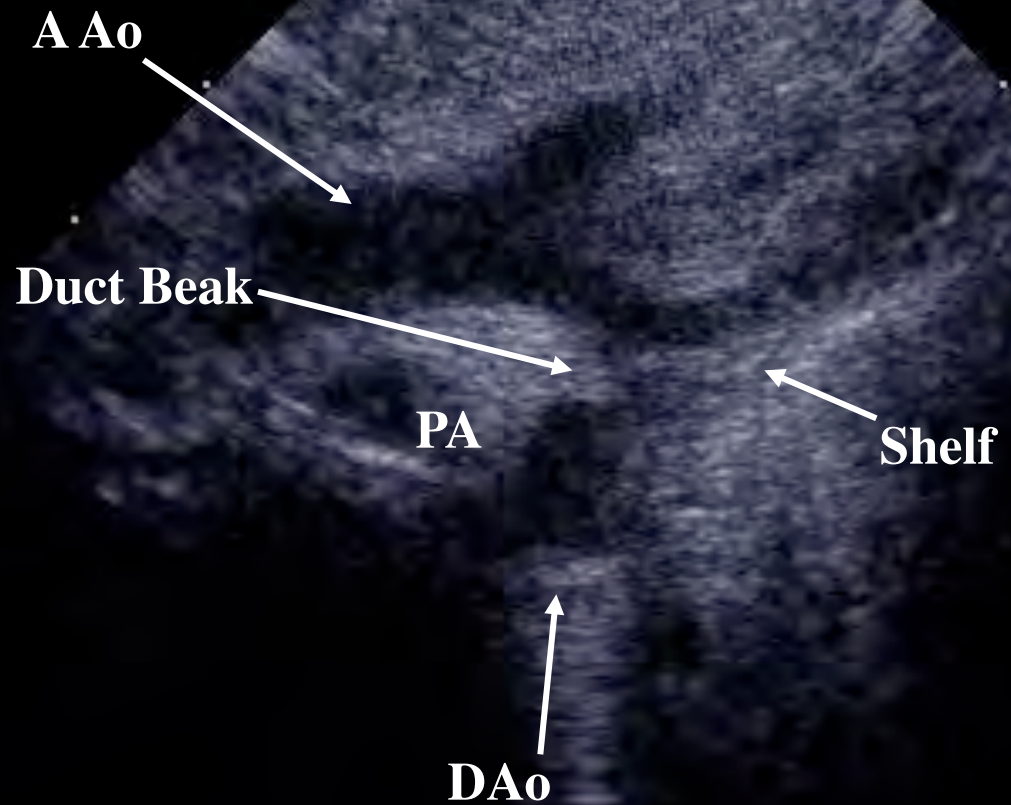
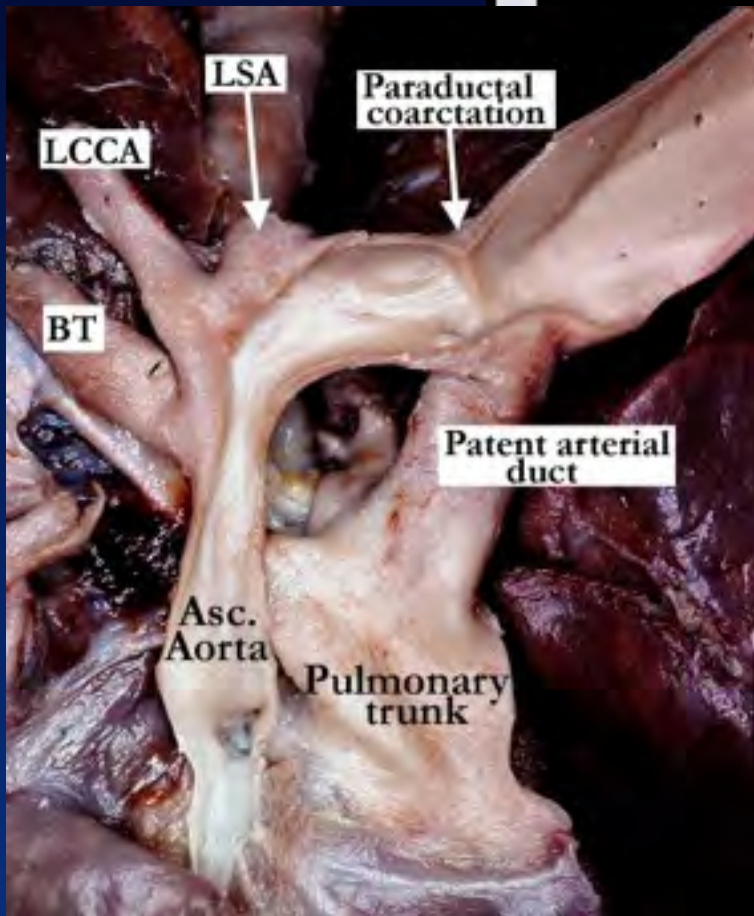
Doppler Δ of Coarctation



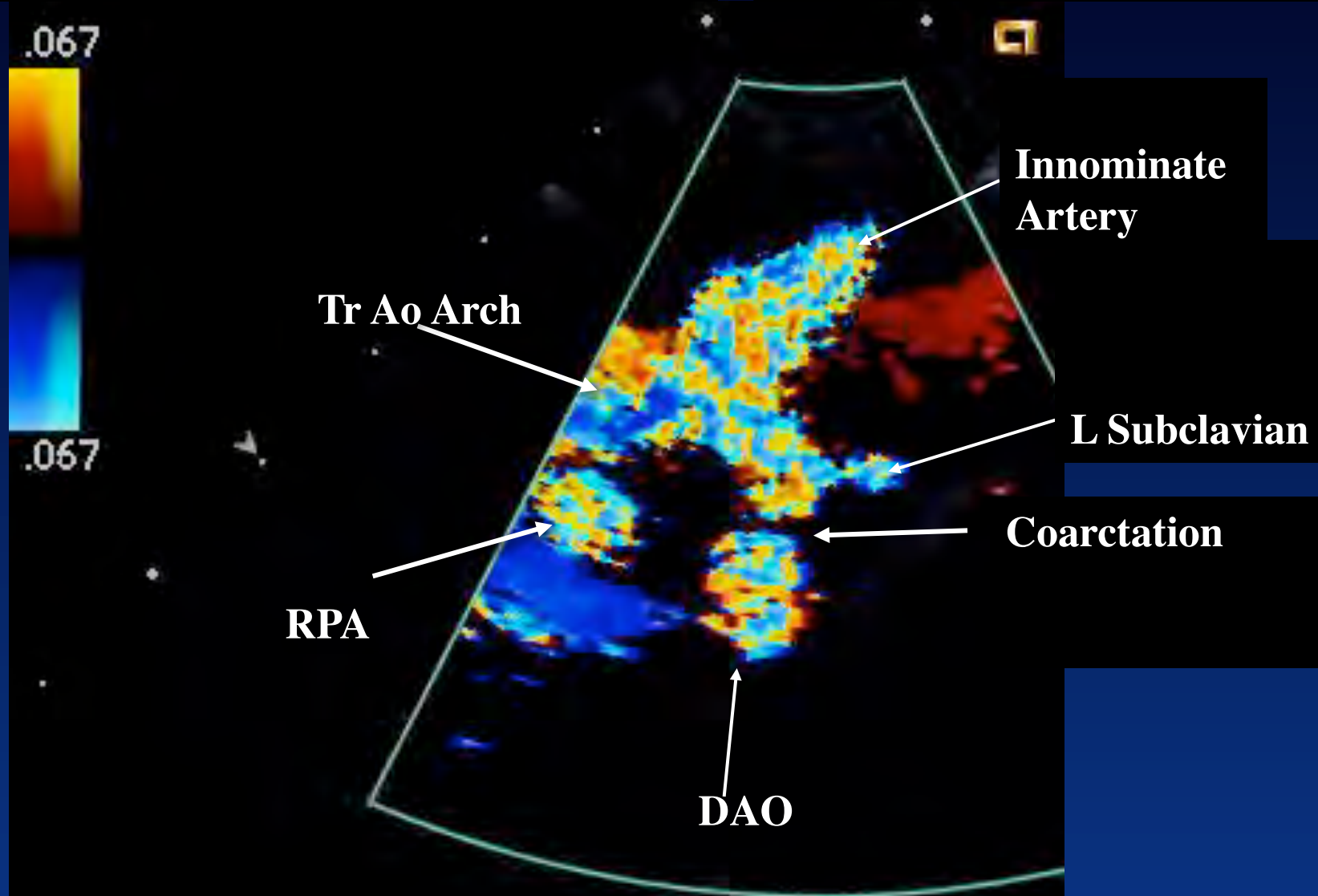
39 50dB 3 +/-1/0/2
PW Depth= 51mm
PW Gate= 1.0mm
PW Gain= 6dB



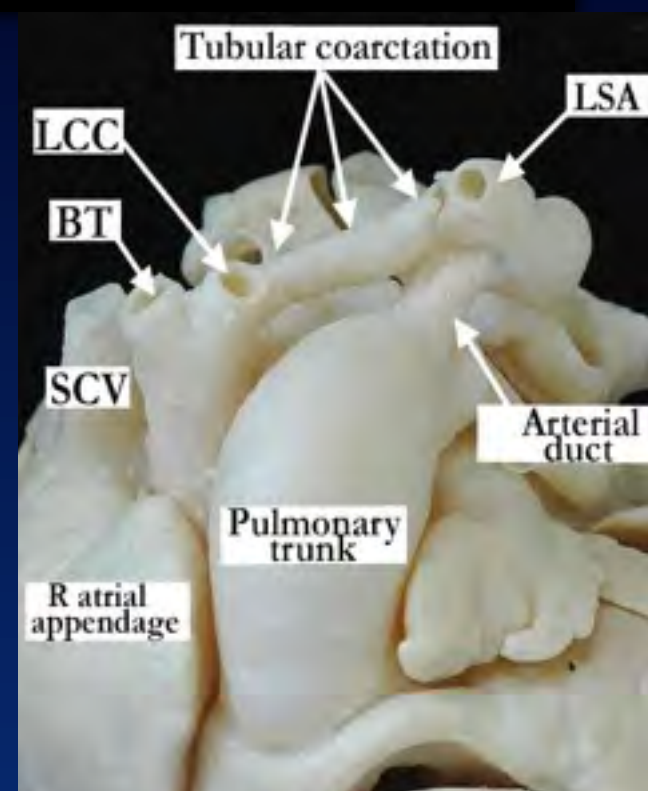
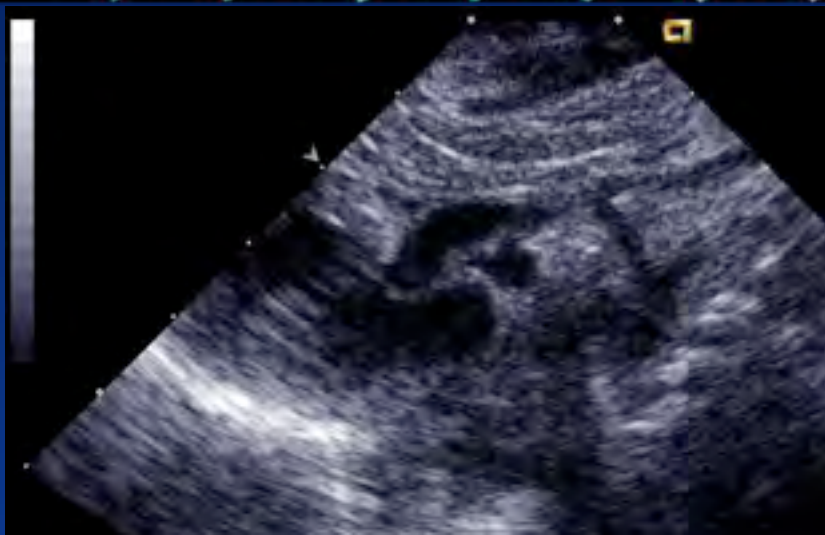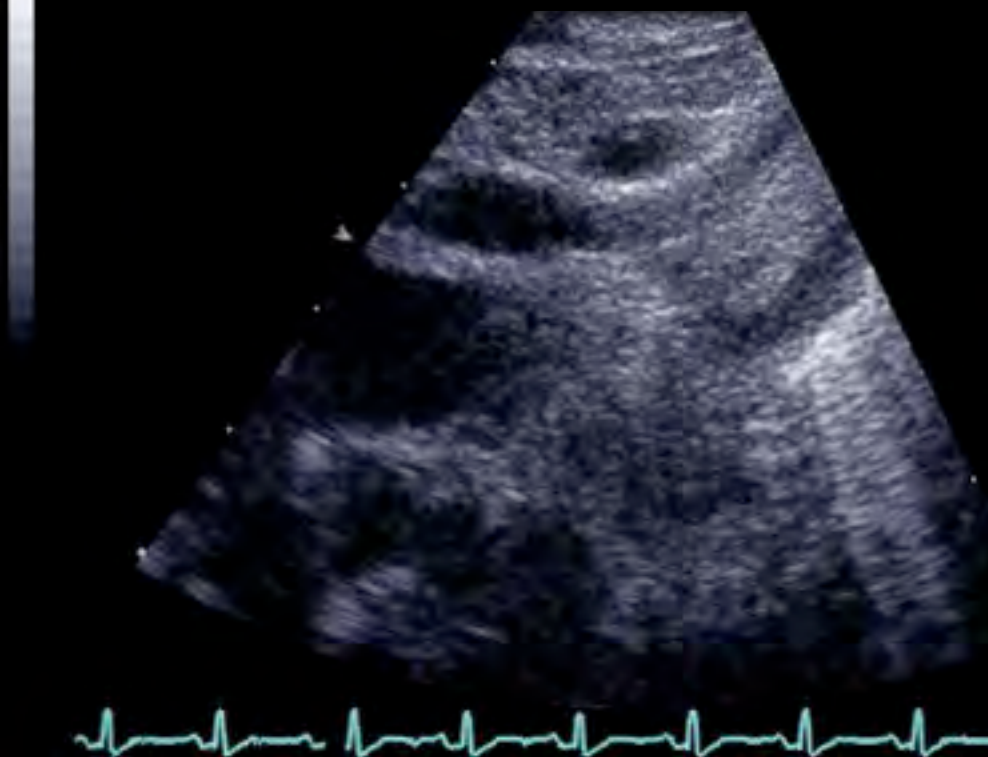Coarctation



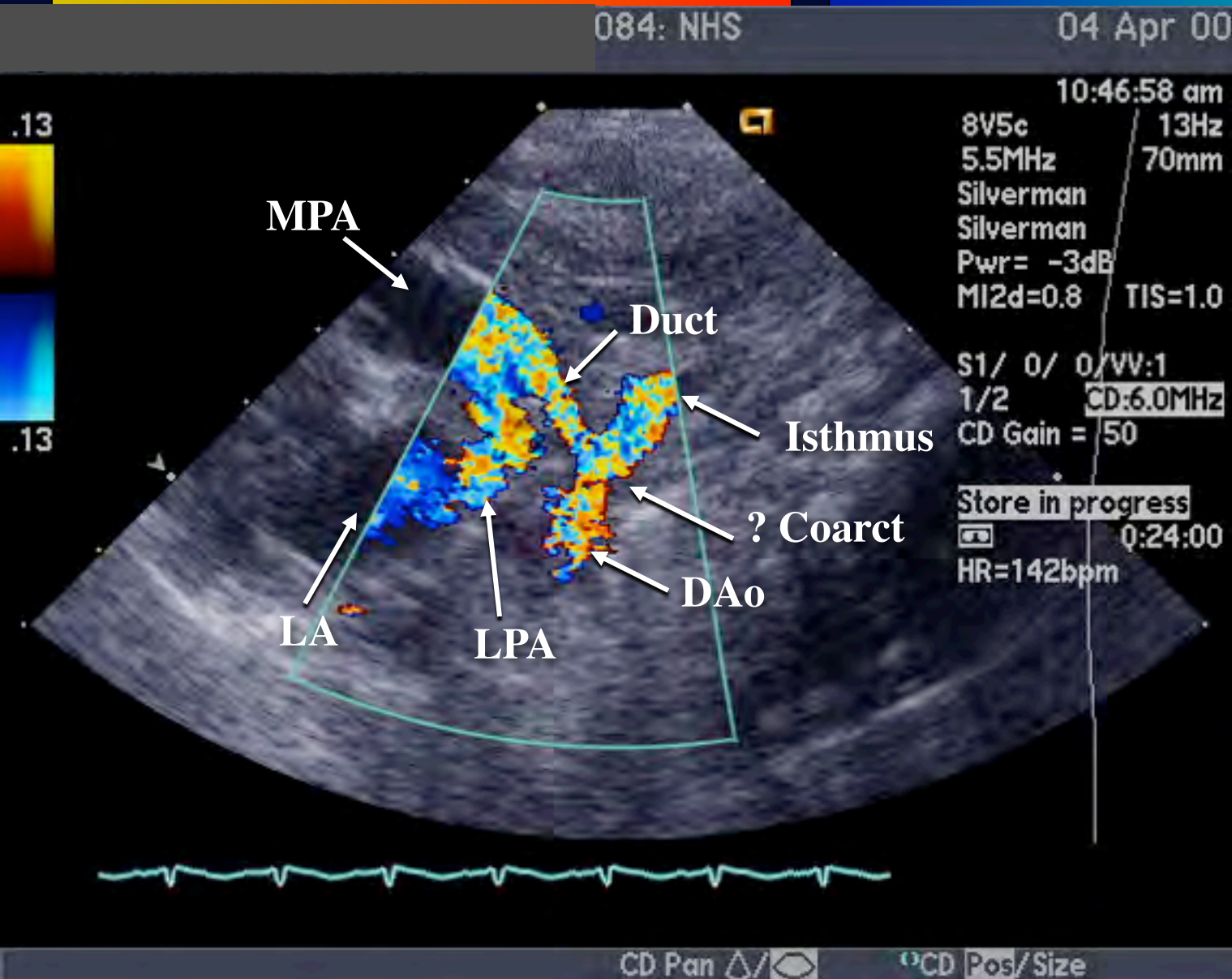
Color Angiogram in Coarctation



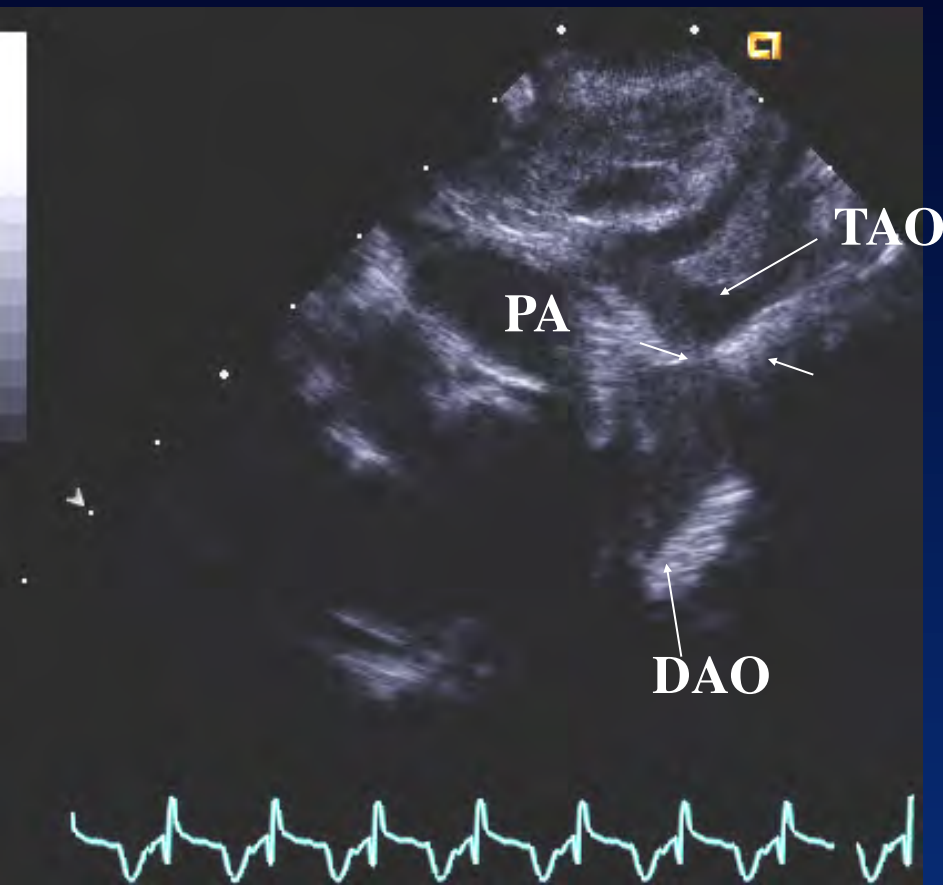
HYPOPLASTIC ISTHMUS



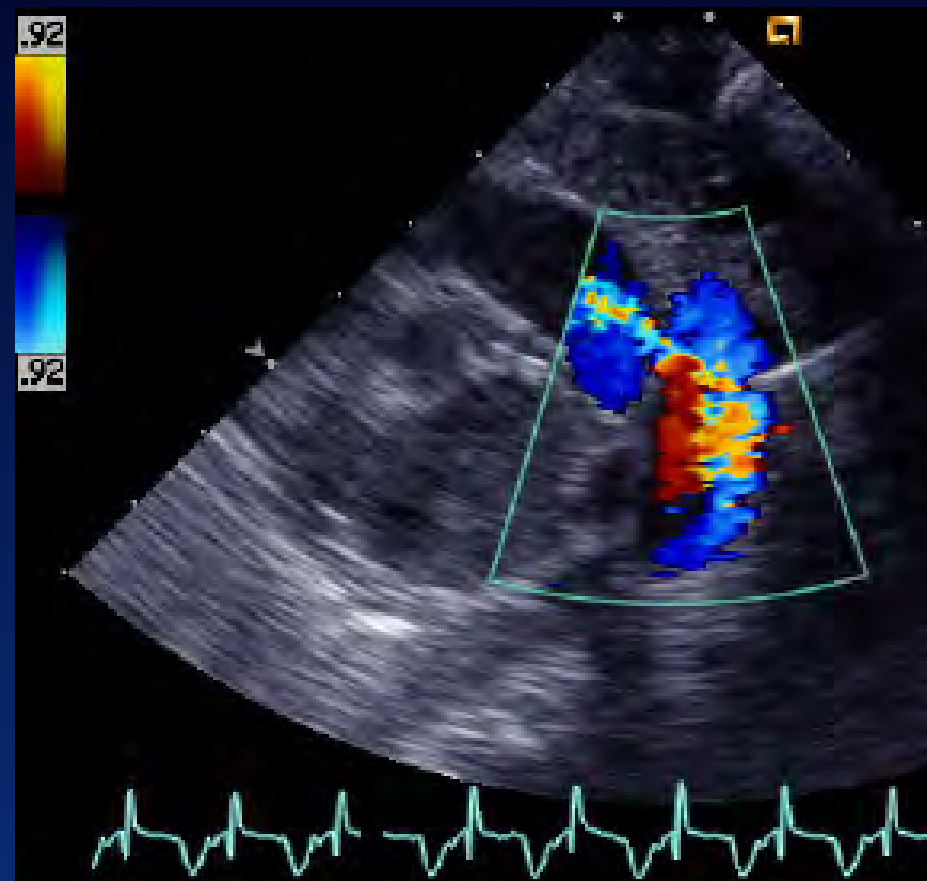
Ductus & ? Coarctation: On Prostaglandin



Coarctation of the Aorta

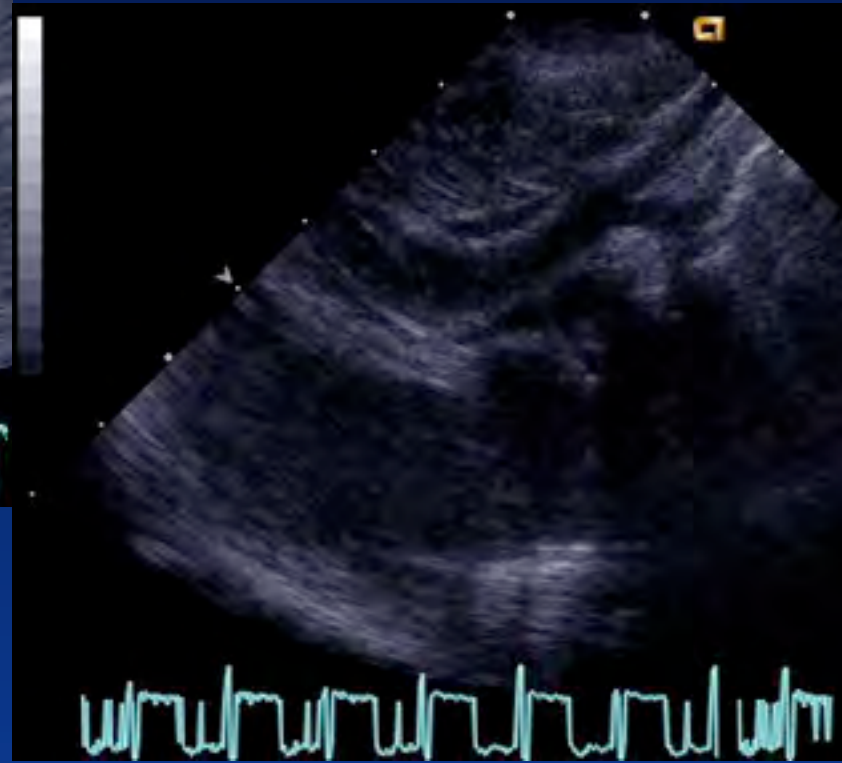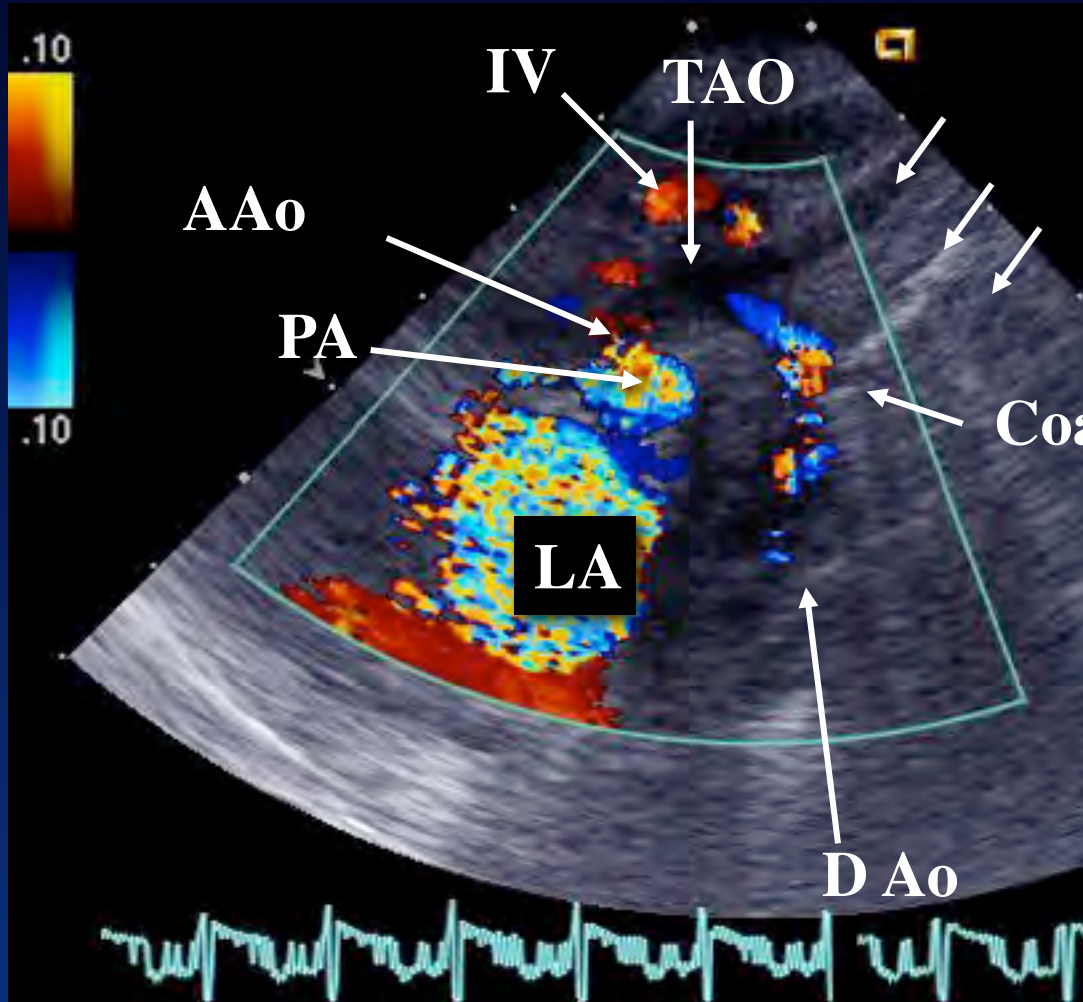


OFF PGE1

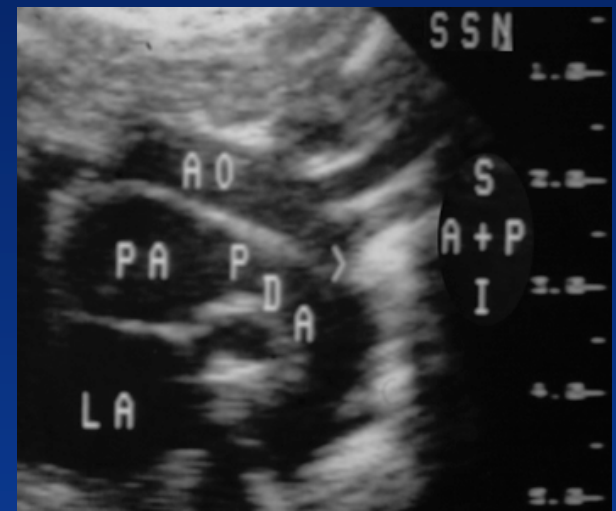
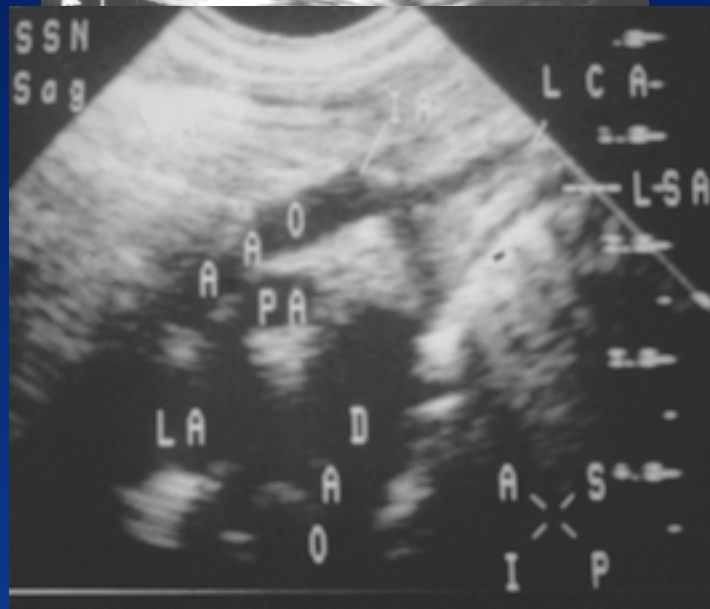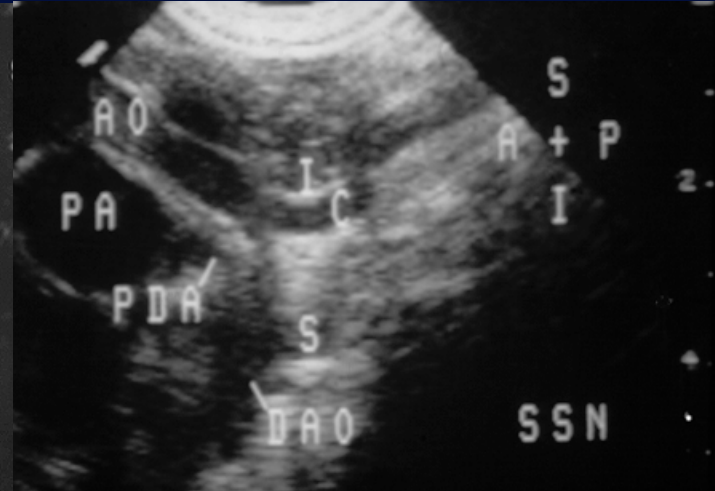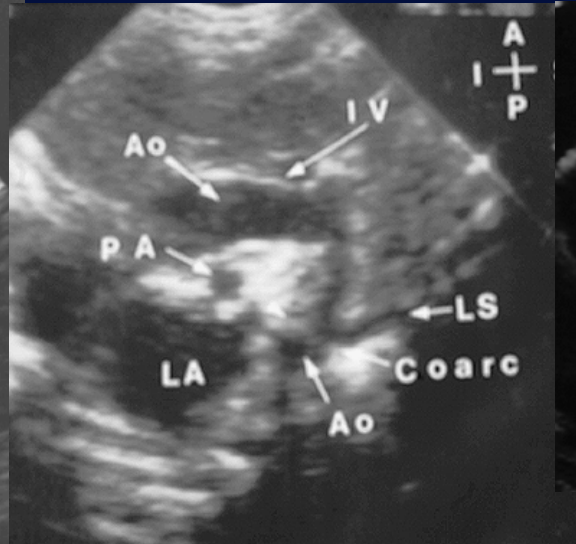
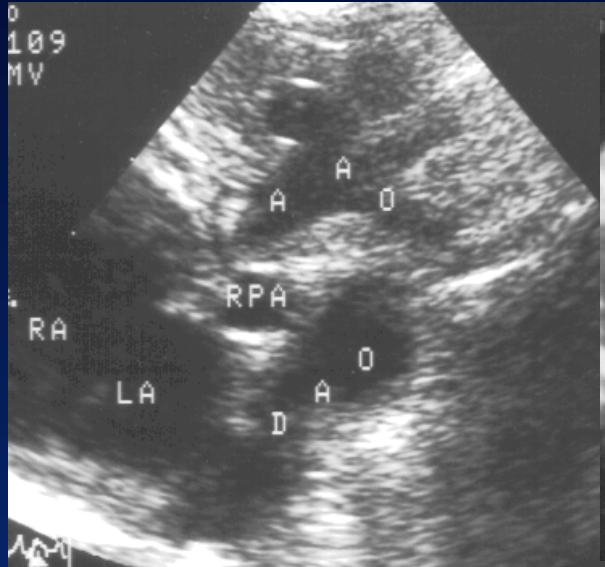


On PGE1

Taussig- Bing Malformation and Coarctation

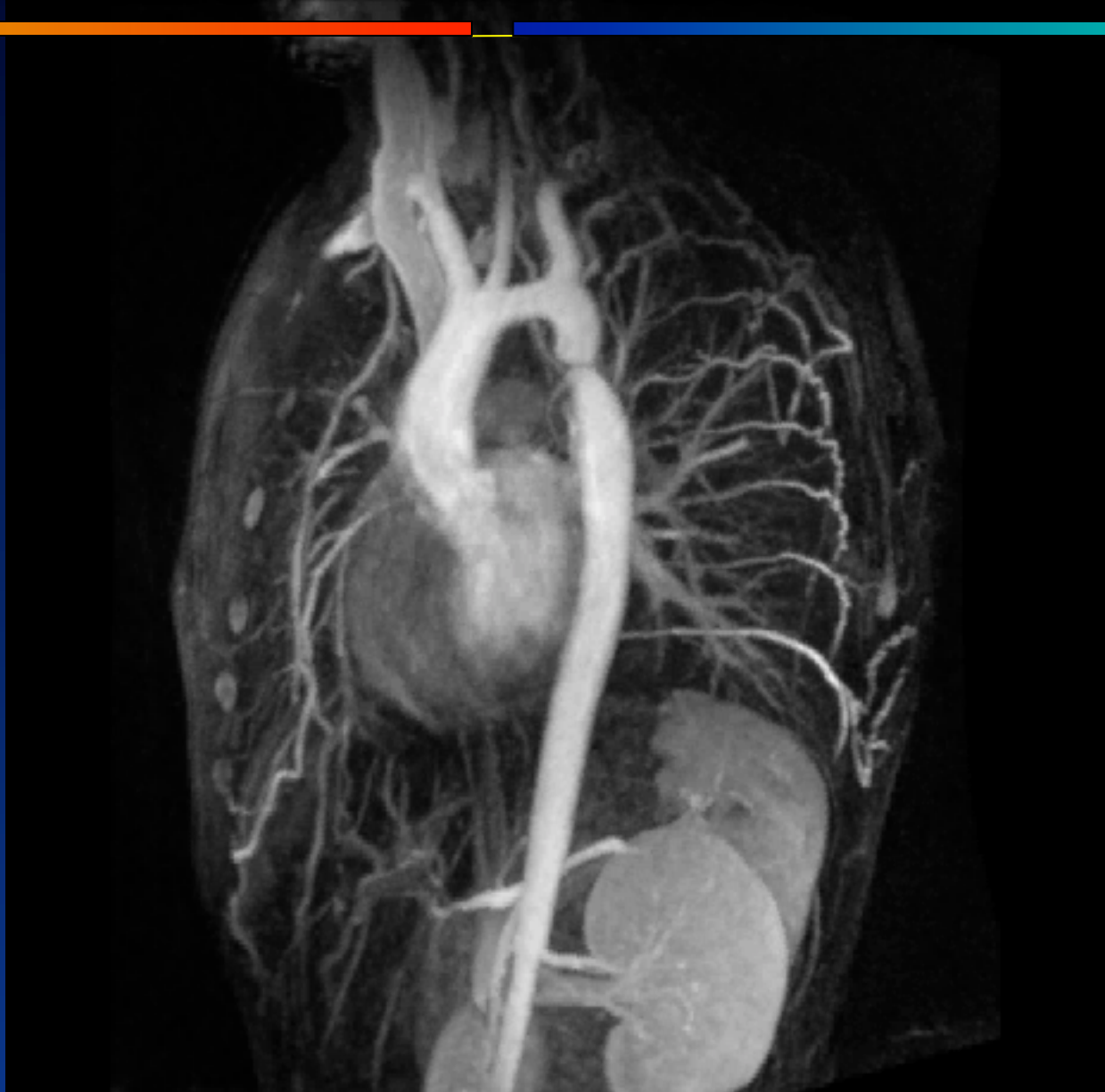

The Diversity of Coarctation

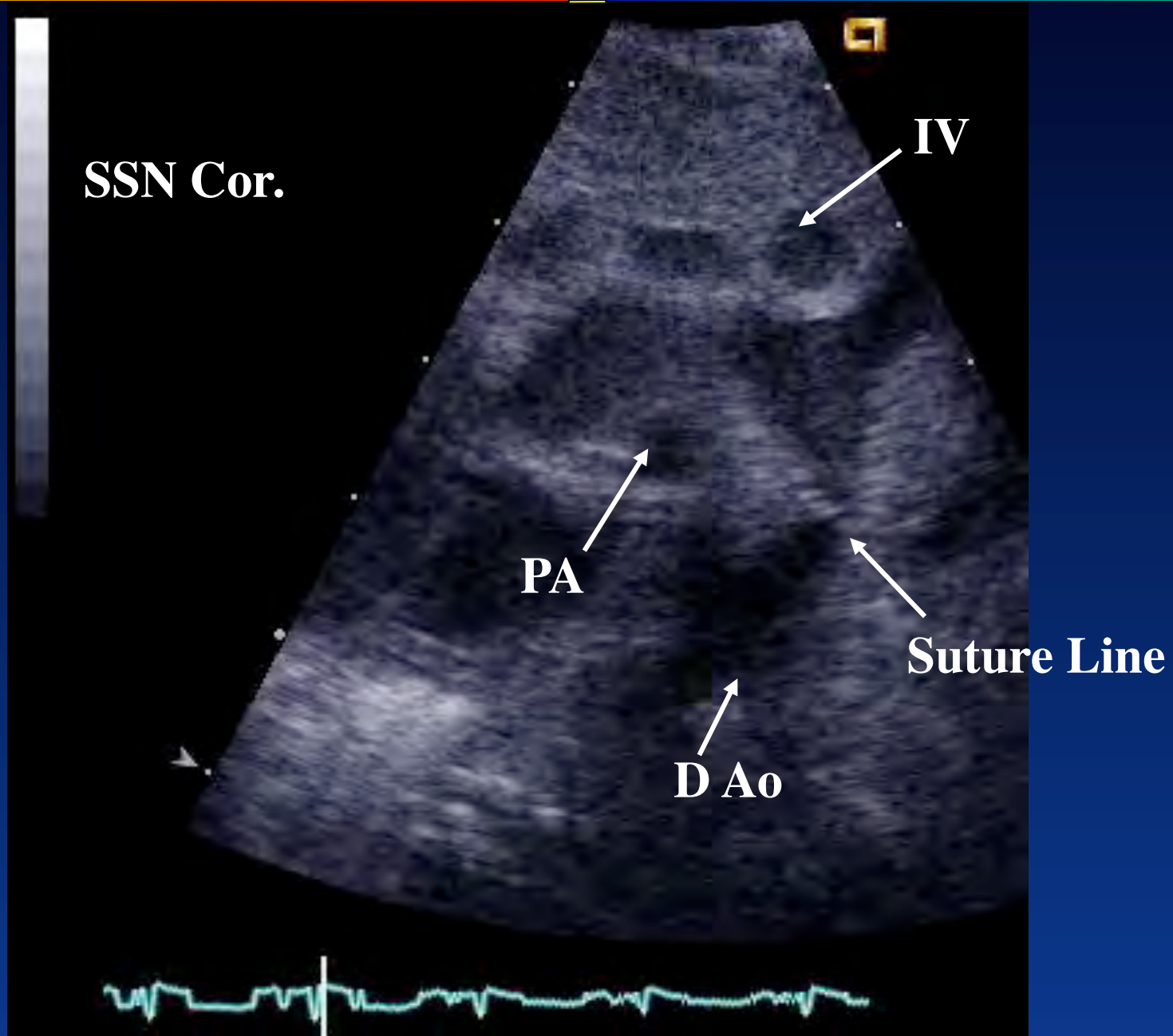


Coarctation-MRI 3 D Reconstruction

Courtesy of
Dr. Keren
Hasbani



Coarctation: End - to - Side Anastomosis



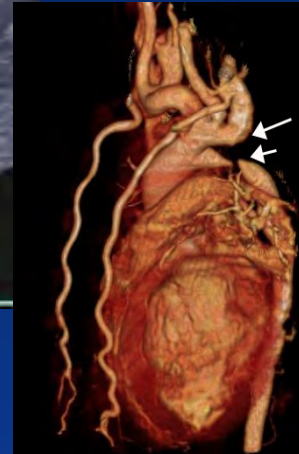
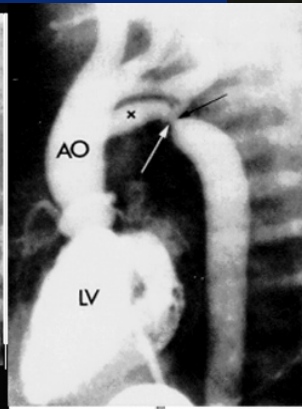
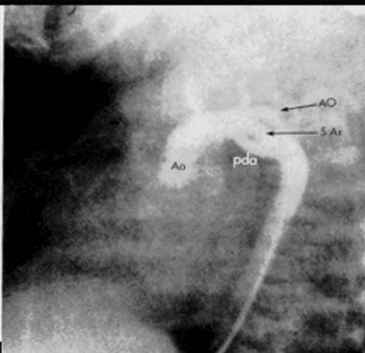
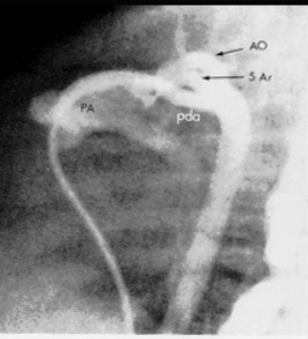
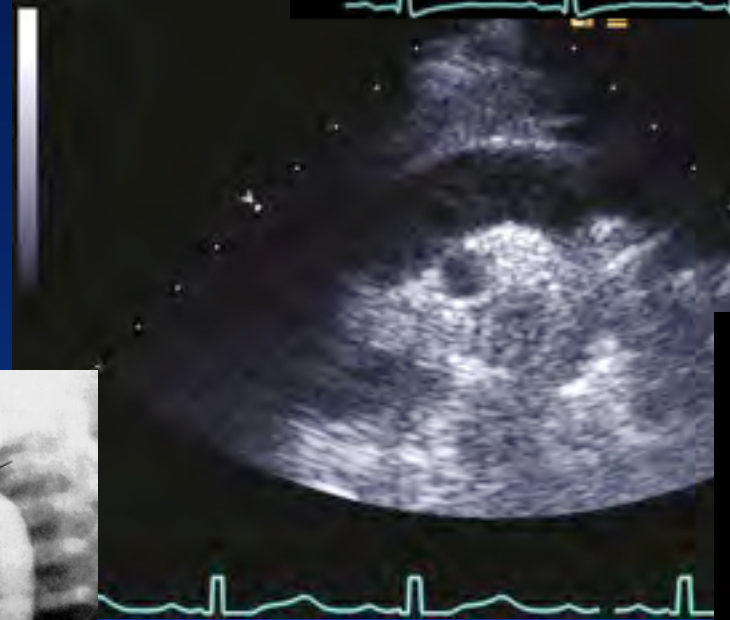
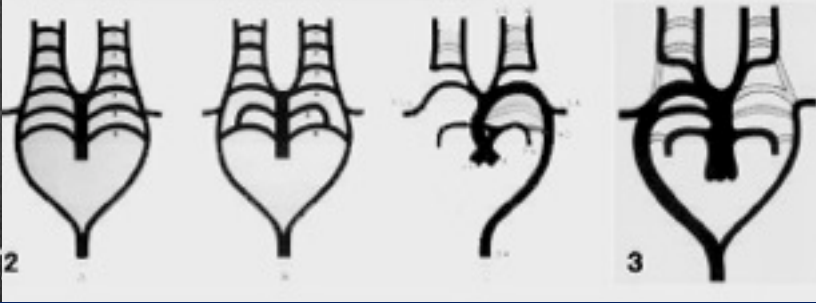
Fifth Aortic Arch

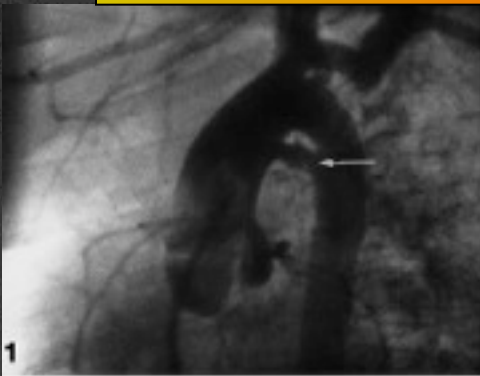

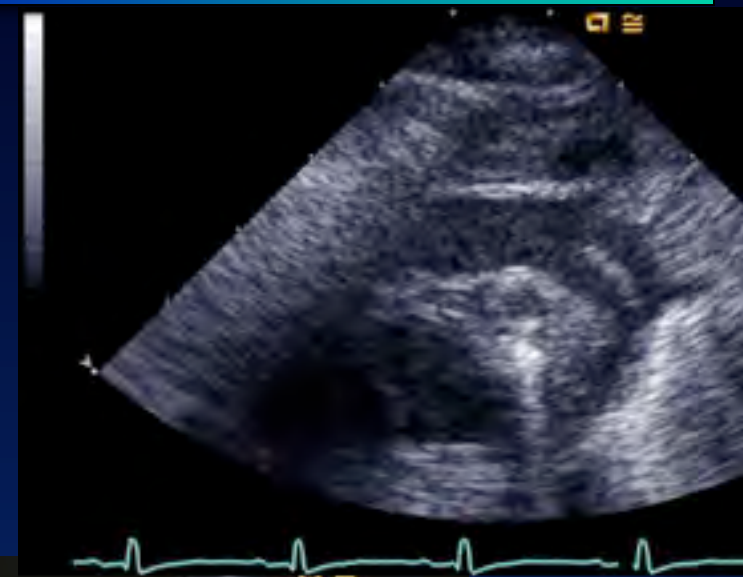Fig.1 Aortogram demonstrating the second lumen (arrow)

Fig.2 Diagram of primitive embryonic arch patterns. **A** and **B** represent potential fifth arch connections and **C** the persisting structures in the normal circulation

Fig.3 Diagram of the case reported with a double-barrelled right-sided arch. Reproduced with permission [1]



Echocardiographic Diagnosis of Persistent Fifth

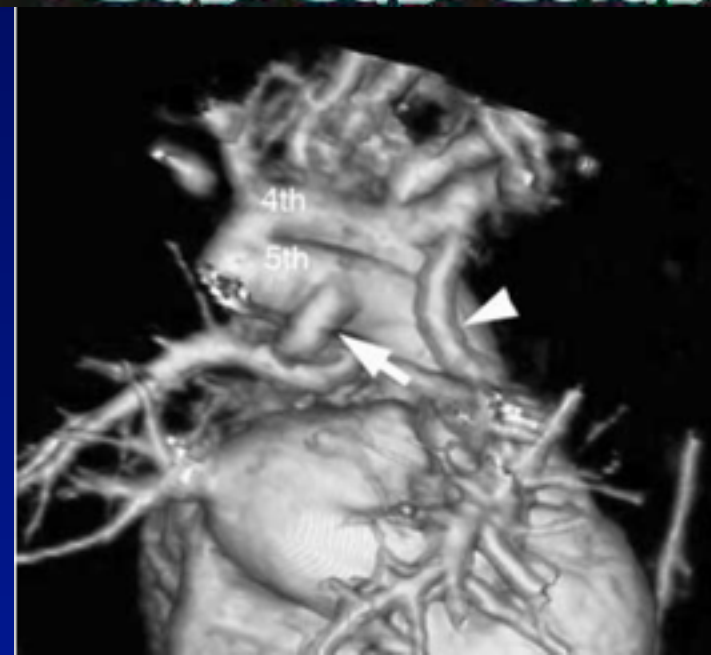
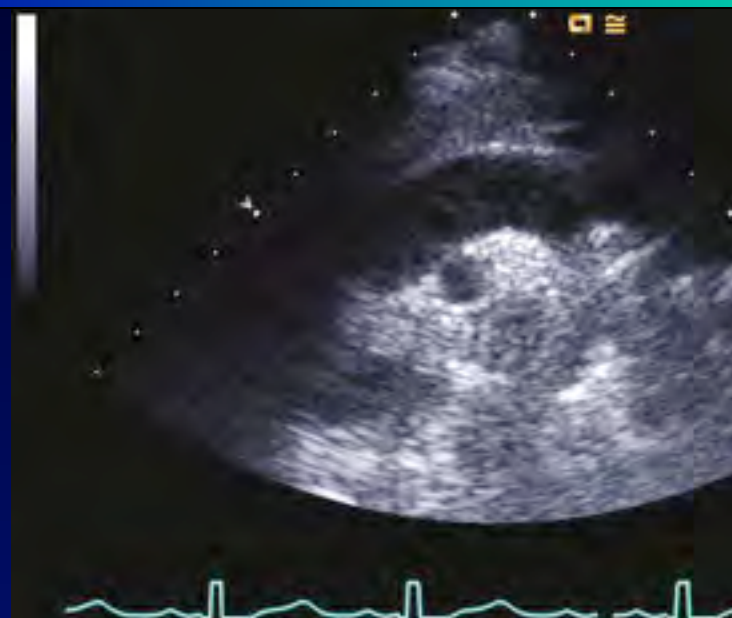
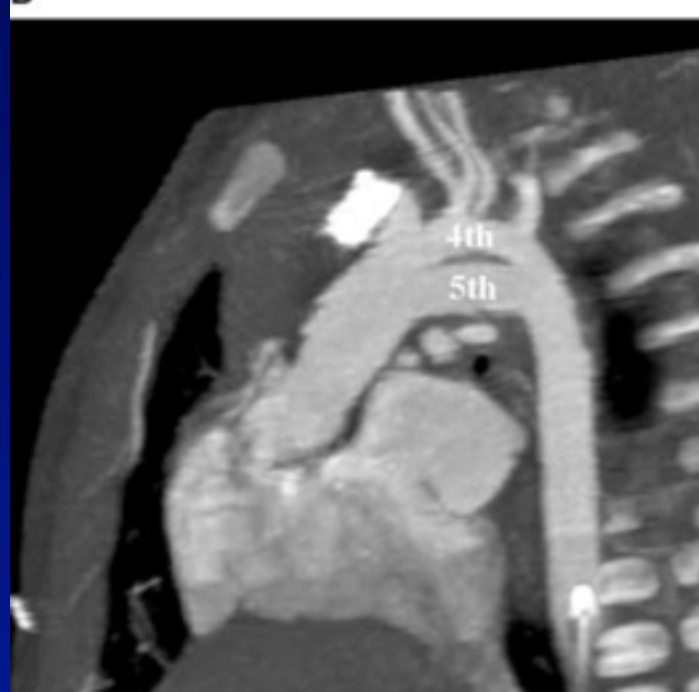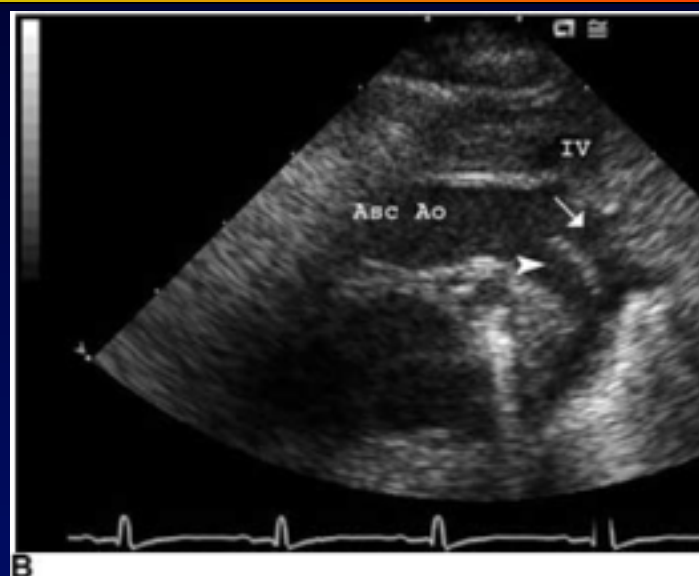
Aortic Arch

Jonathan Bernheimer, M.D.,* Mark Friedberg, M.D.,* Frandies Chan, M.D.,†

and Norman Silverman, M.D.*

Vol. 24, No. 3, 2007

ECHOCARDIOGRAPHY:



Interrupted Aortic Arch: Associations

- **Ventricular septal defect**
- **Catch 22 Syndrome**
- **Truncus arteriosus**
- **Aortopulmonary Window**
- **Taussig Bing Malformation**

Aortic Arch Interruption

Found with:-

22 Q-

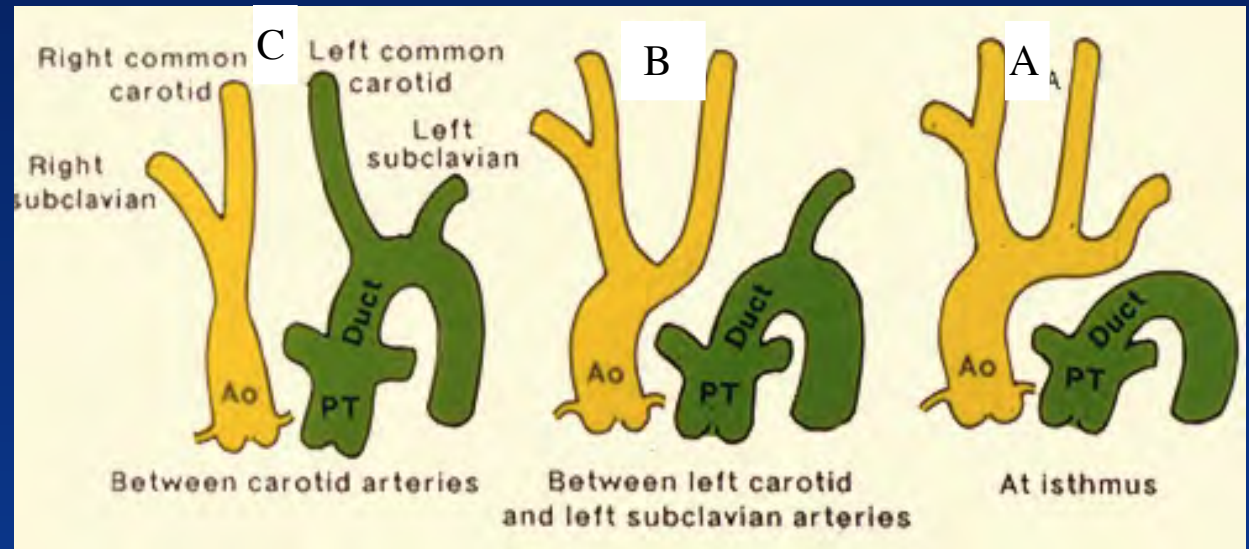
Truncus Arteriosus

Taussig Bing

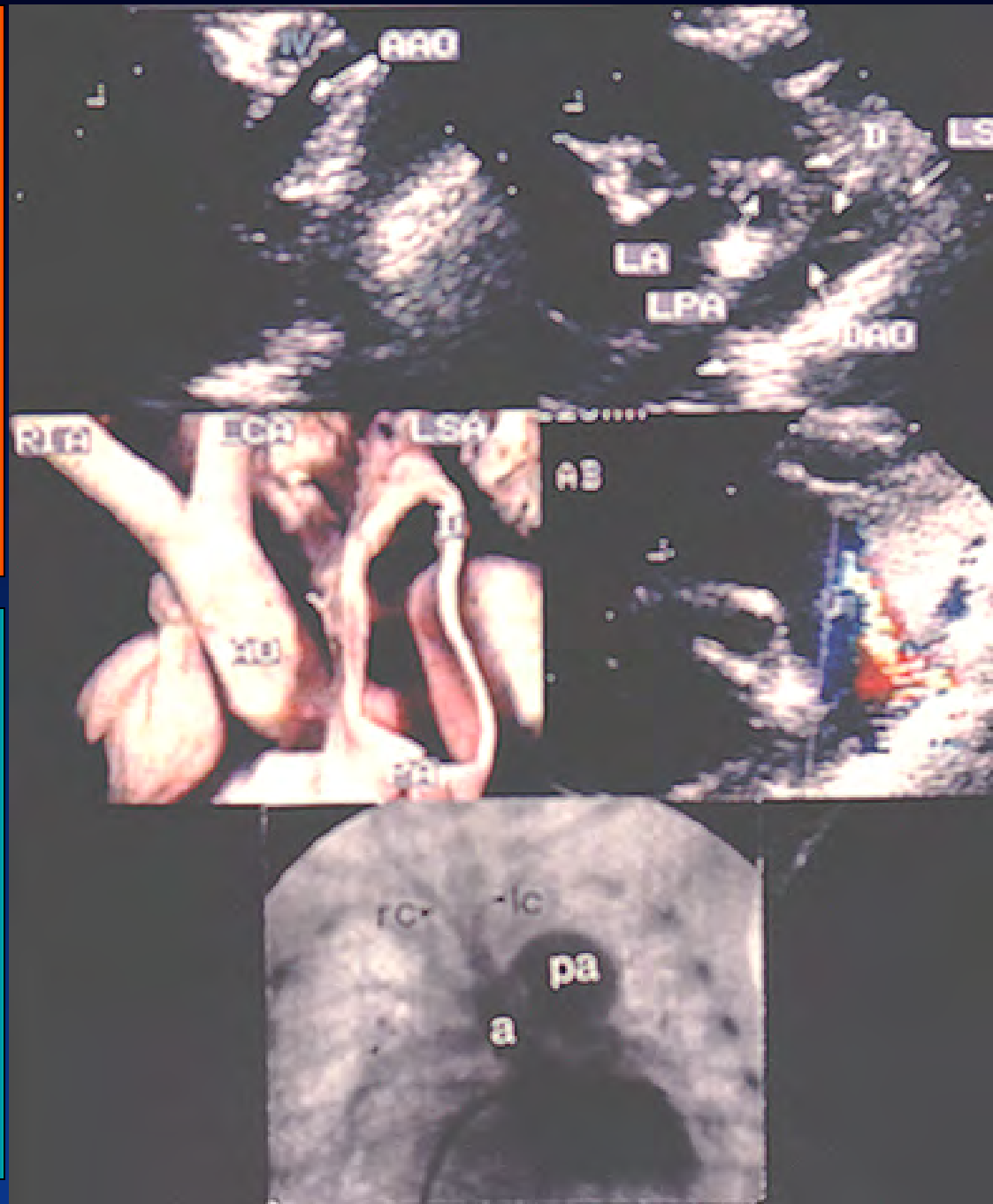
Aortopulmonary

Window

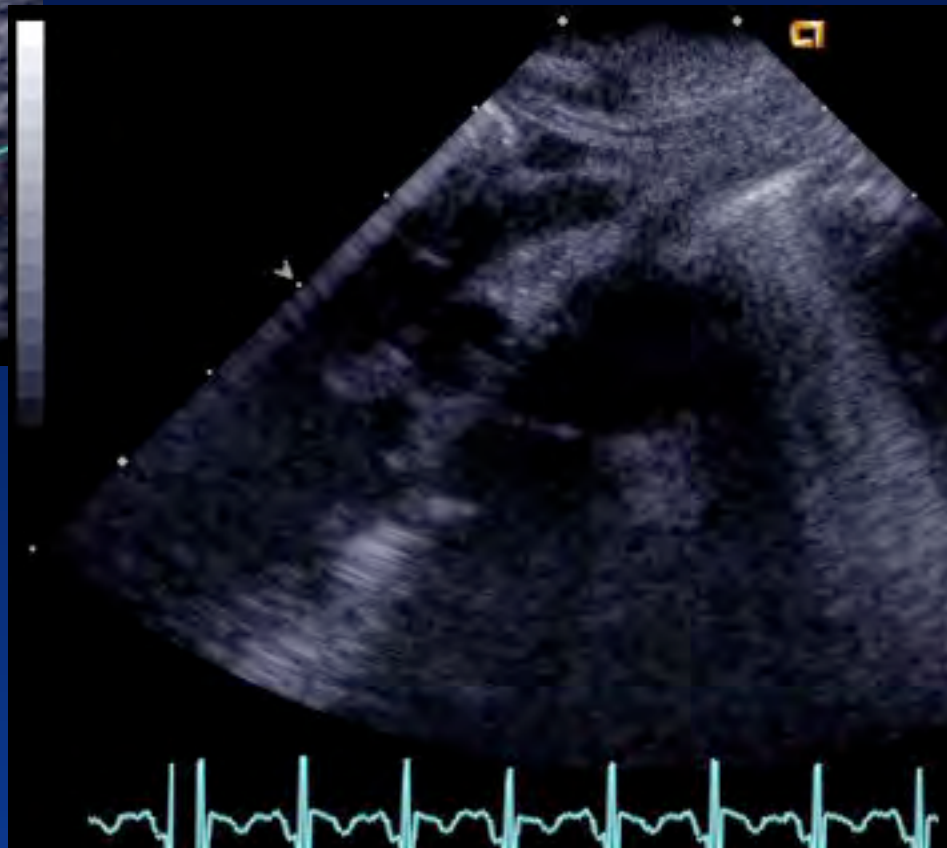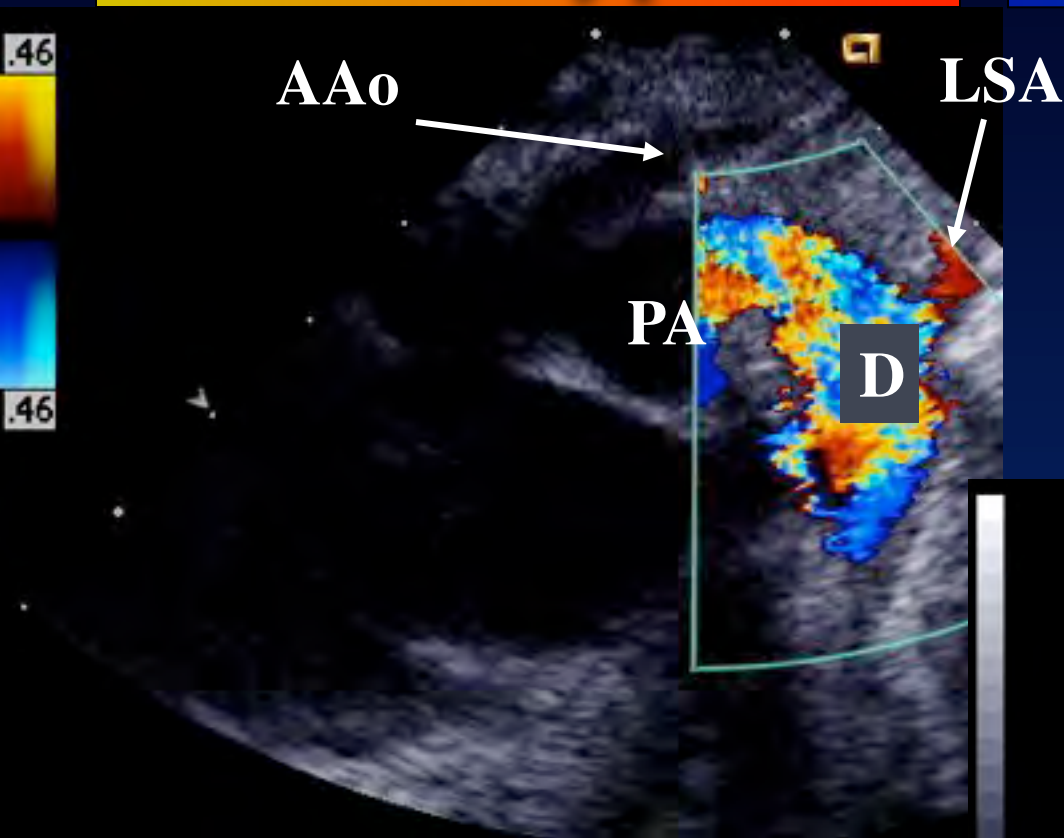
VSD



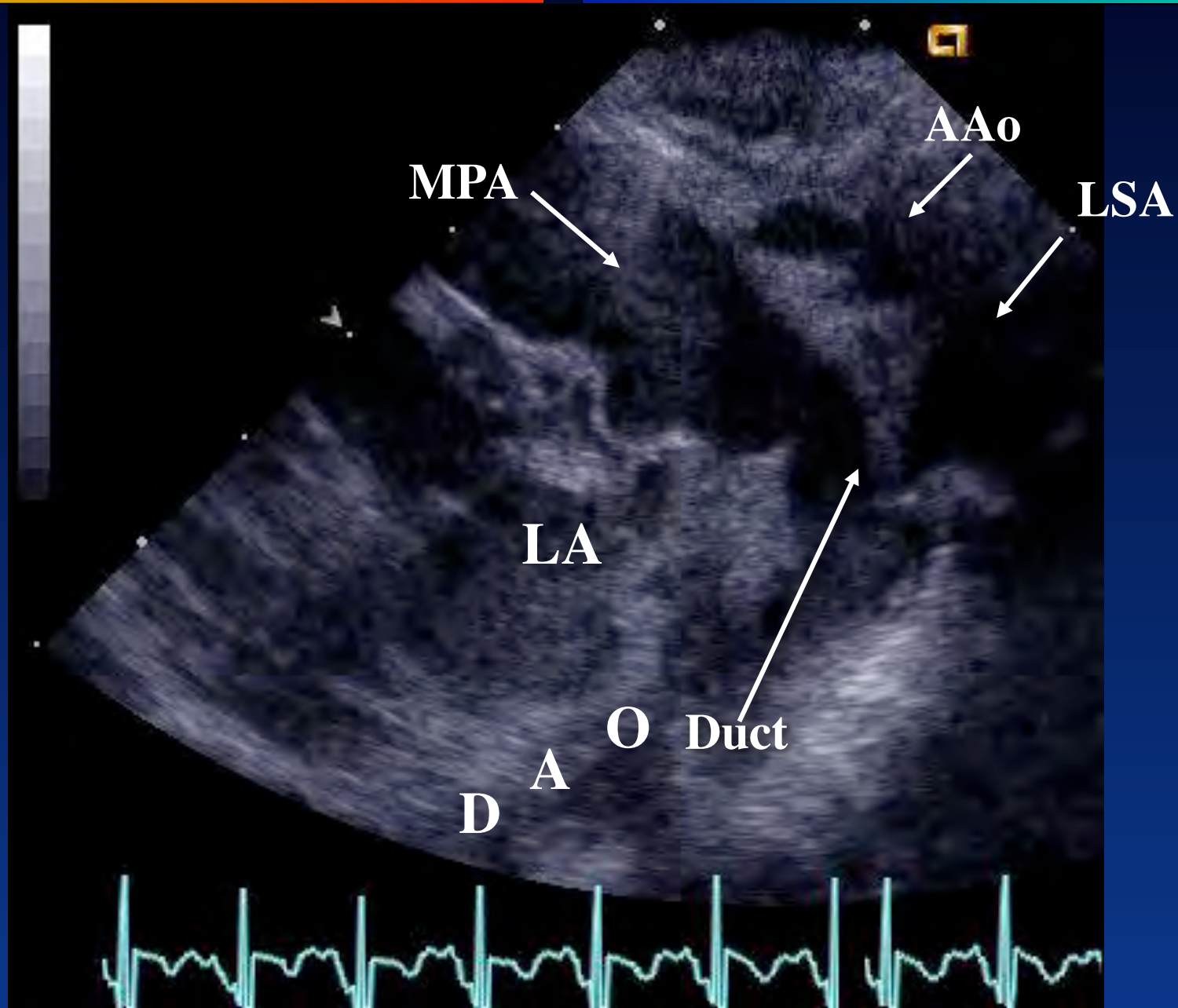
Aortic Arch Interruption



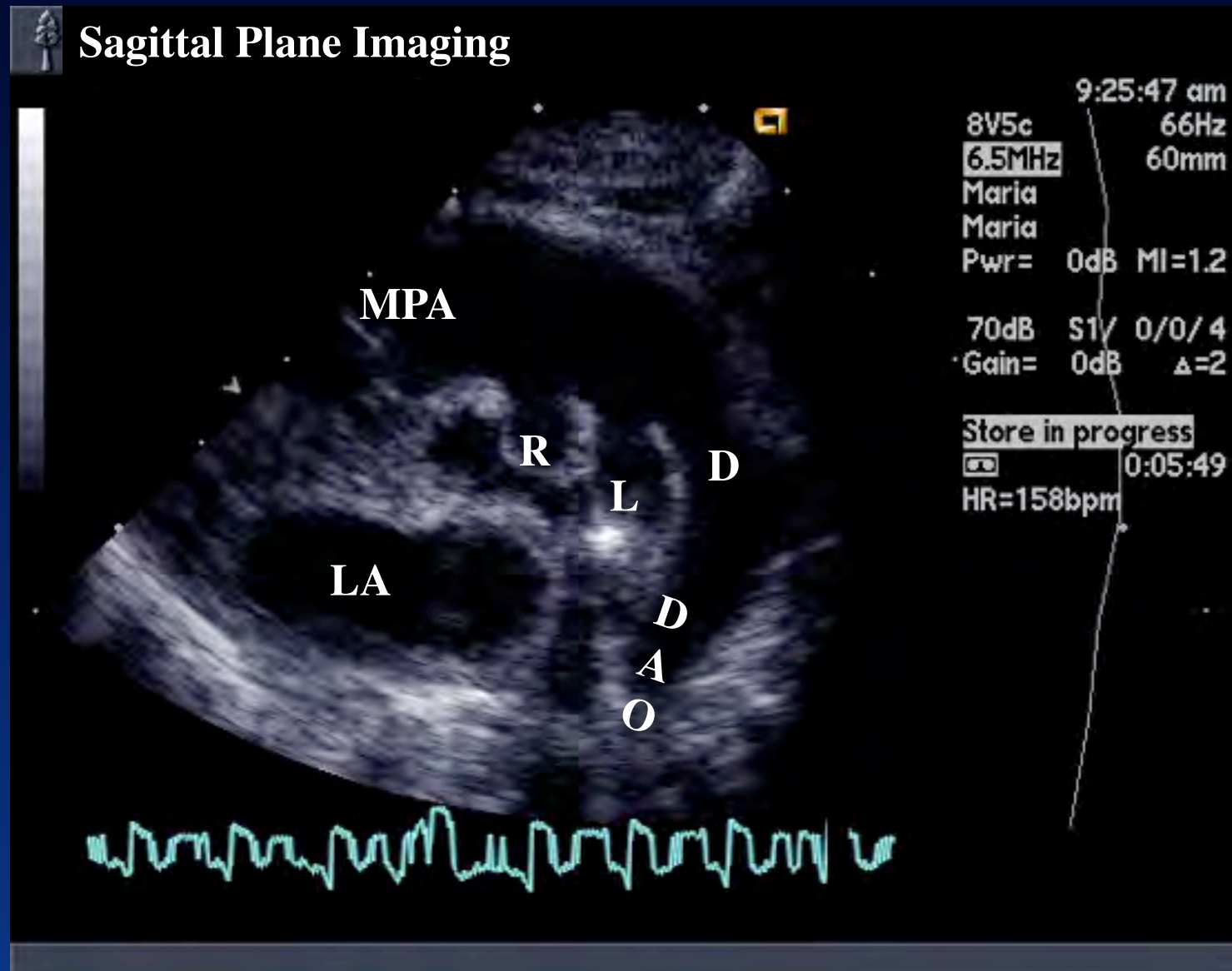
Type B Interruption



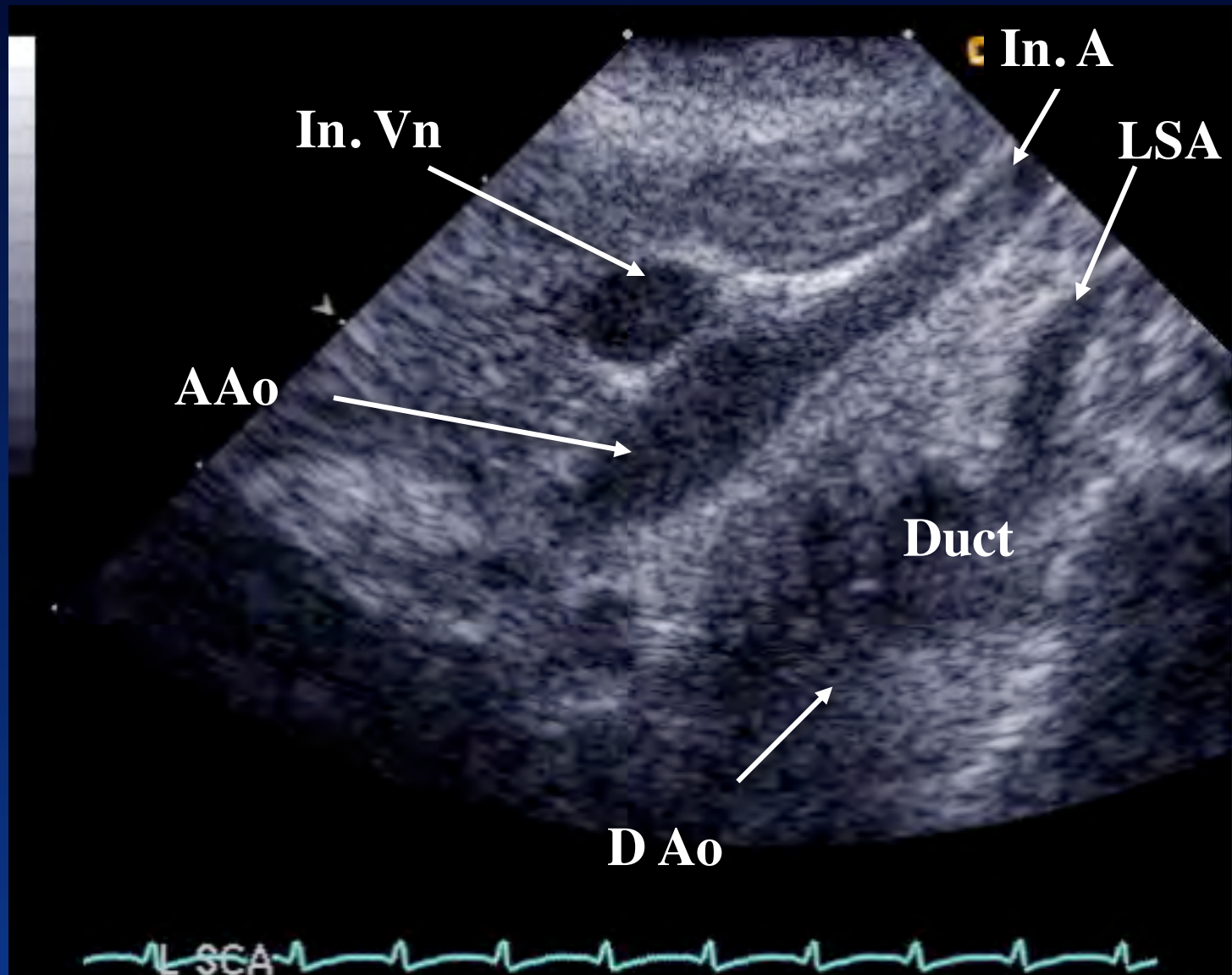
Type B Interruption: Ductus & Descending Aorta




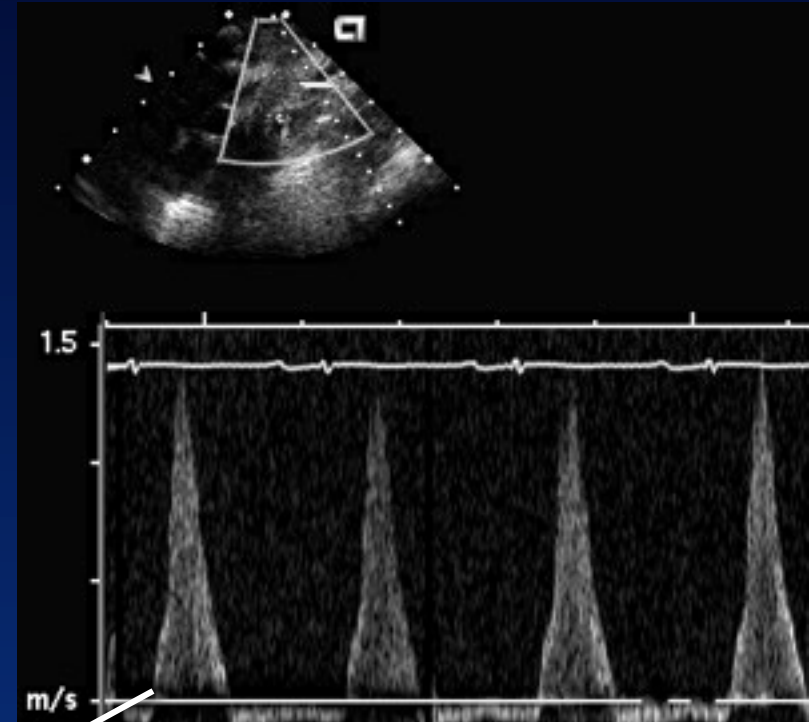
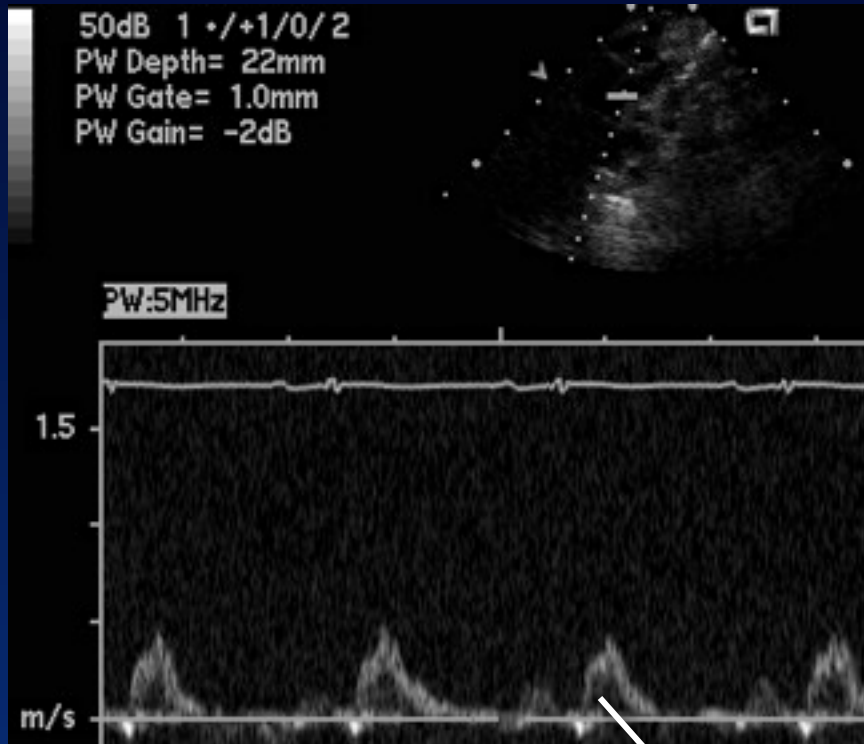
Interrupted Aortic Arch



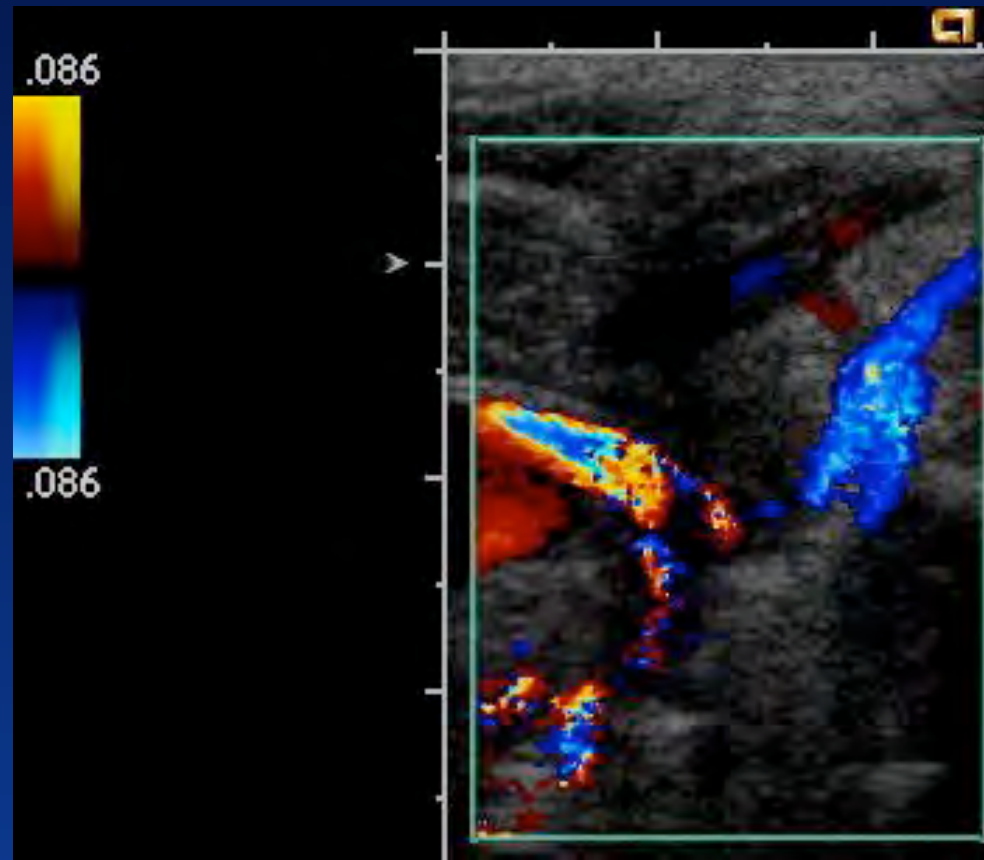
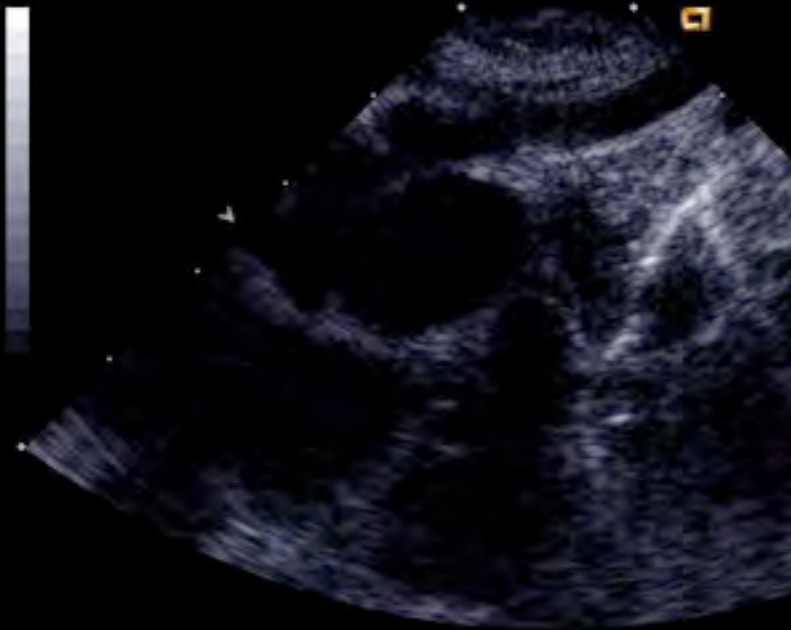
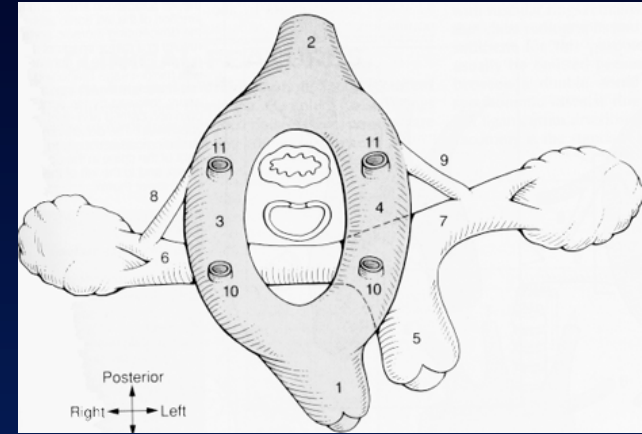
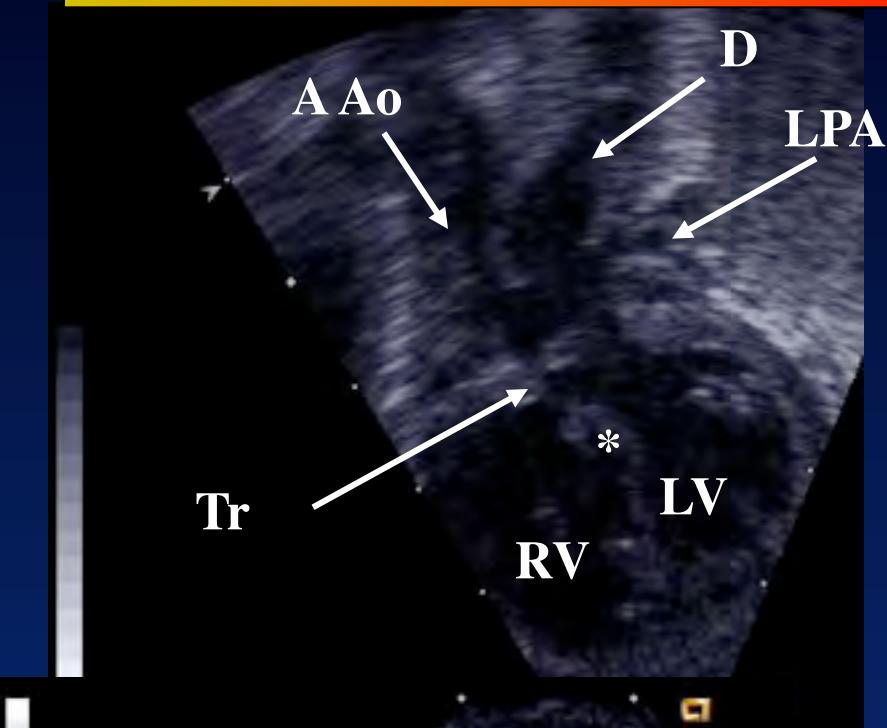
INTERRUPTED ARCH TYPE B



Interrupted Arch: 2 Different Doppler Signals



Truncus with Interrupted Aortic Arch



The VSD in Interruption & Coarctation

A4Ch.

Ao
RV
LV



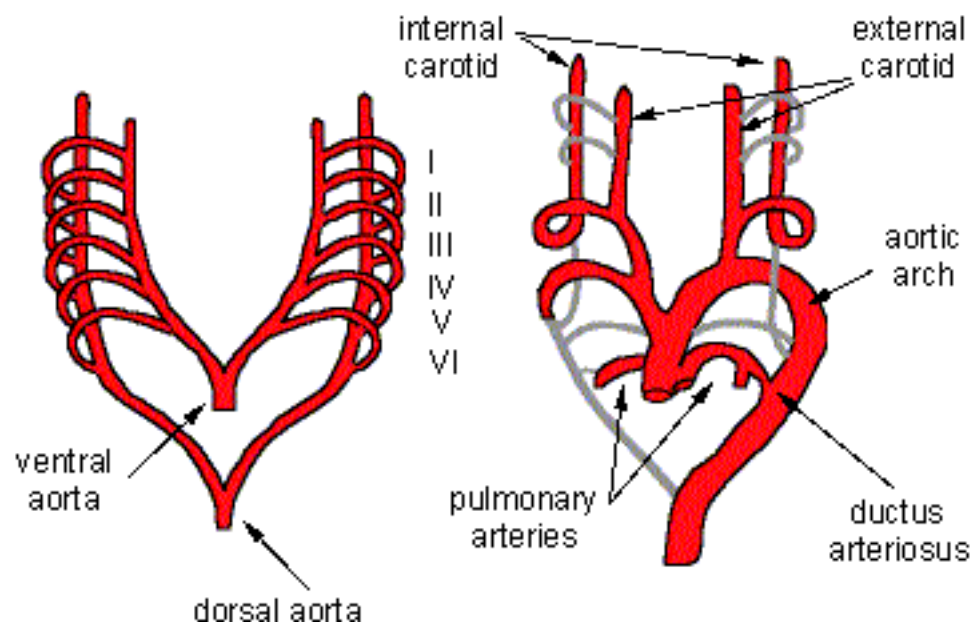
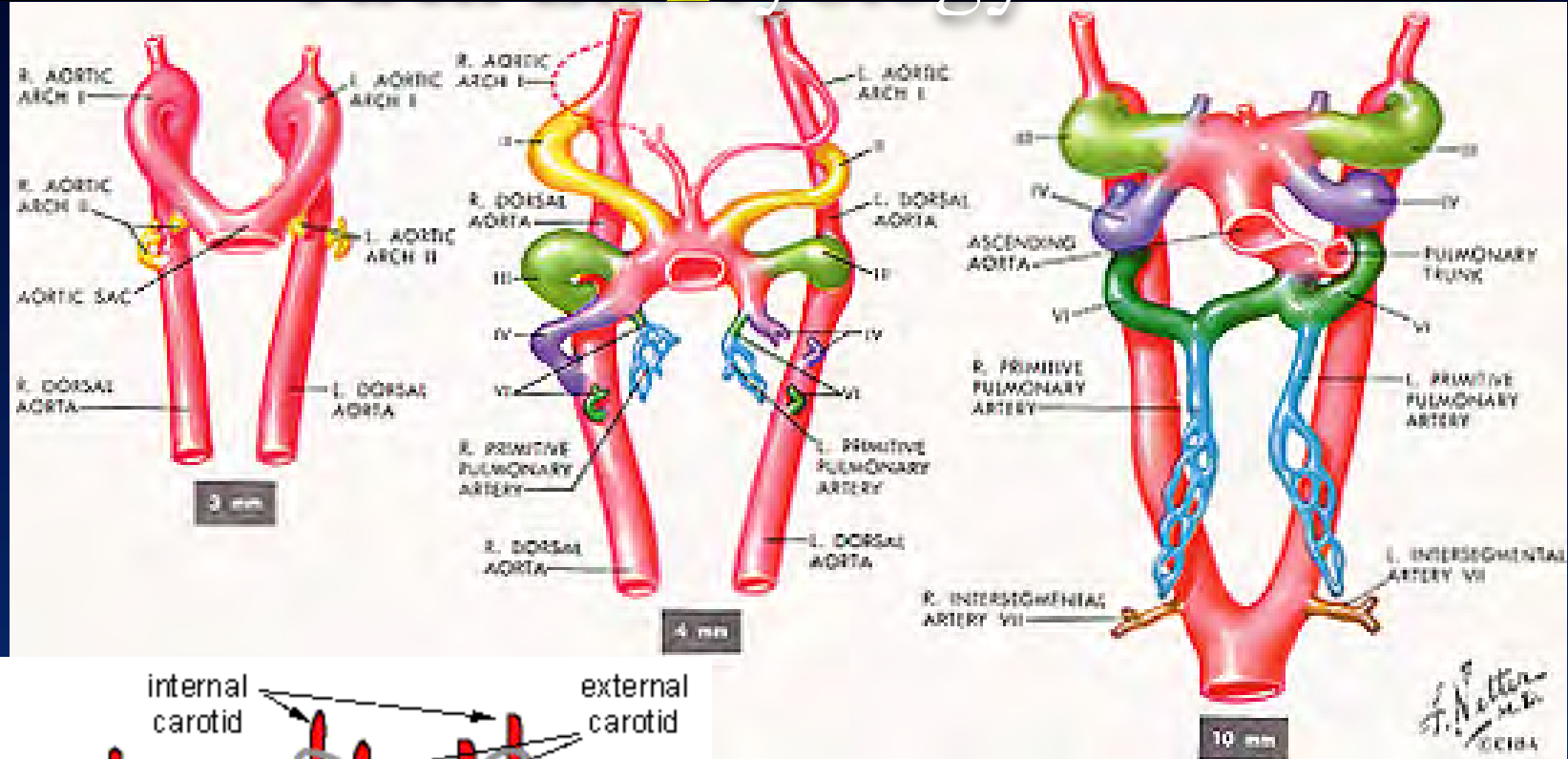
In Coarctation and interruption of the aortic arch, all the woe, lies below!
Richard Van Praagh.

PLx

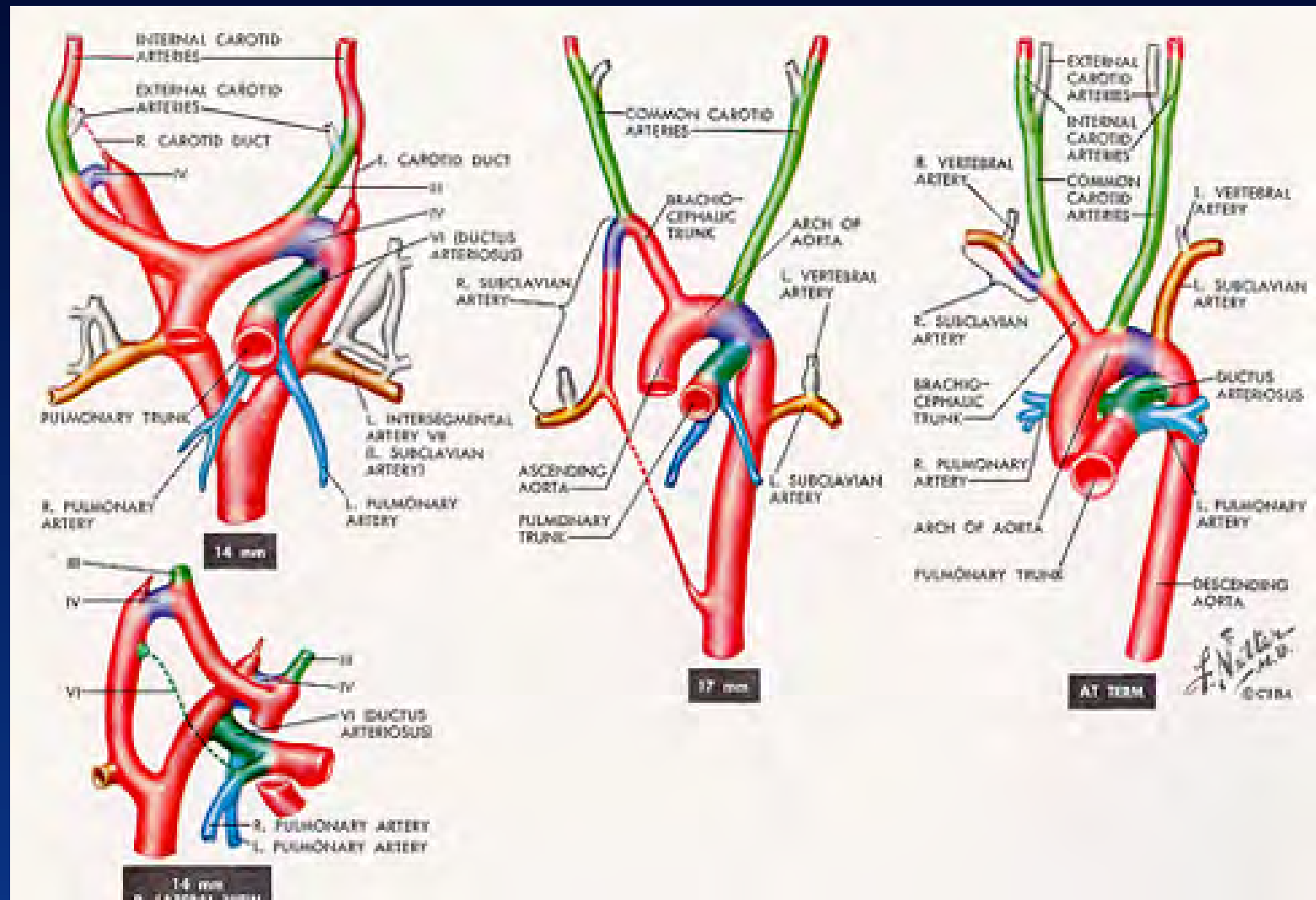
RV
LV
Ao
LA



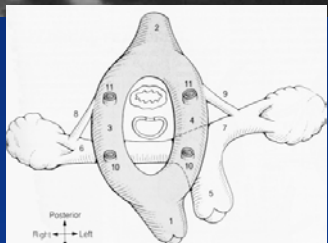
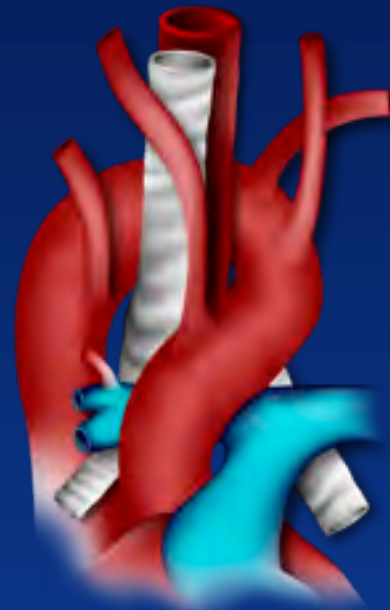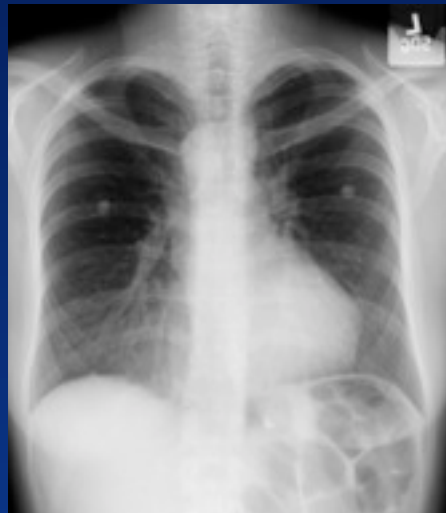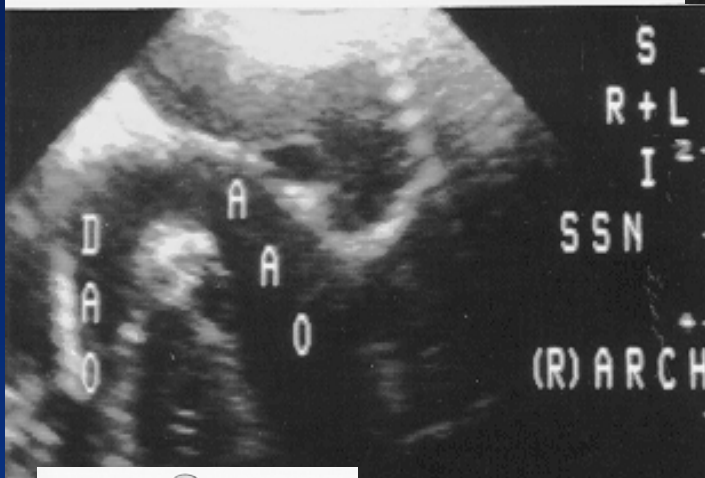
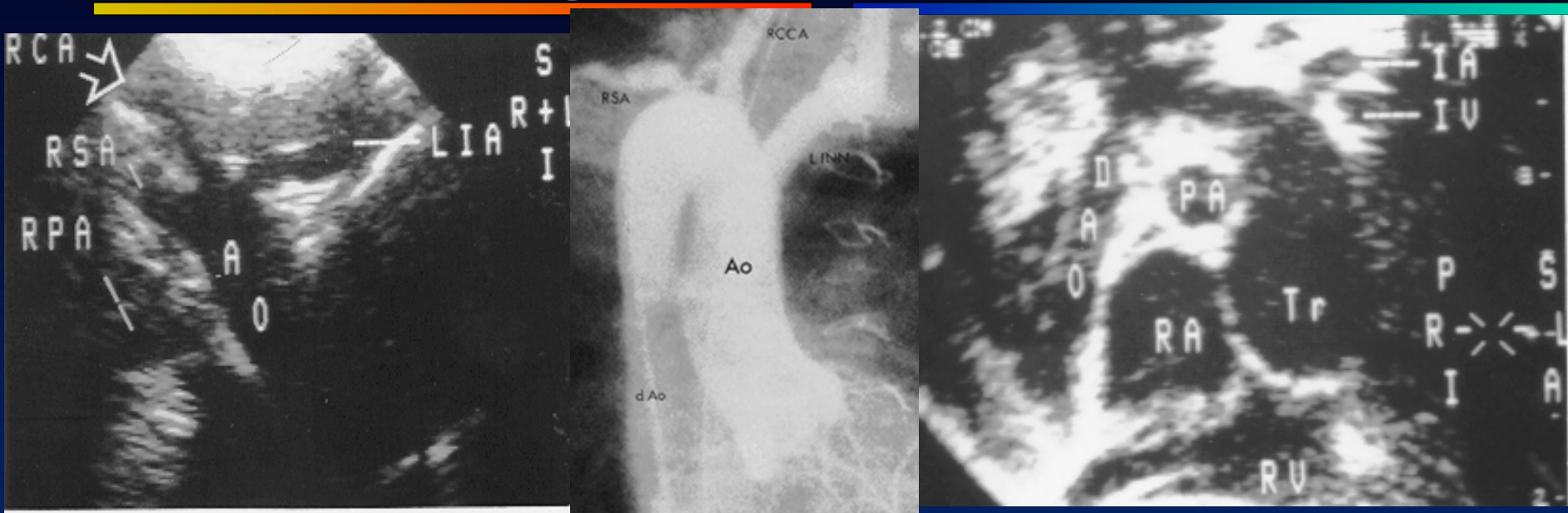
Arch Embryology



Arch Embryology

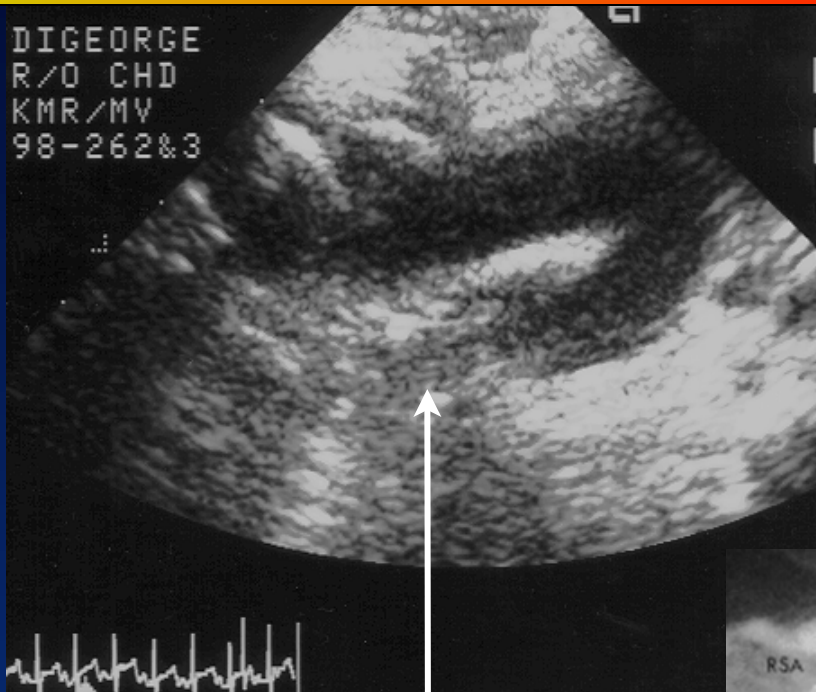


Right Aortic Arch

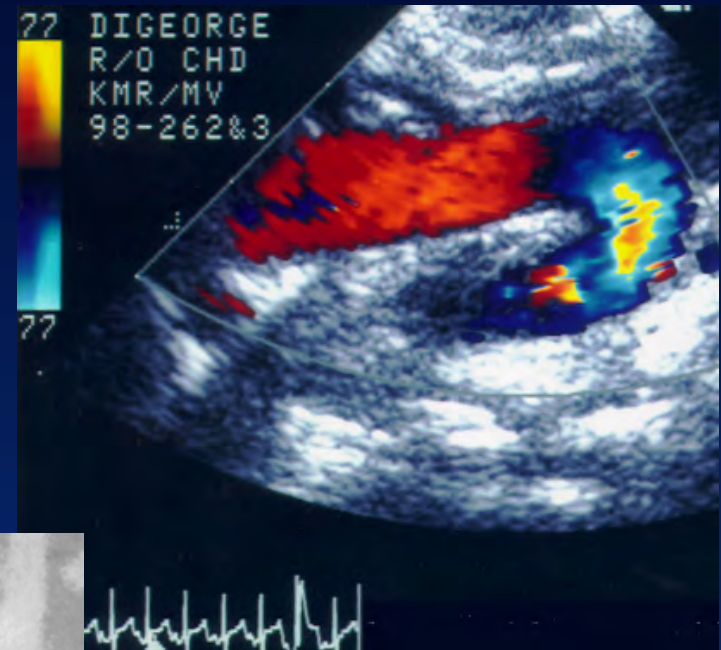
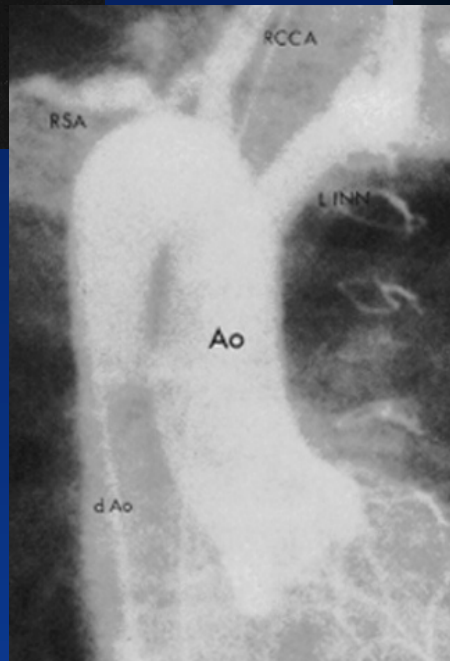


Left Arch: Cervical Arch and Right Ductus

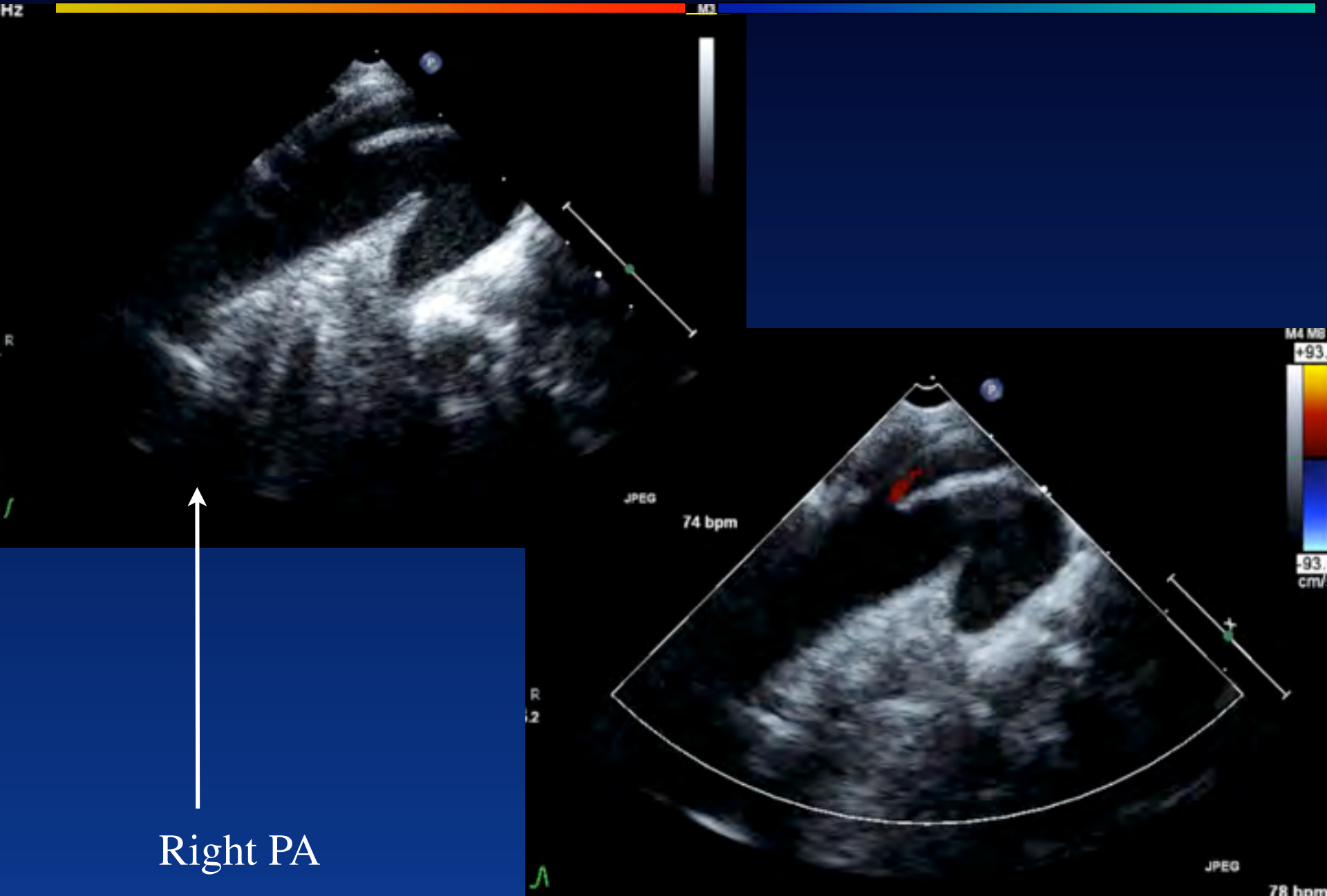
High (Cervical) Arch

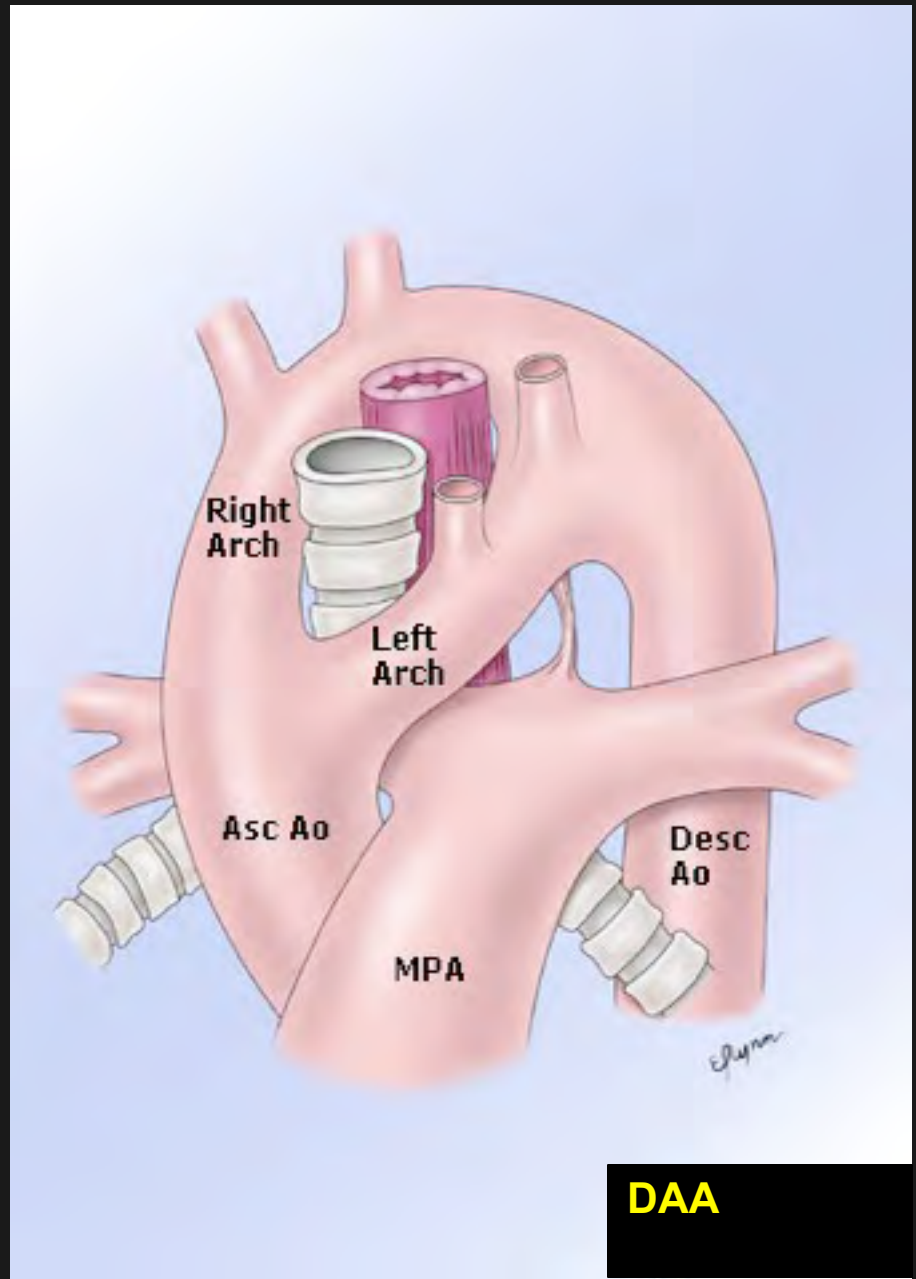
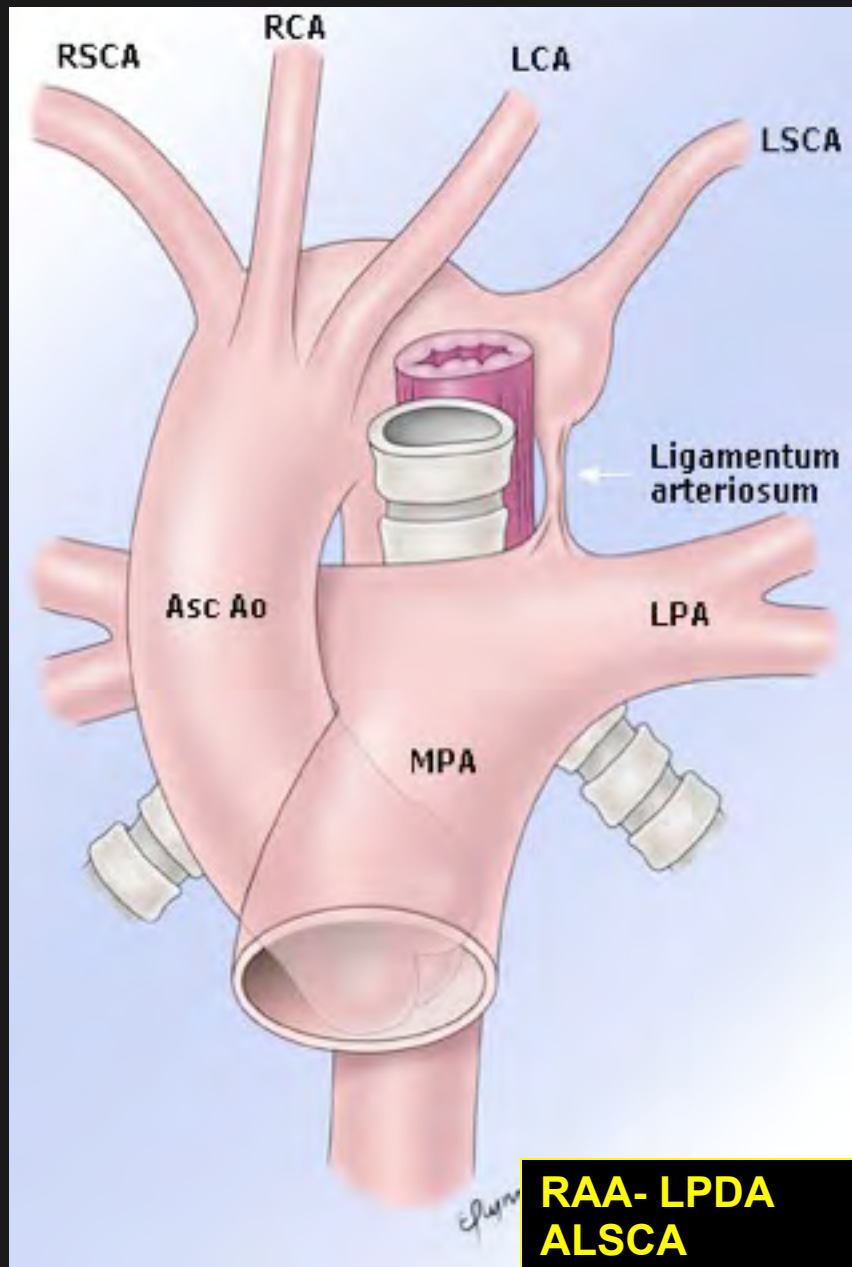


Right PA



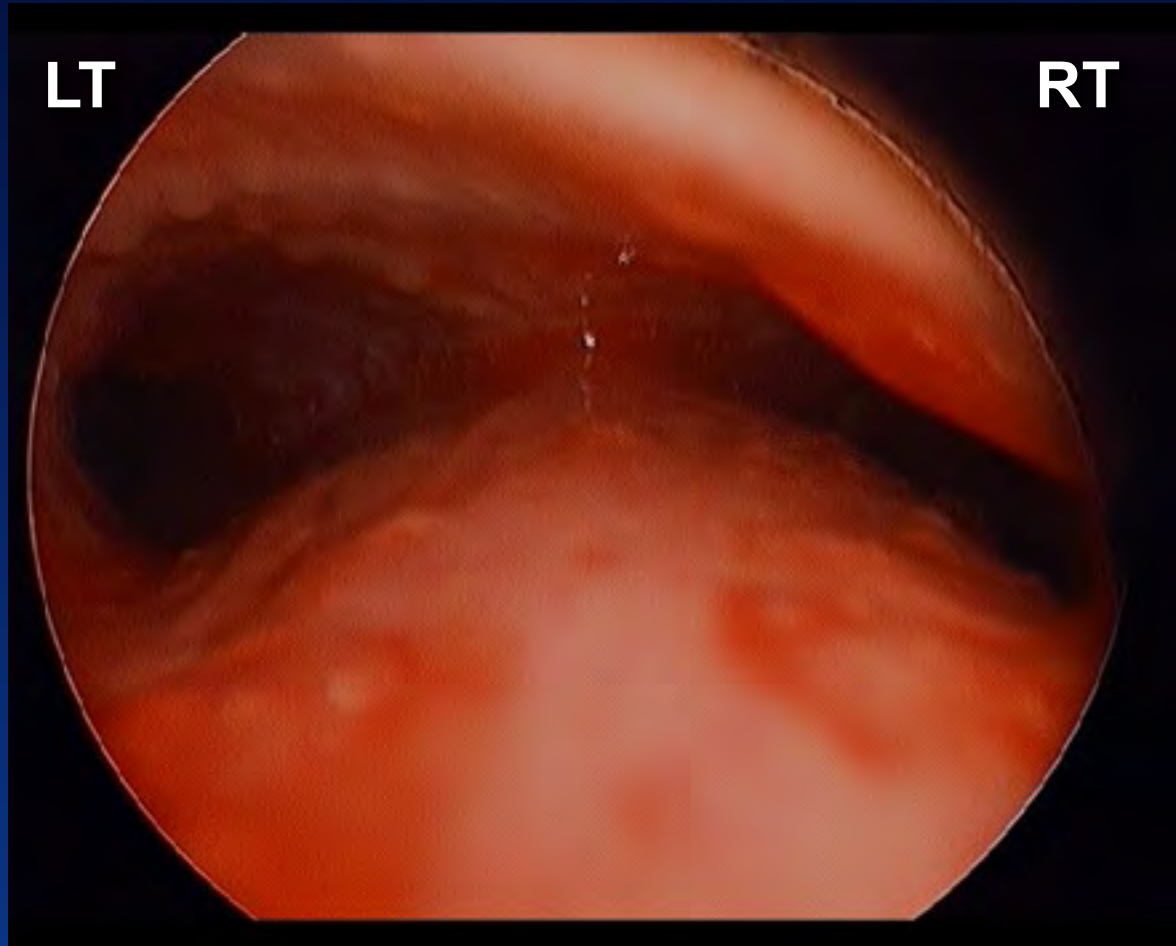
High (Cervical) Arch

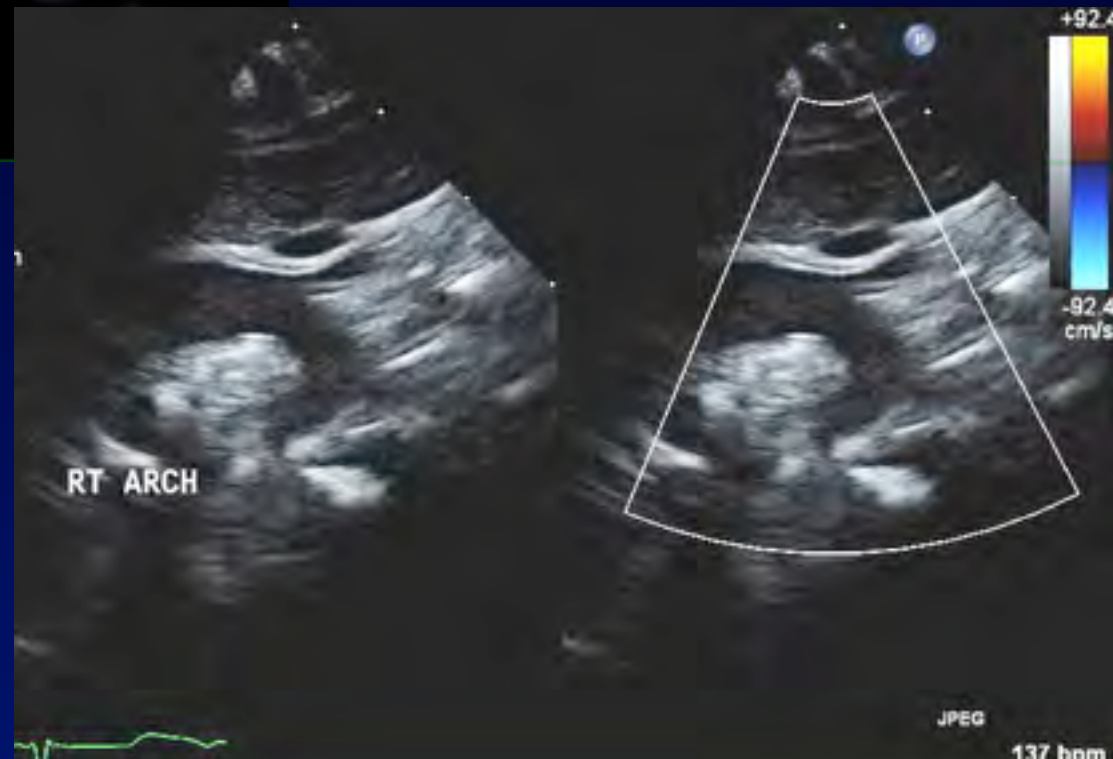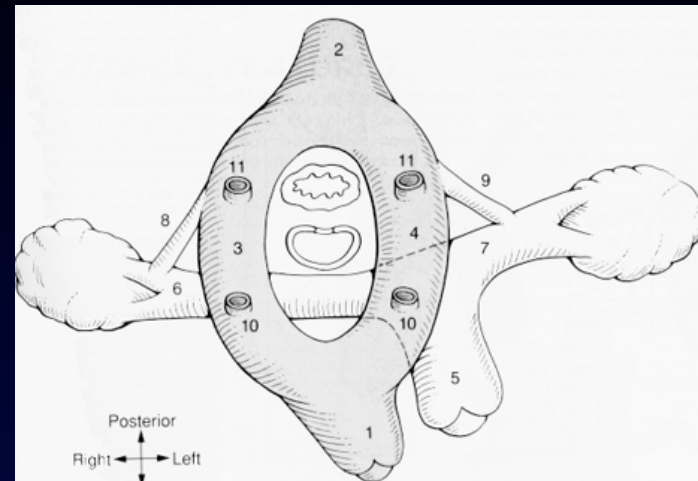
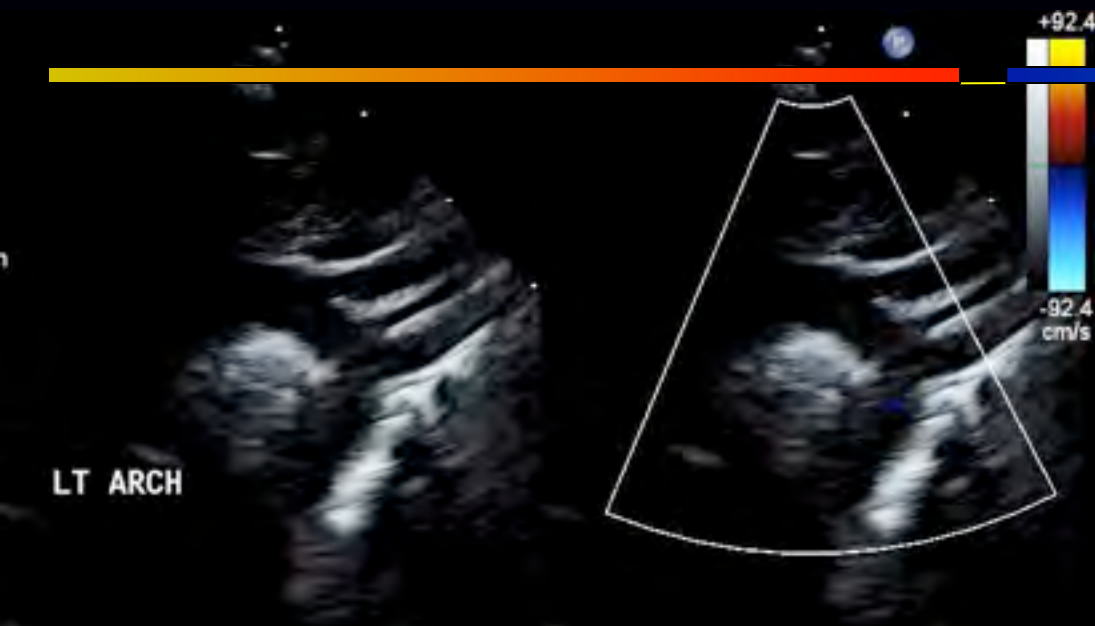




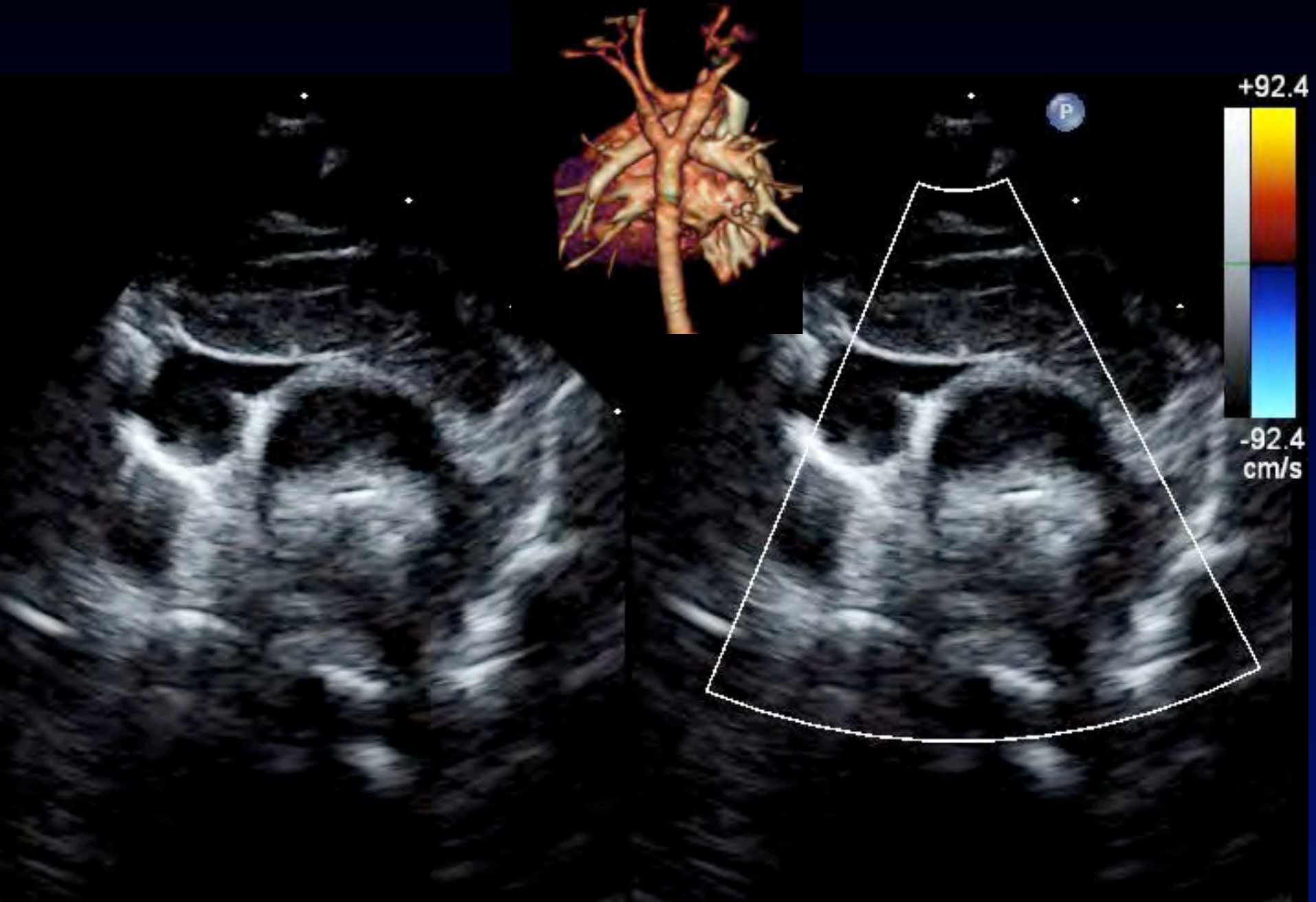
Bronchoscopy

RT Mainstem Bronchus Compression

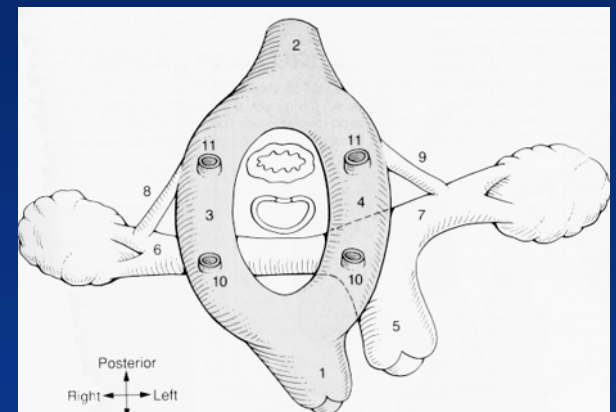
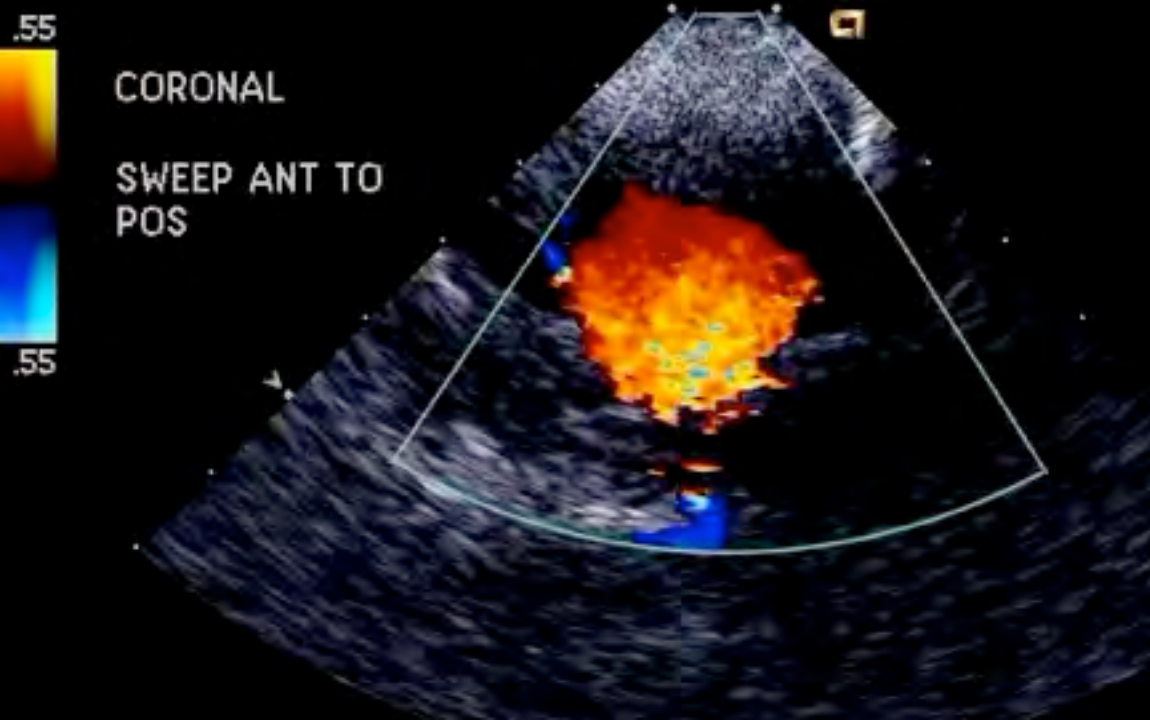
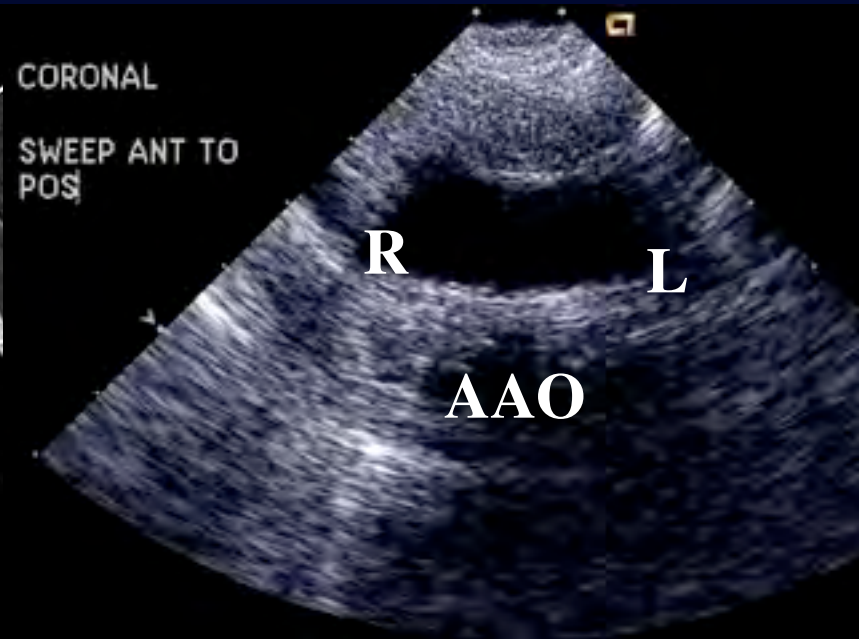
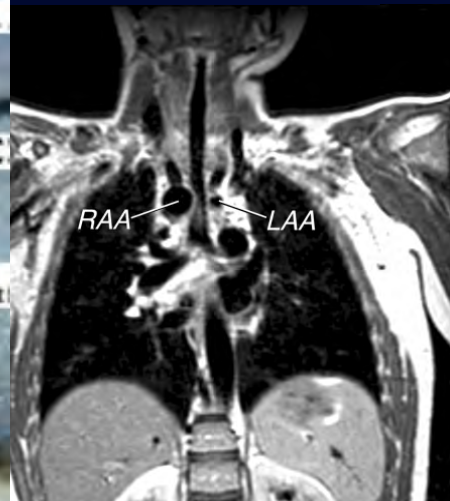
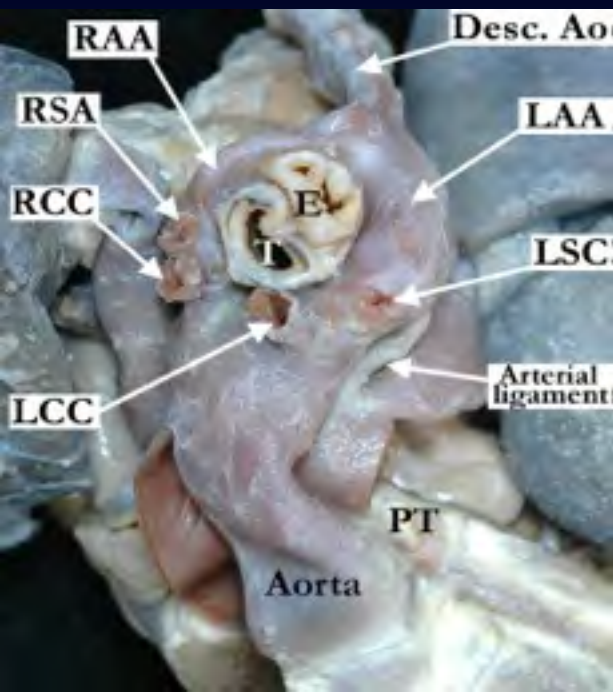


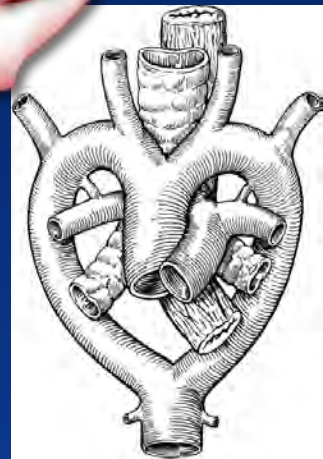
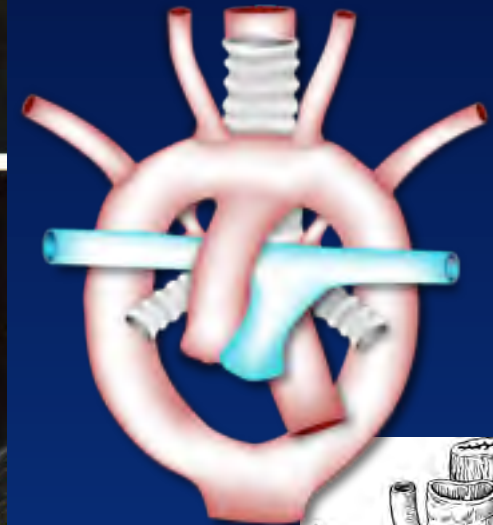
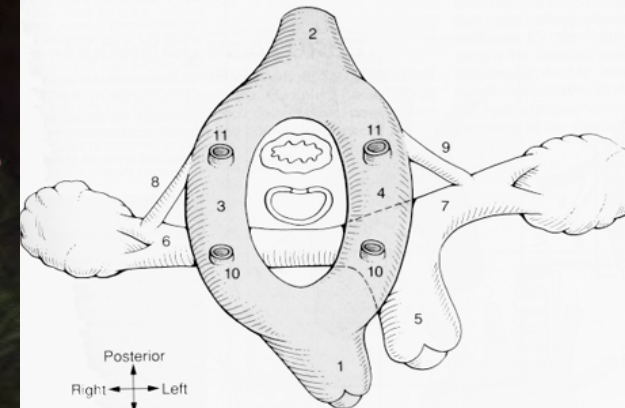
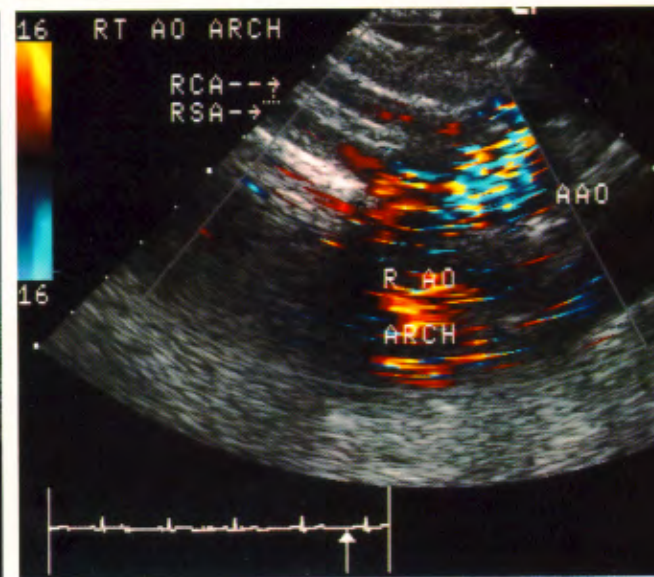
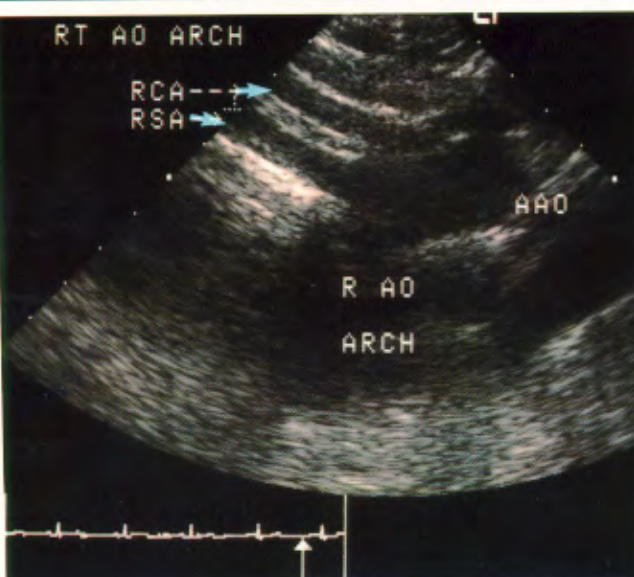
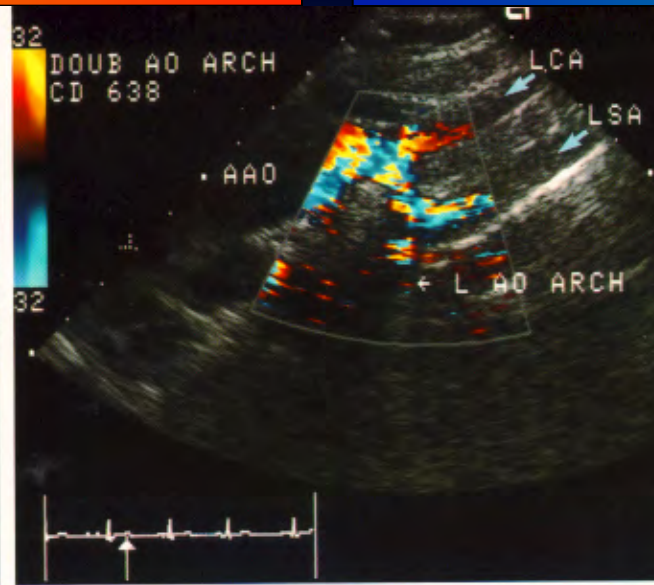
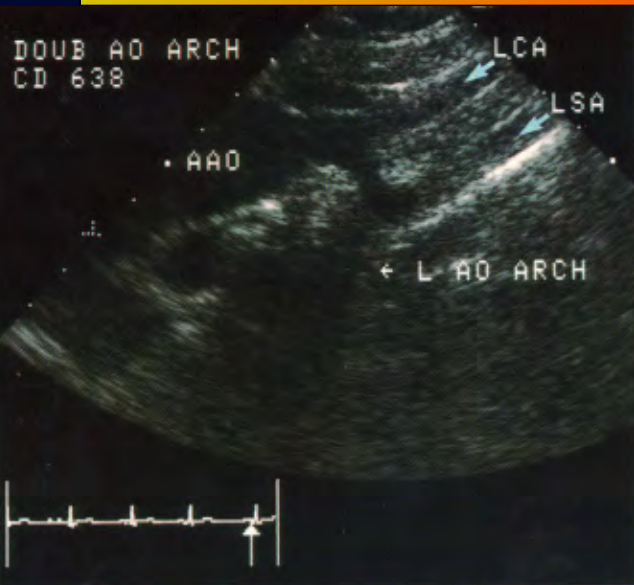
Coronal Scan



Double Aortic Arch




Double Aortic Arch

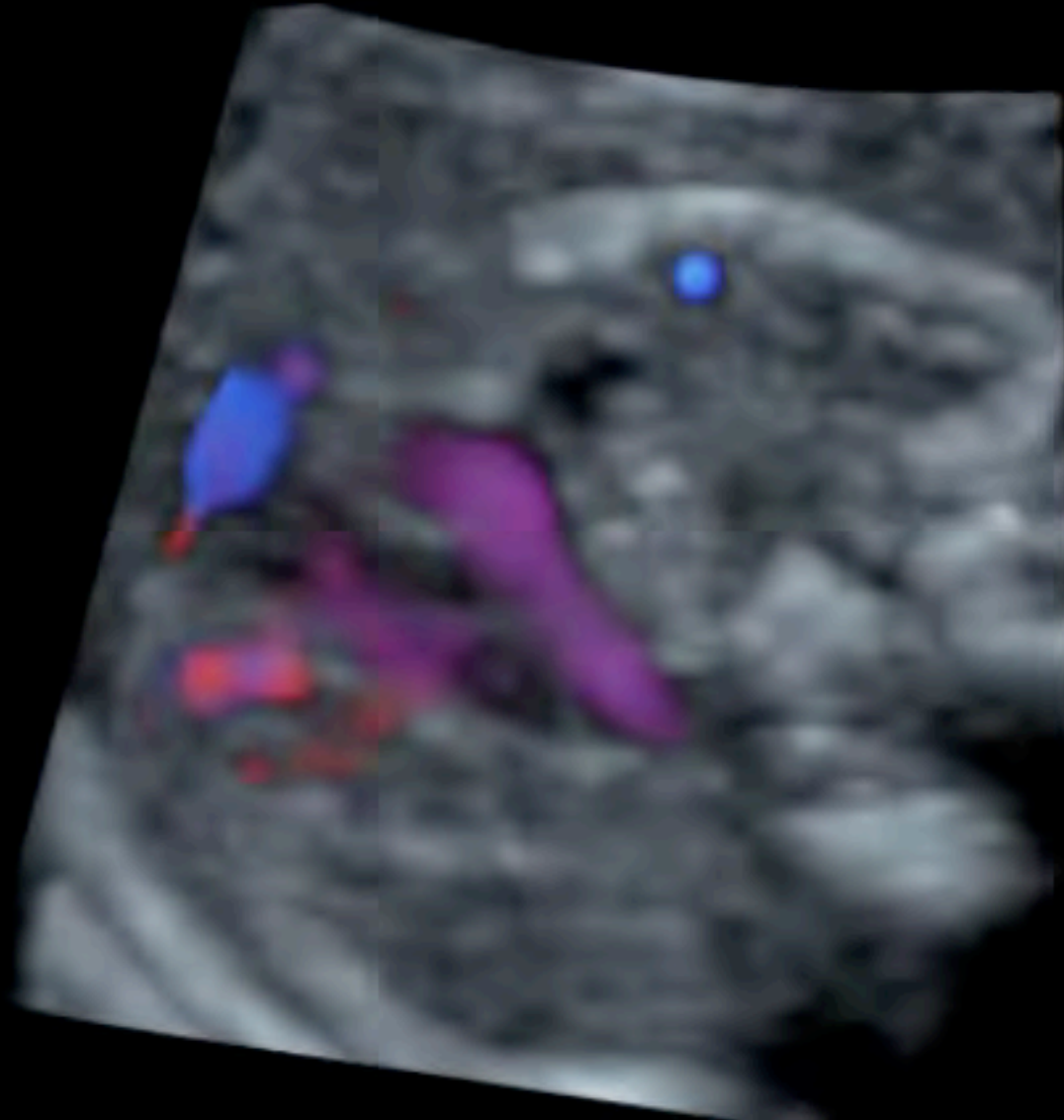


Fetal Double Aortic Arch

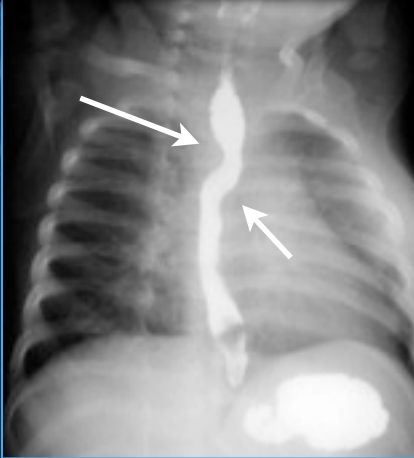
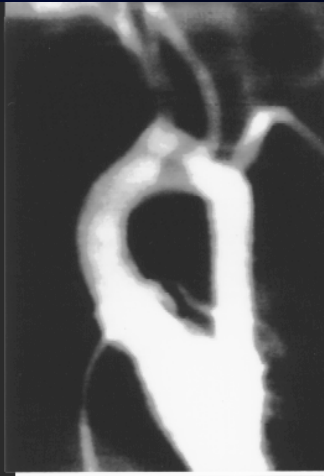COMP



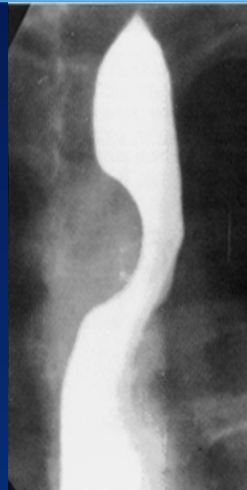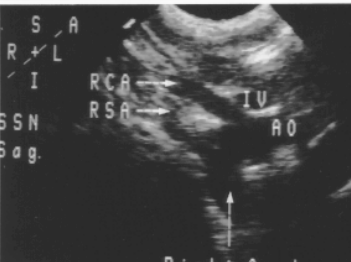
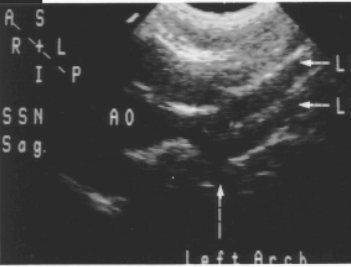
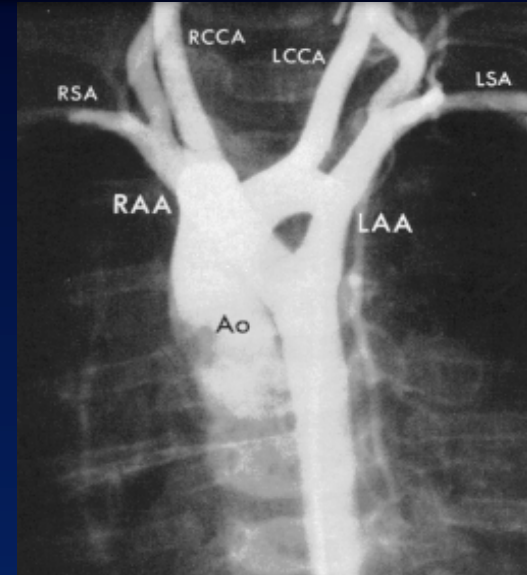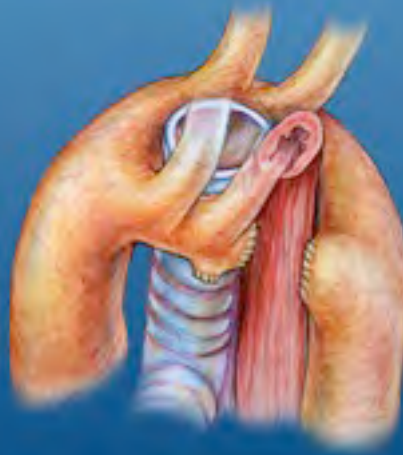B17"/V30"
24 Hz
2. Trim.
T12.5
Mix8/92
HR 152
CRI 3/VSRI 1
STIC HD-Flow™



Double Aortic Arch

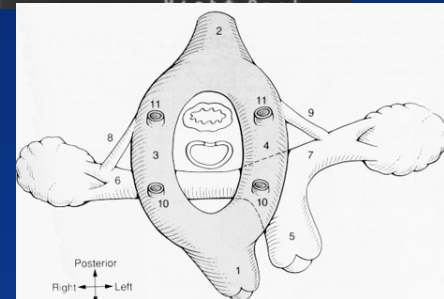
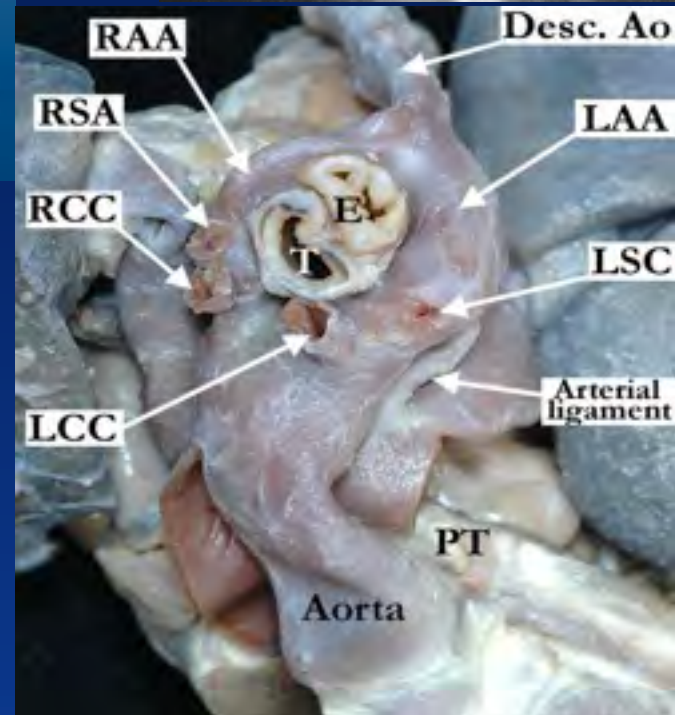
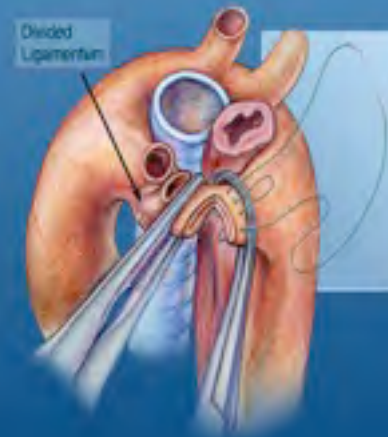
Left Arch Divided

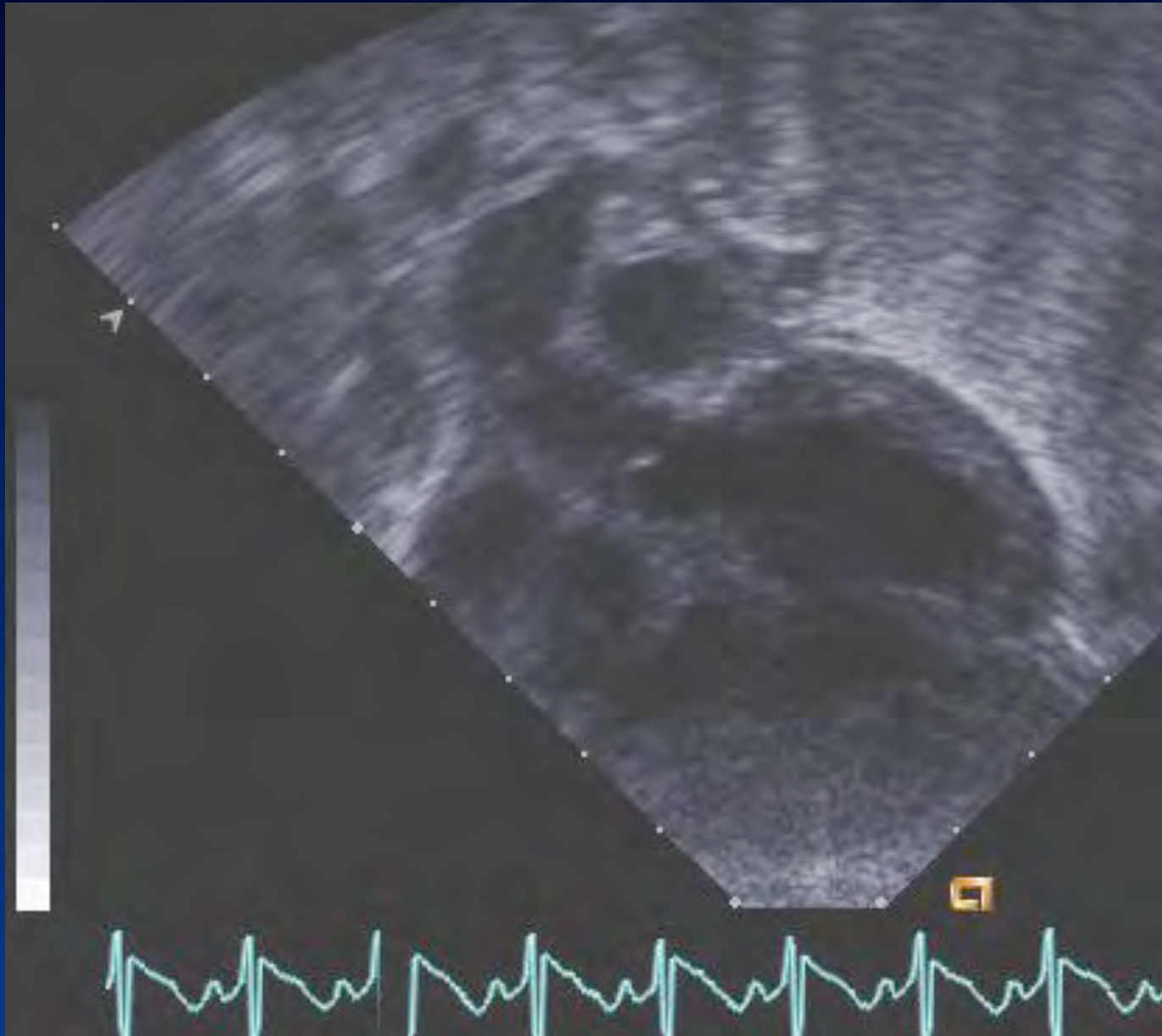


Ligamentum Divided
Left Arch Partially Divided

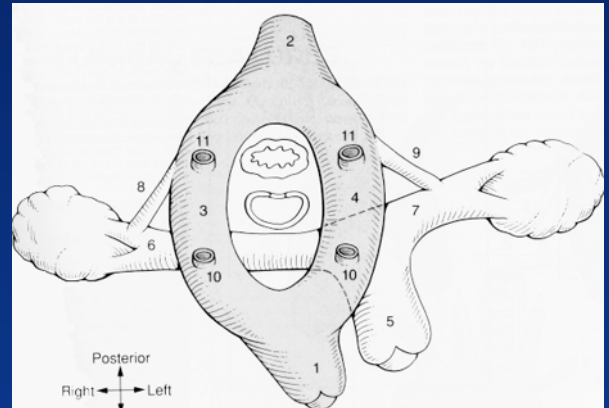
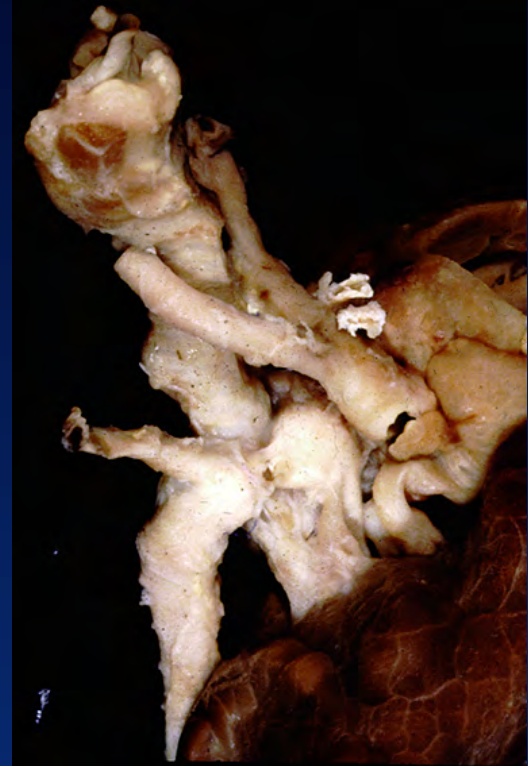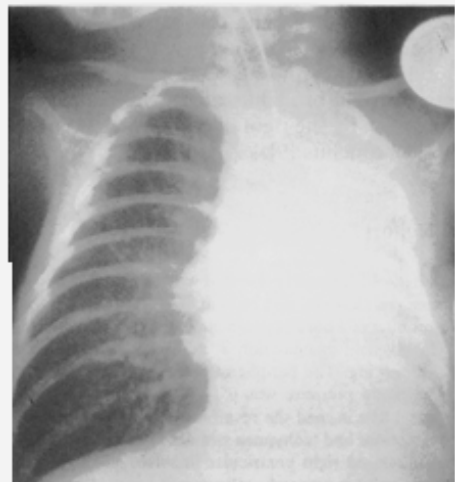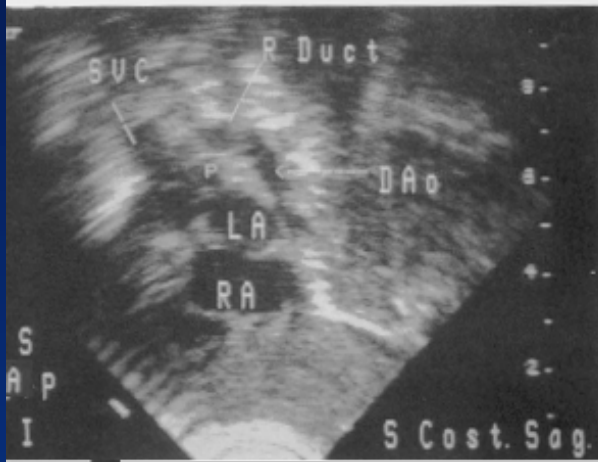
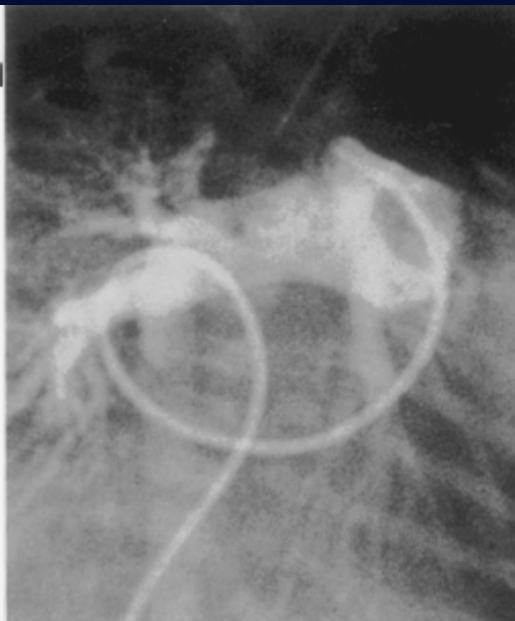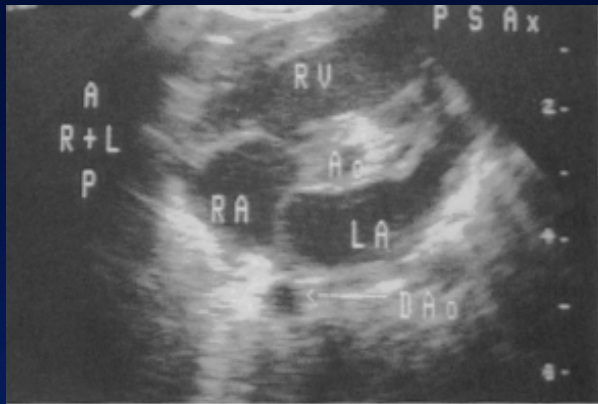
Divided Ligamentum



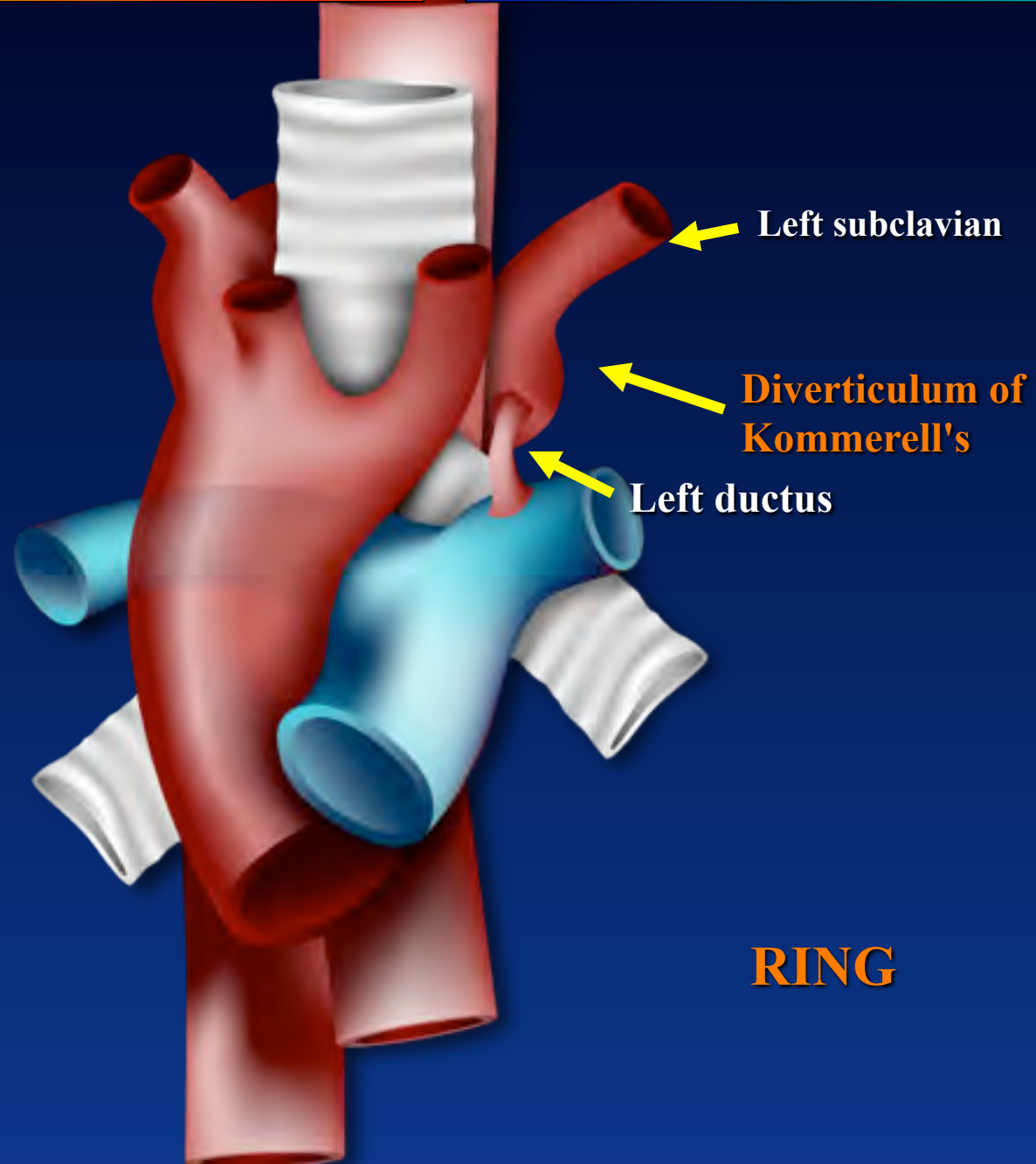
L Duct, Right Ao Arch



Interrupted Aortic Arch, R Desc. Ao & R Duct- Another Bronchial Vise



Right Arch with Aberrant Left Subclavian



Right Arch Mirror-image Branching and No Ring

Right Arch



Mirror Image Branching

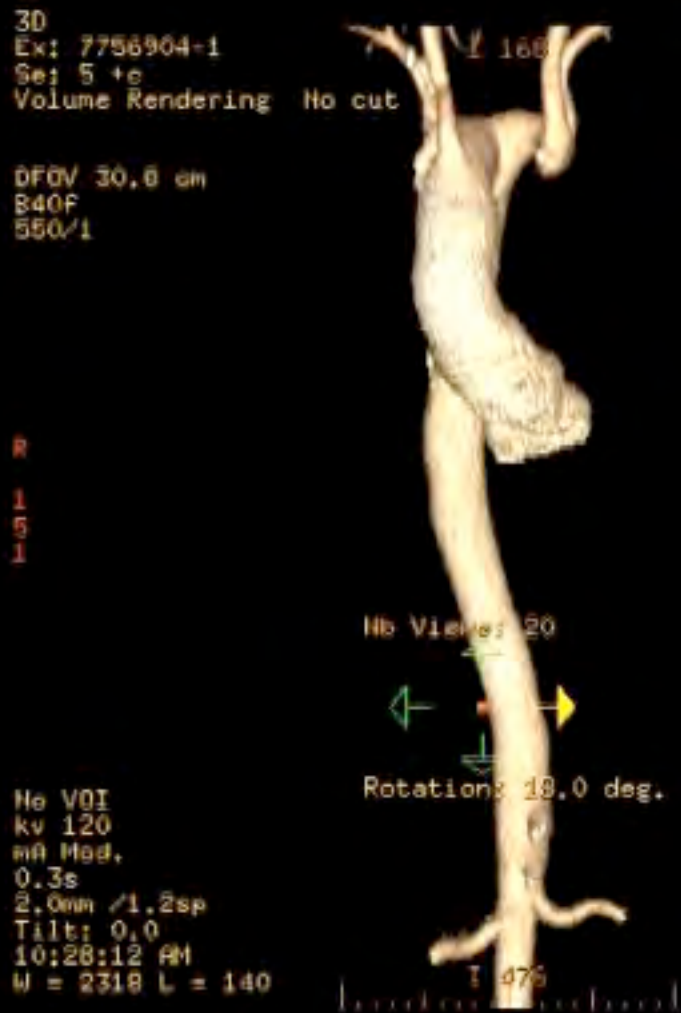

Left ductus From innominate

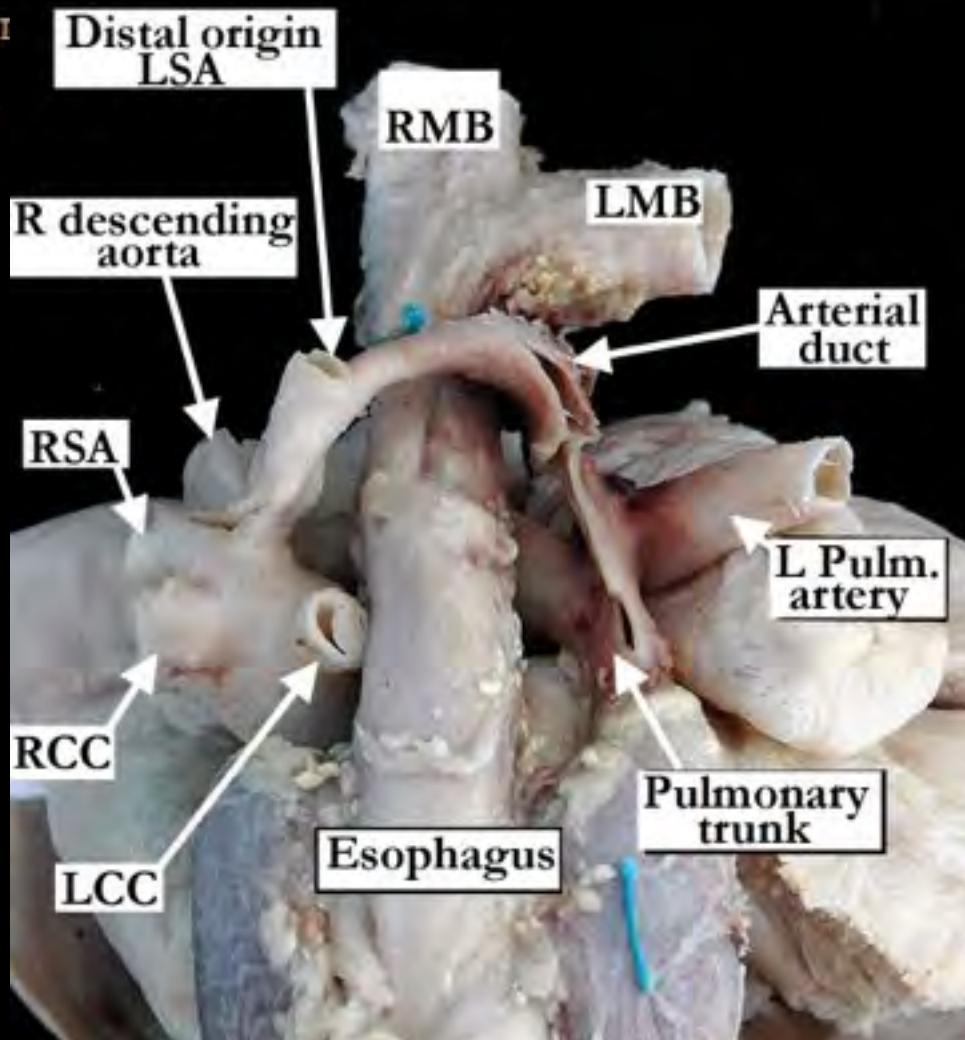


NO RING

Right Aortic Arch – Aberrant L subclavian artery and L arterial duct

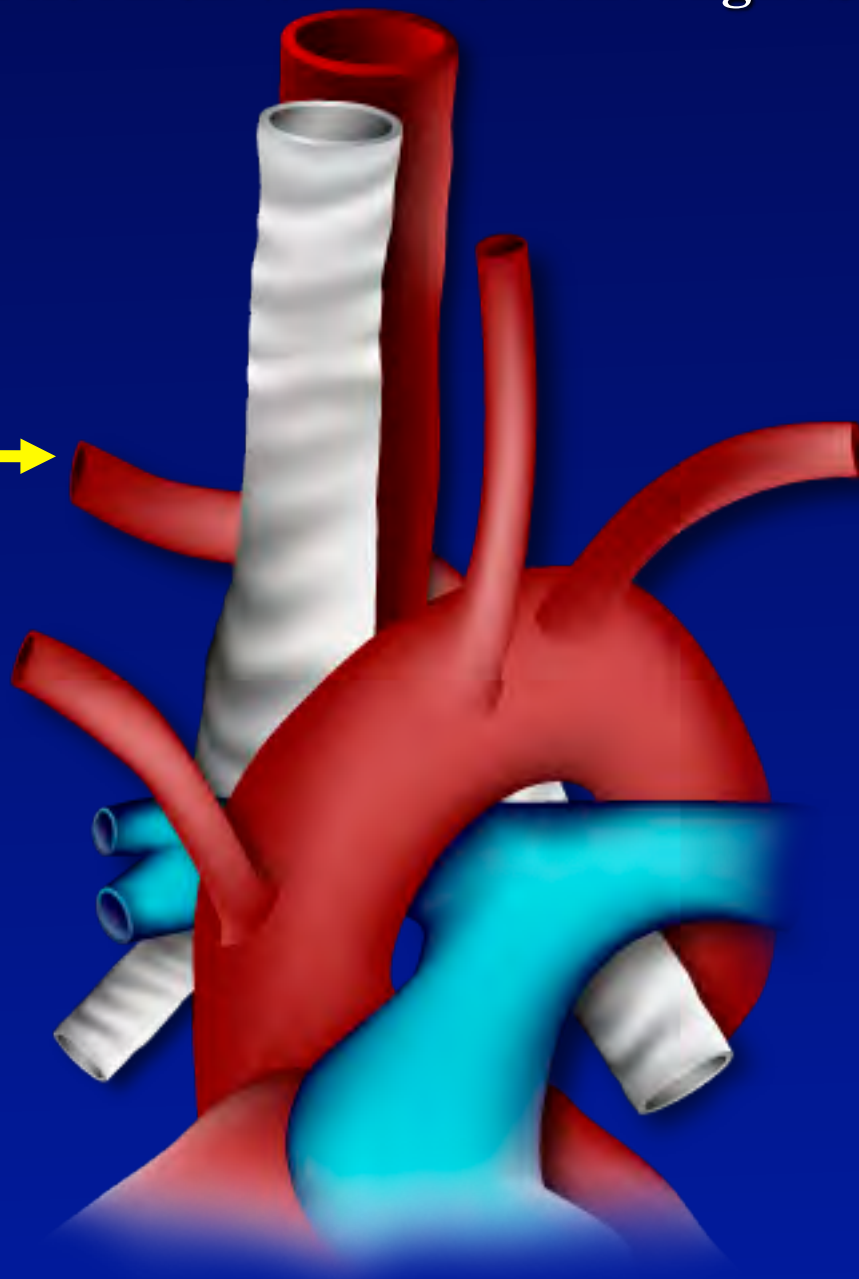


MAYO CLINI
Har

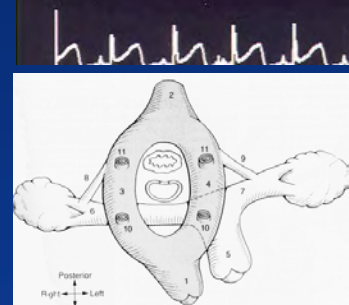
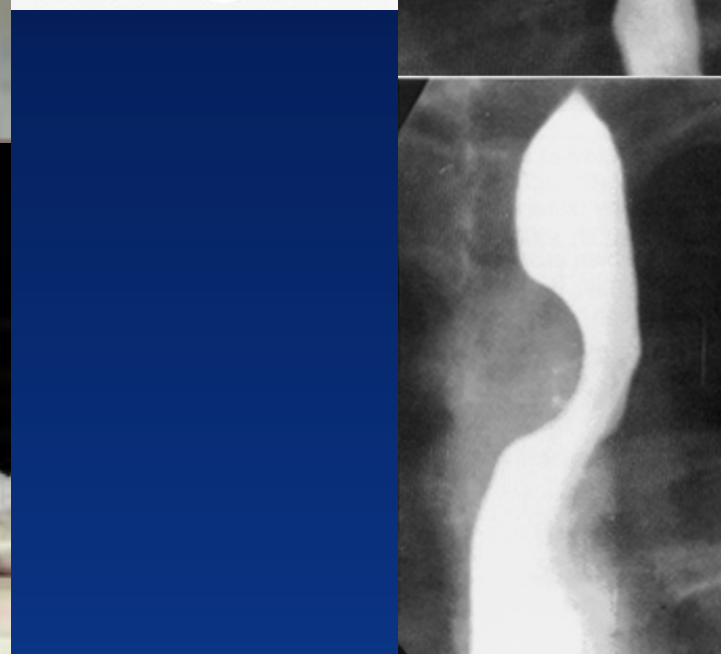
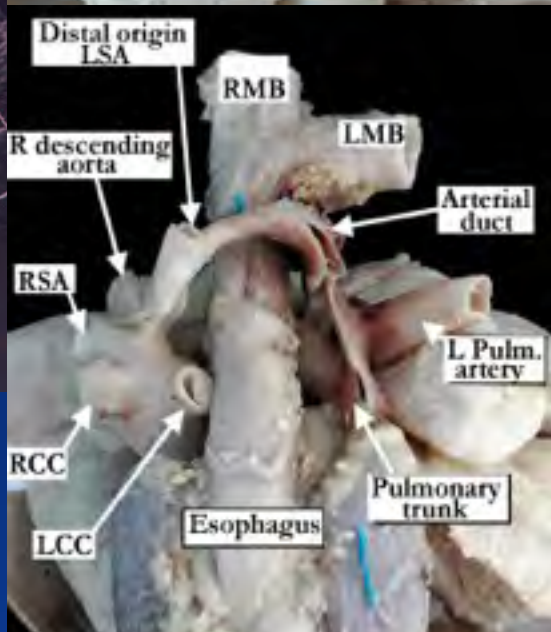
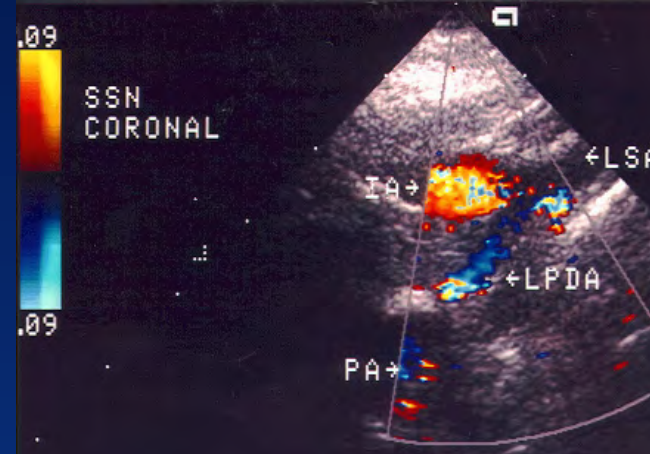
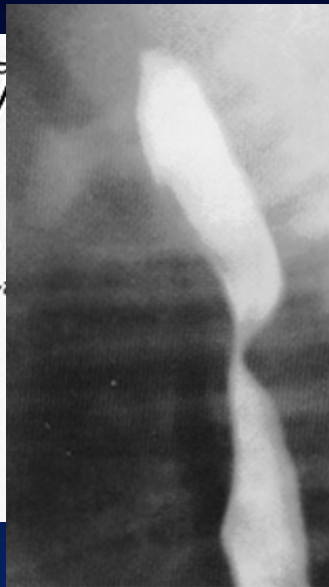
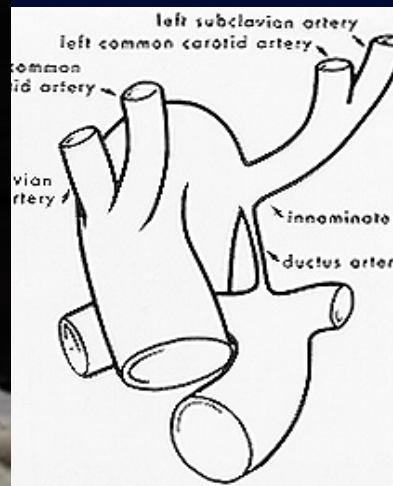
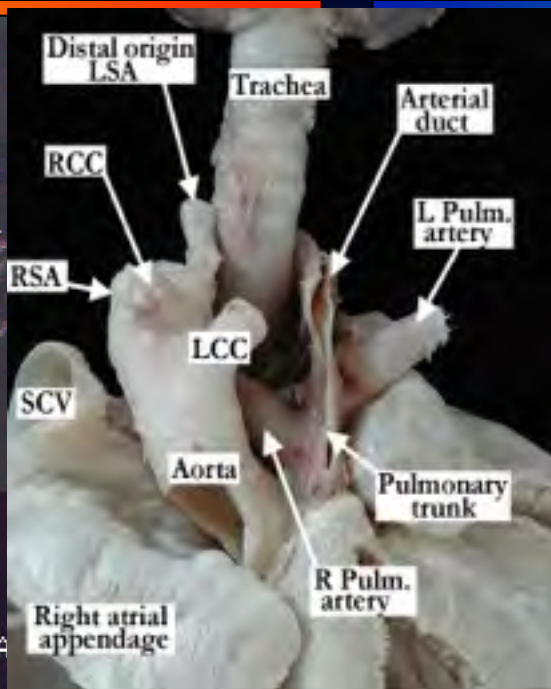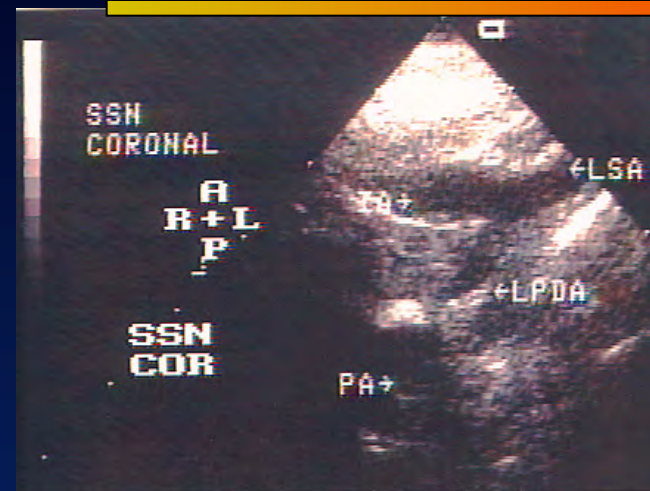


Left Aortic Arch with Aberrant Right Subclavian

Aberrant
RT SCA

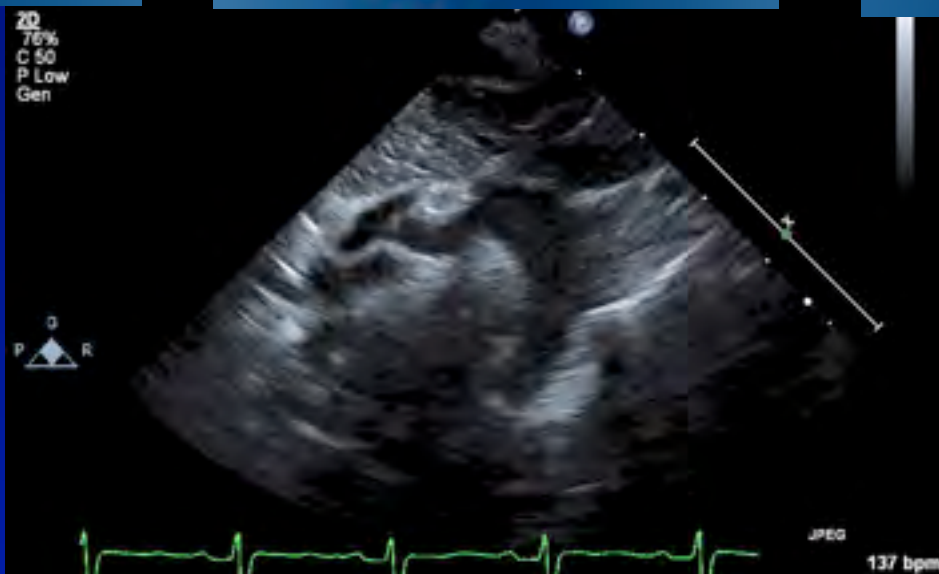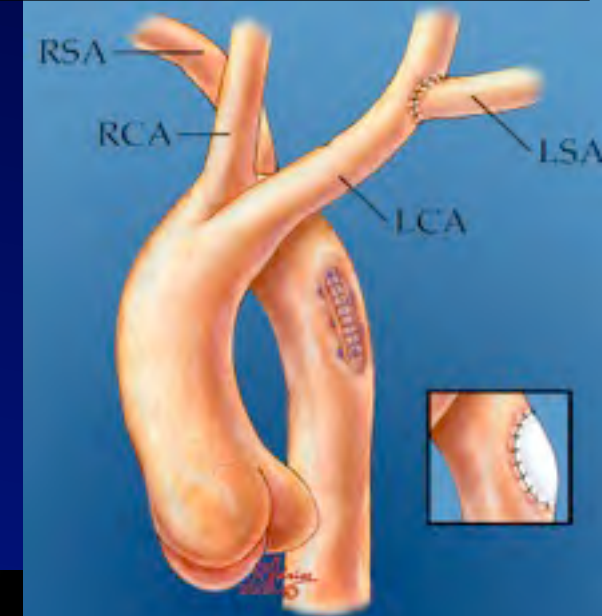
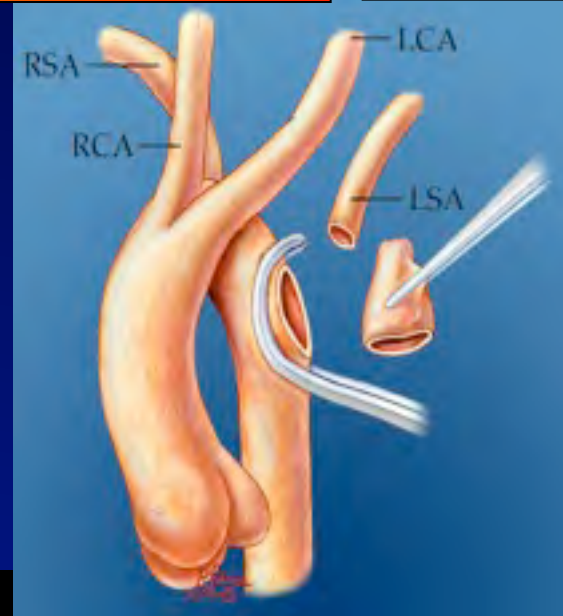

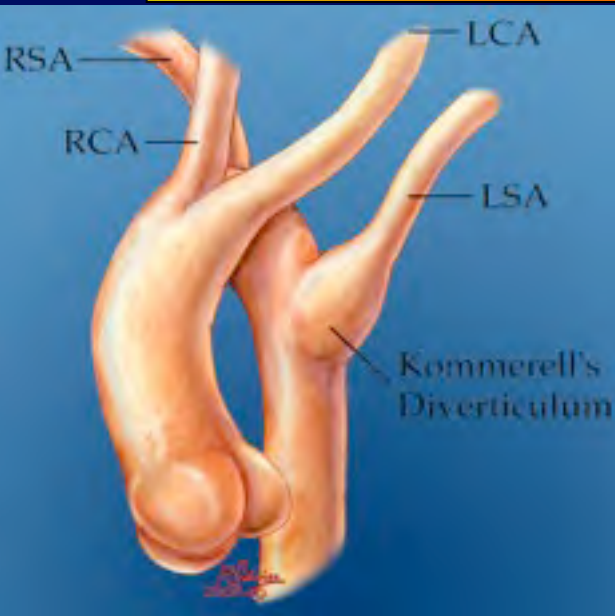
Left Duct with Right Aortic Arch

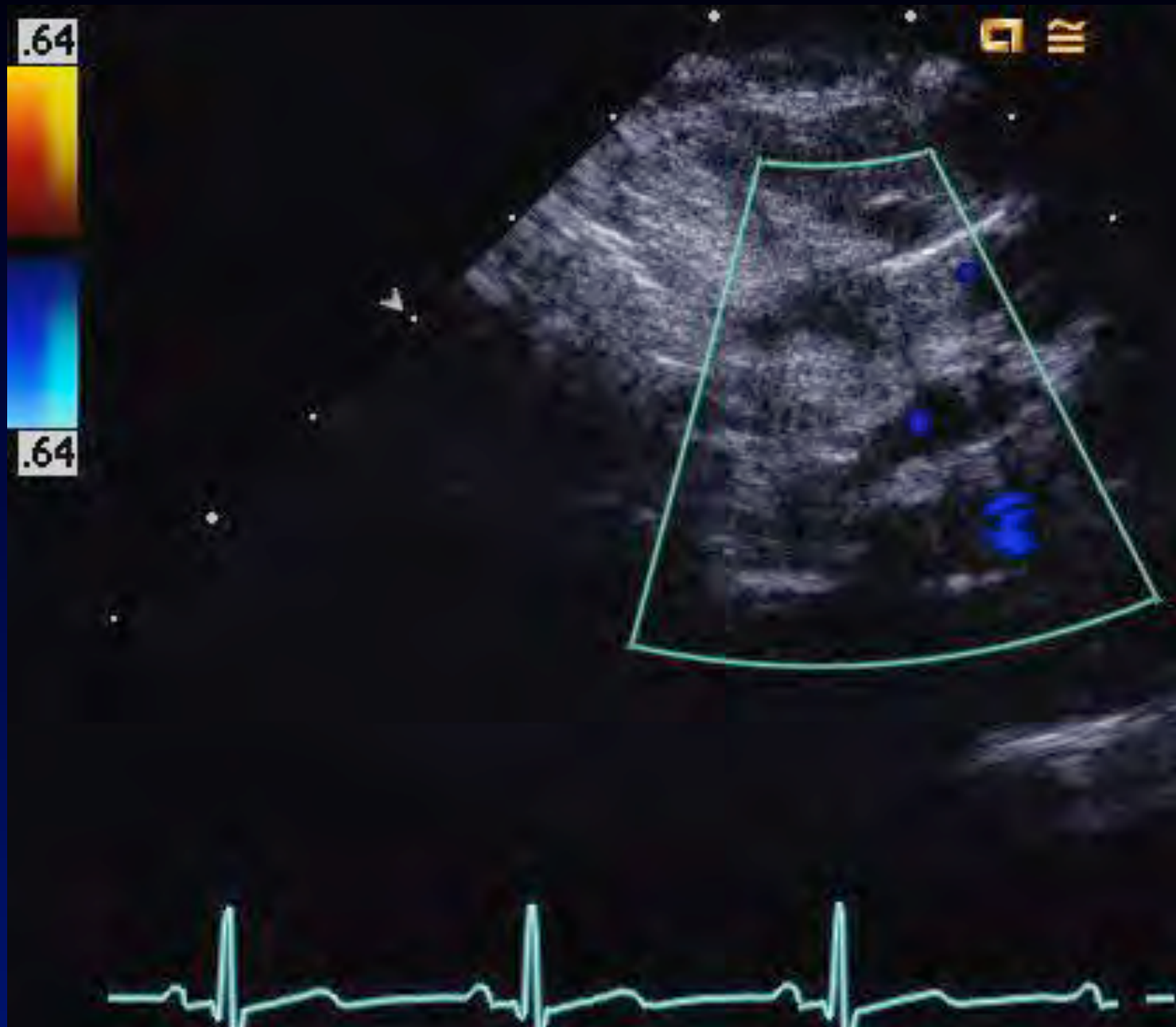

Resection of Kommerell's diverticulum and left subclavian artery transfer for recurrent symptoms after vascular ring division

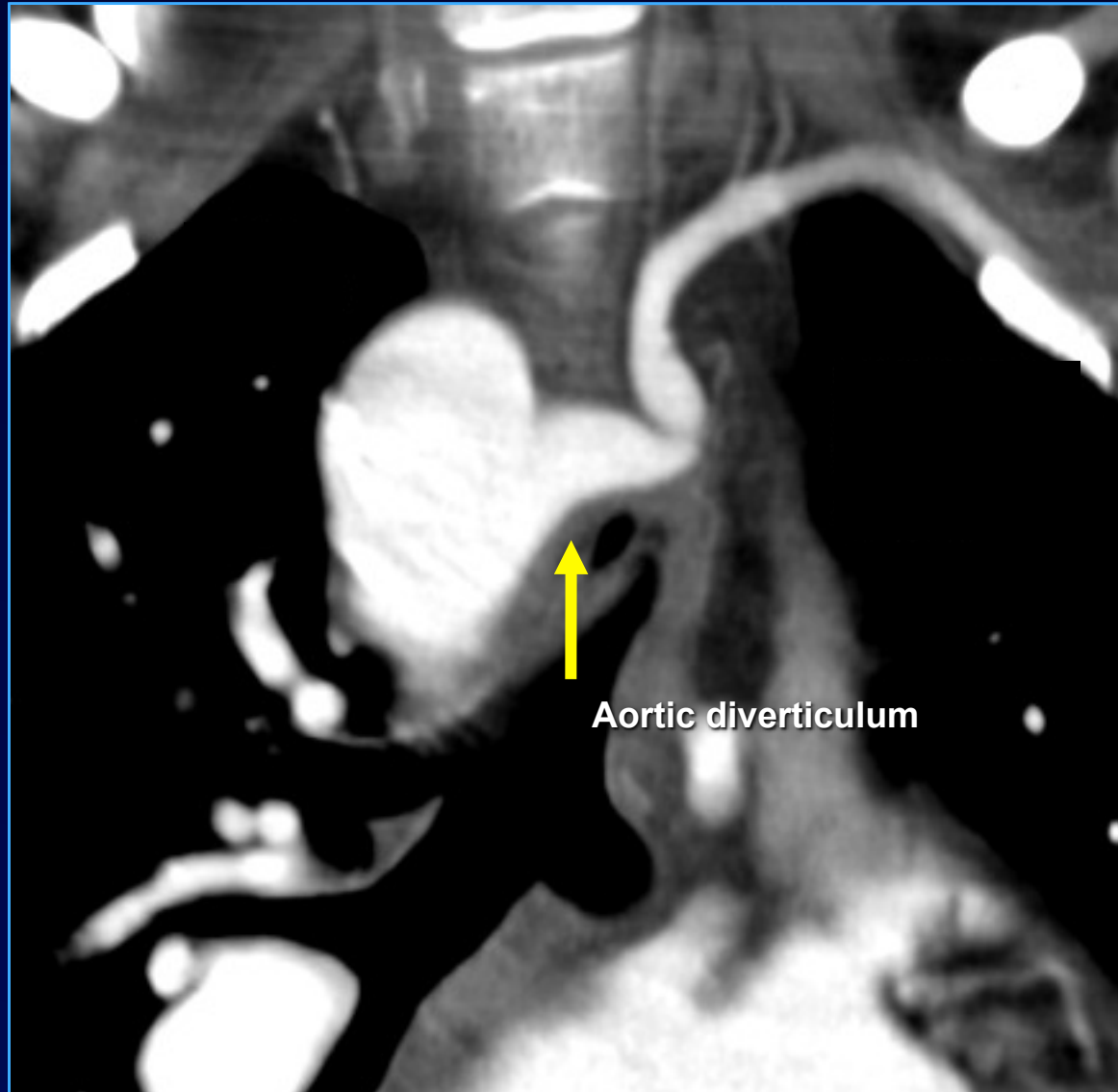
C.L. Backer, N. Hillman, C. Mavroudis, L.D. Holinger *EJCTS* 2002



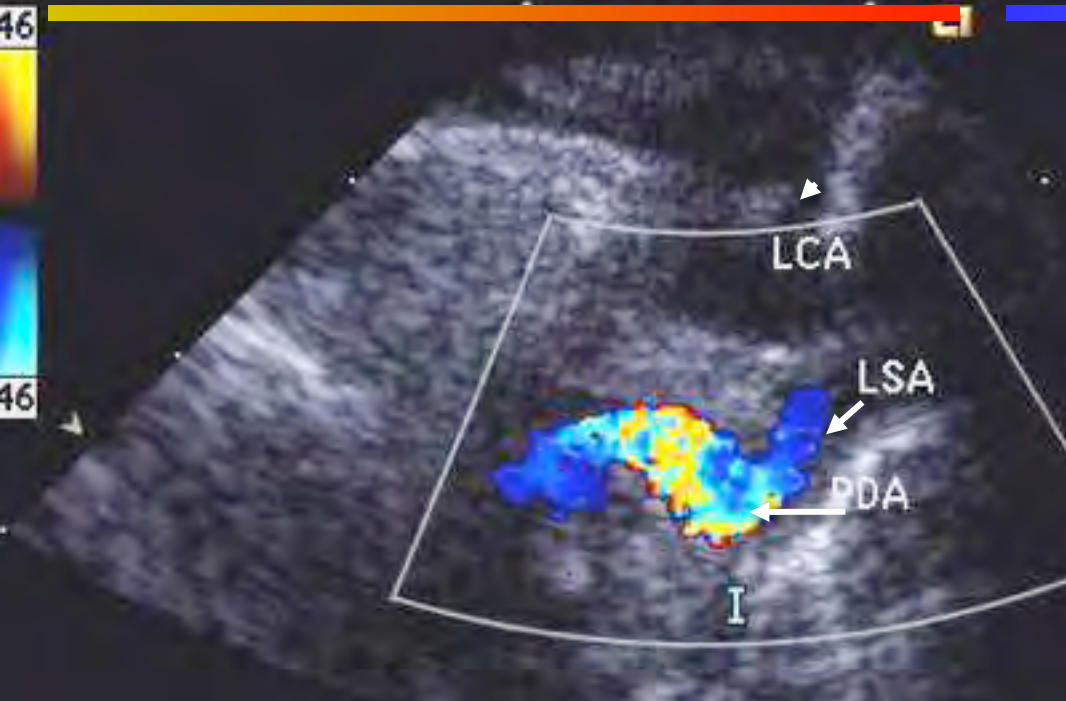
Kommerell's Diverticulum



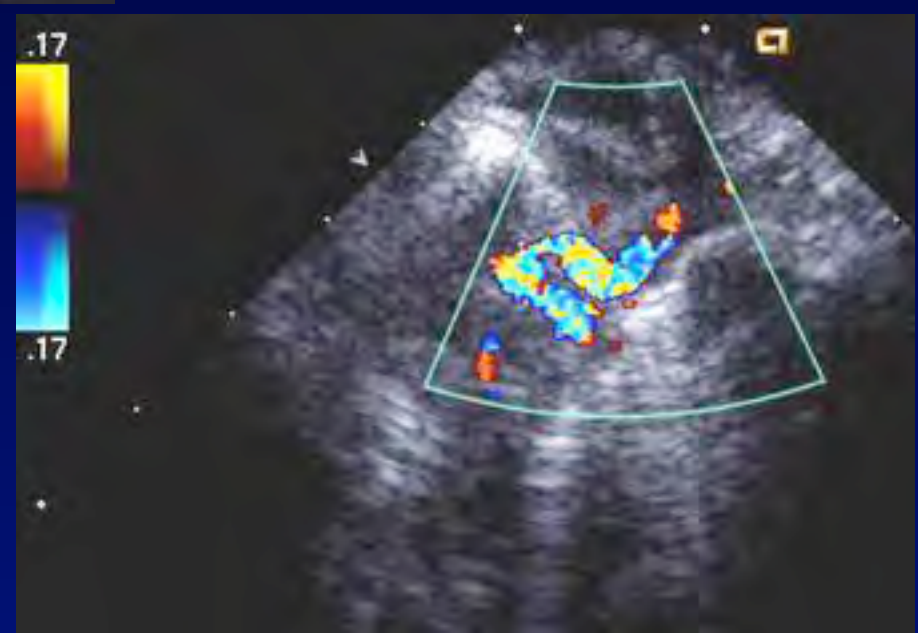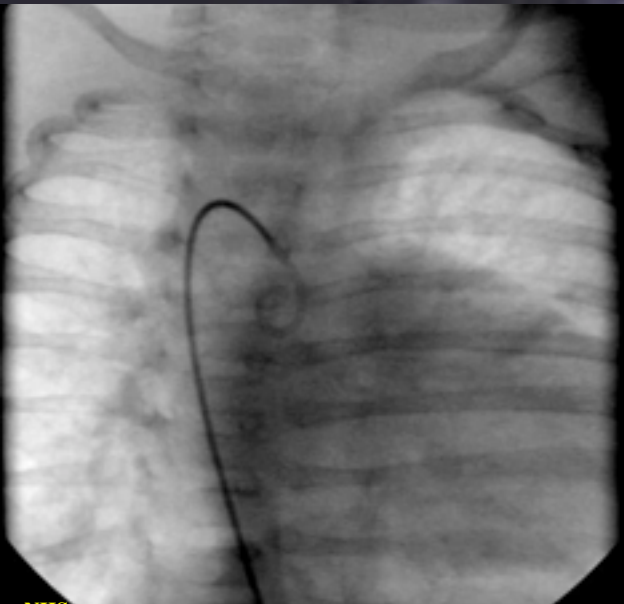
Kommerell's Diverticulum



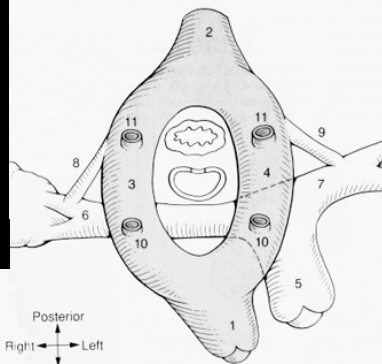
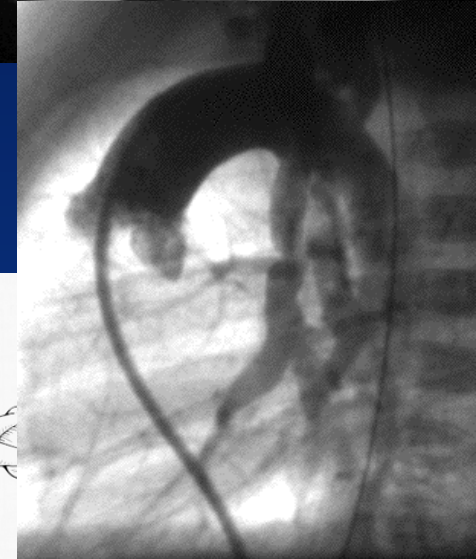
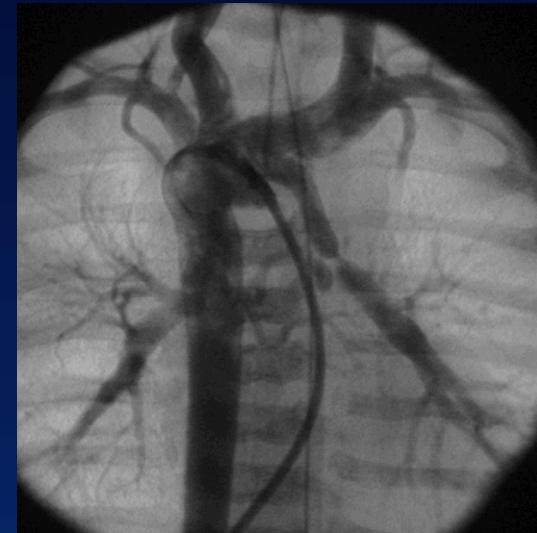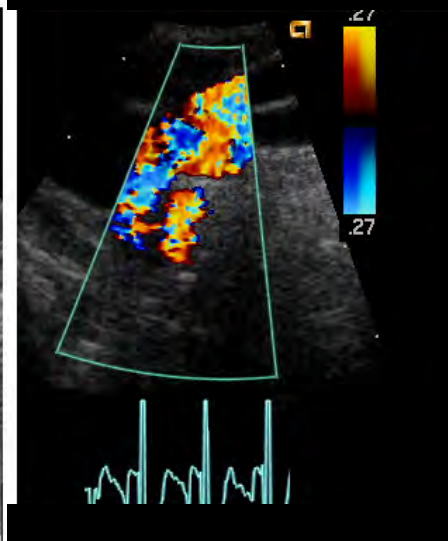
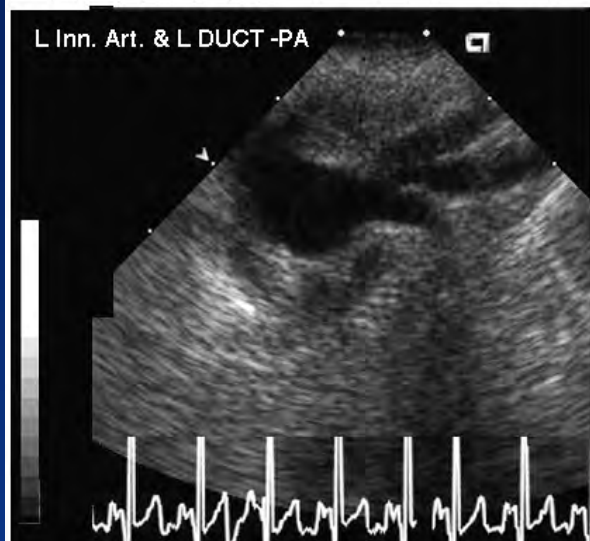
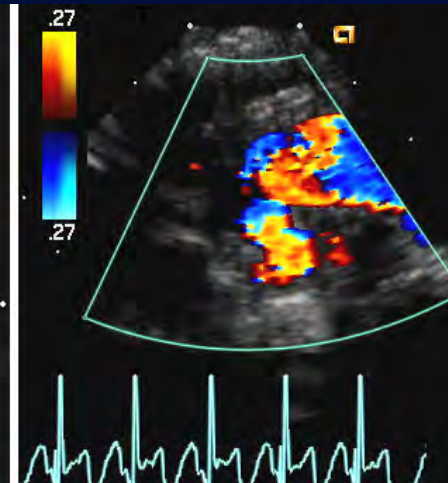
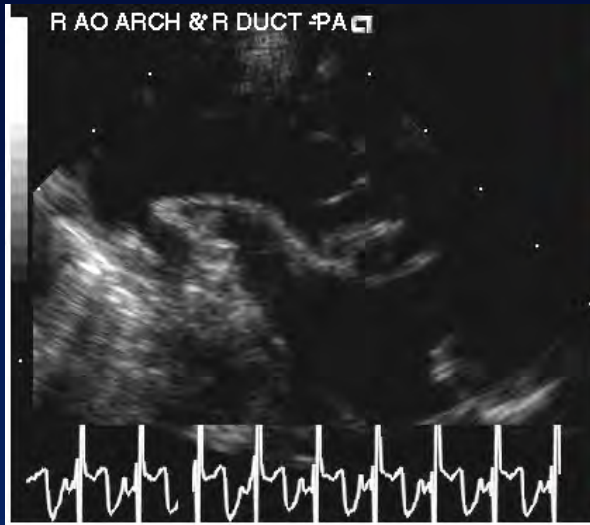
Left Ductus: Right Arch



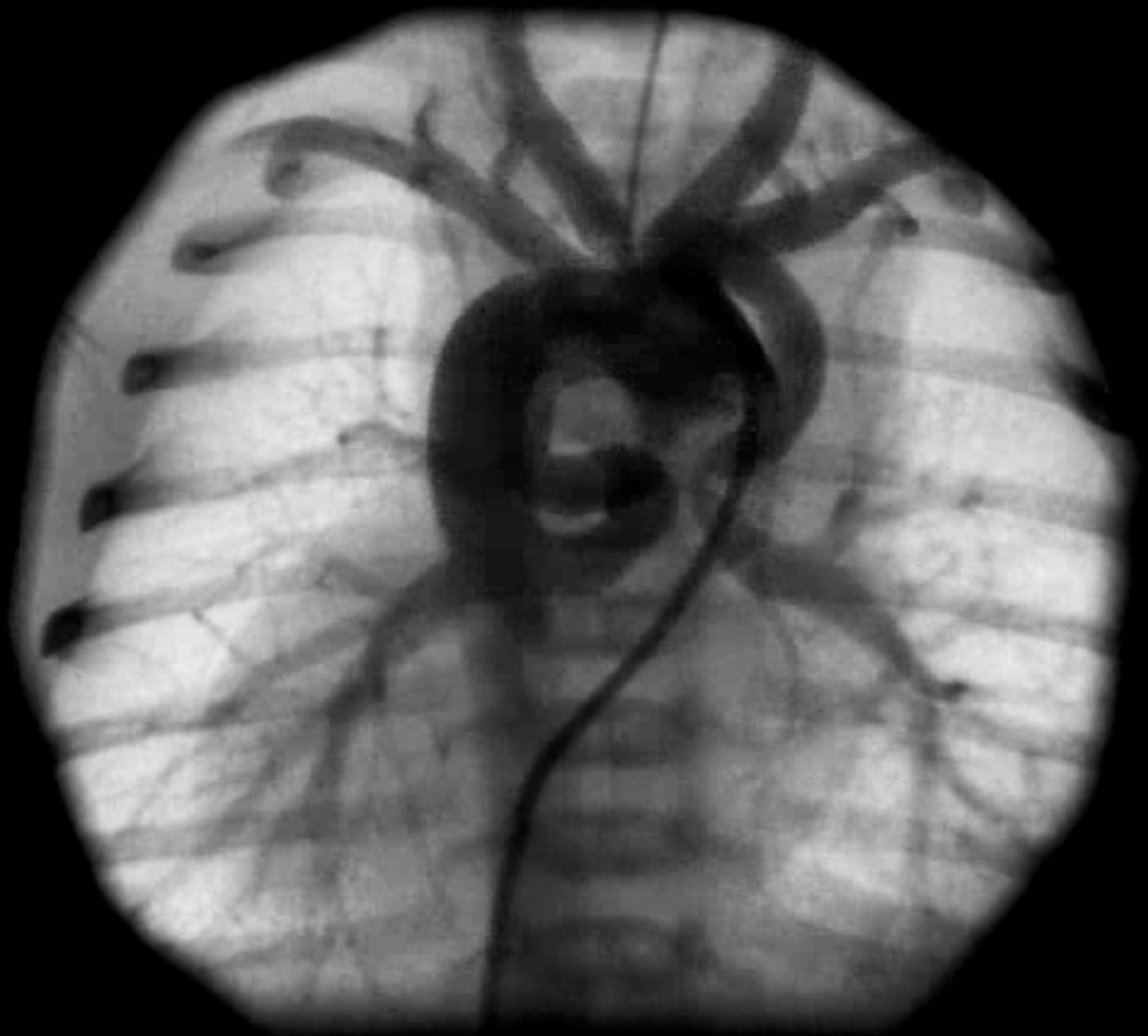
Potentially
Isolated
L subclav.
Art



BILATERAL DUCTS WITH ABSENT CENTRAL PA'S

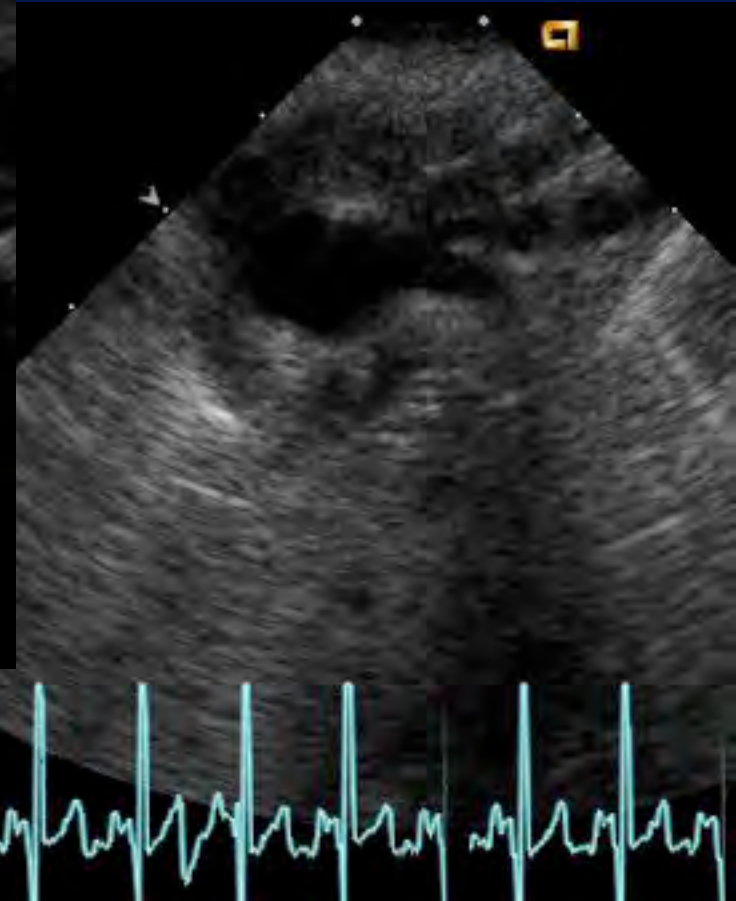


Bilateral Ductus

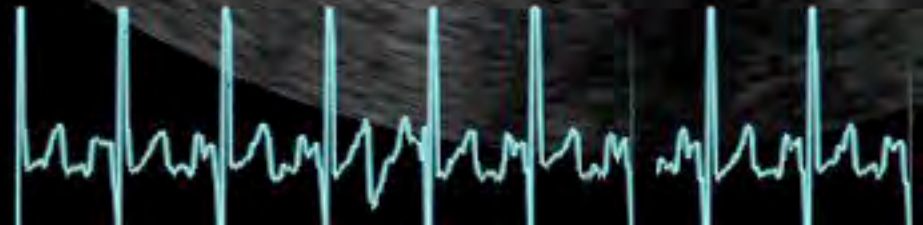


Bilateral Ducts & Absent Central PA's

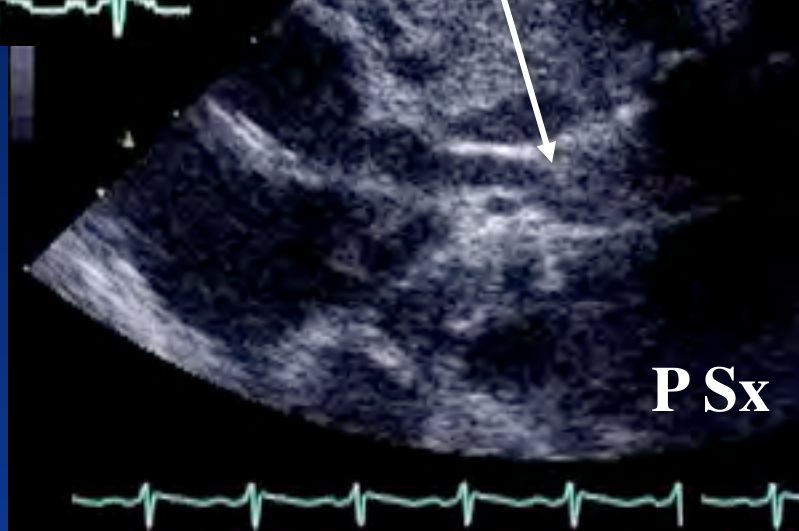
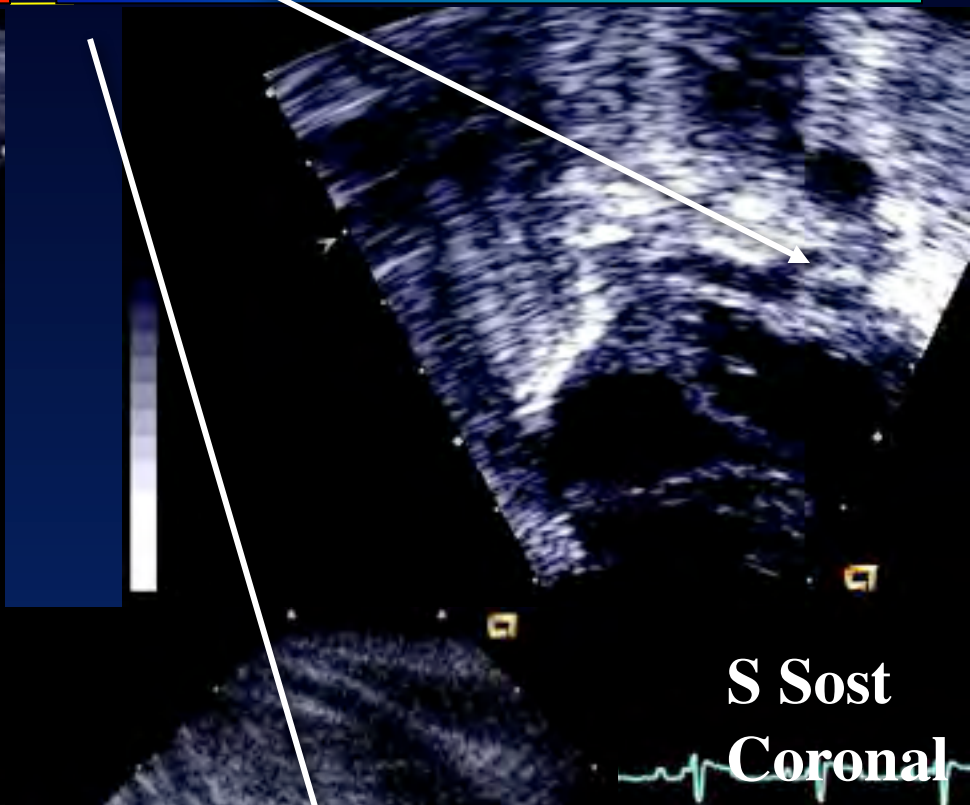
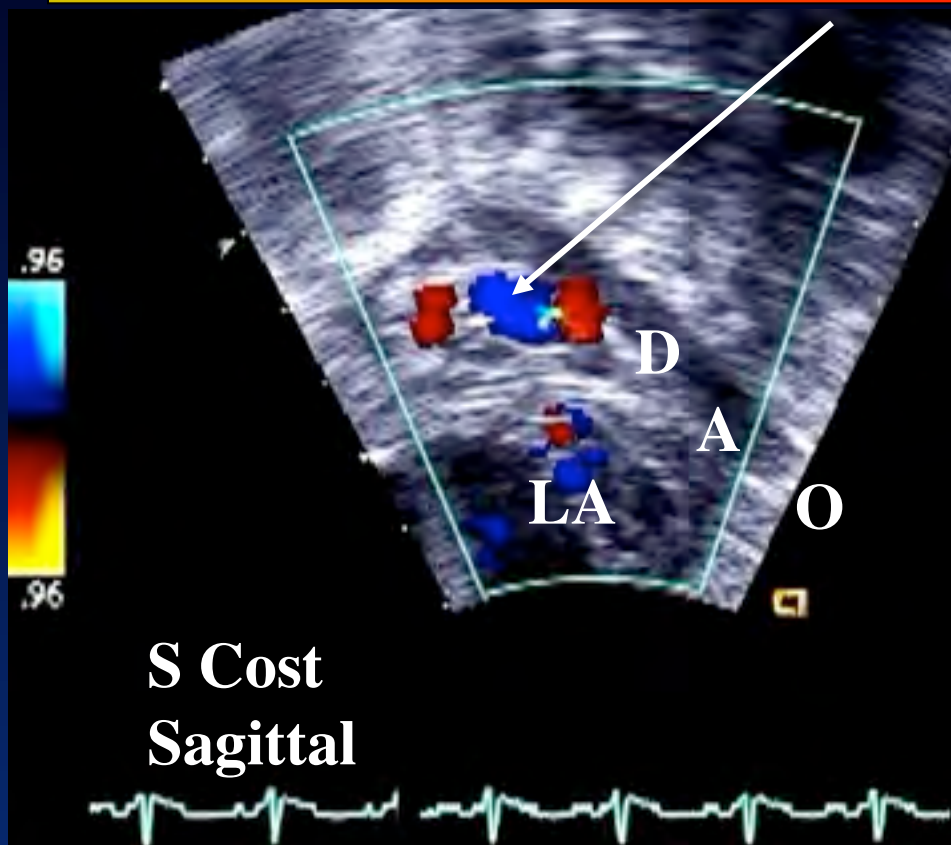
**Left Innominate
and Duct**



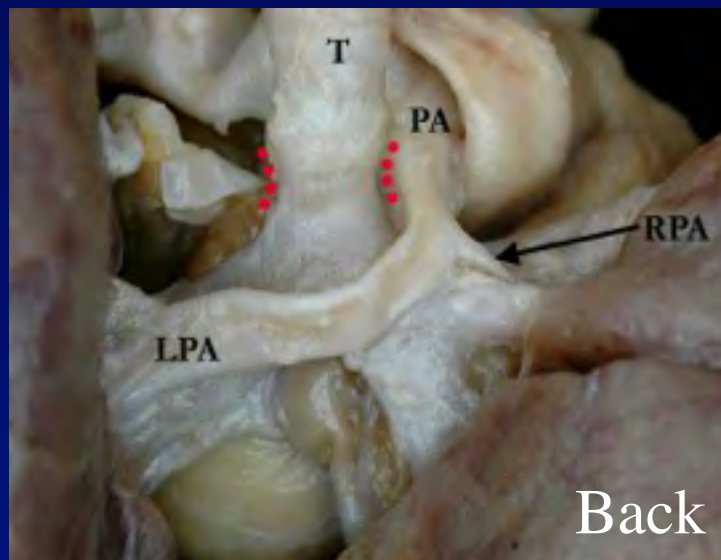
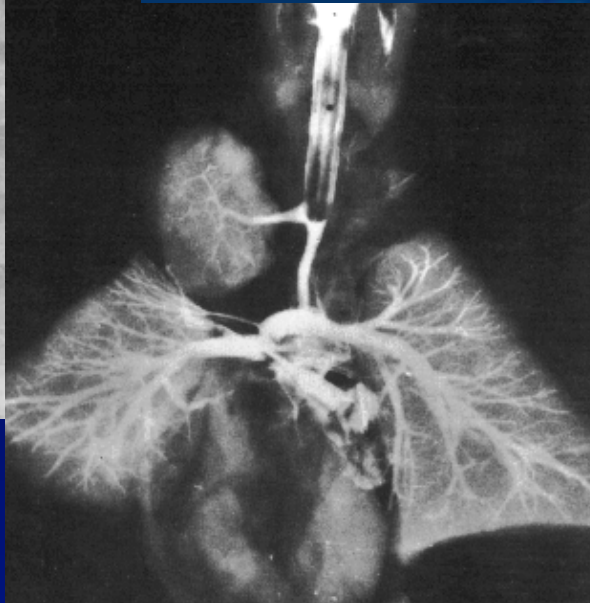
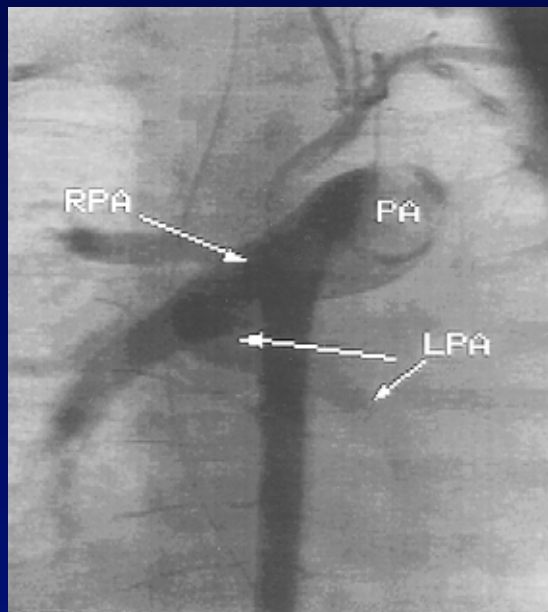
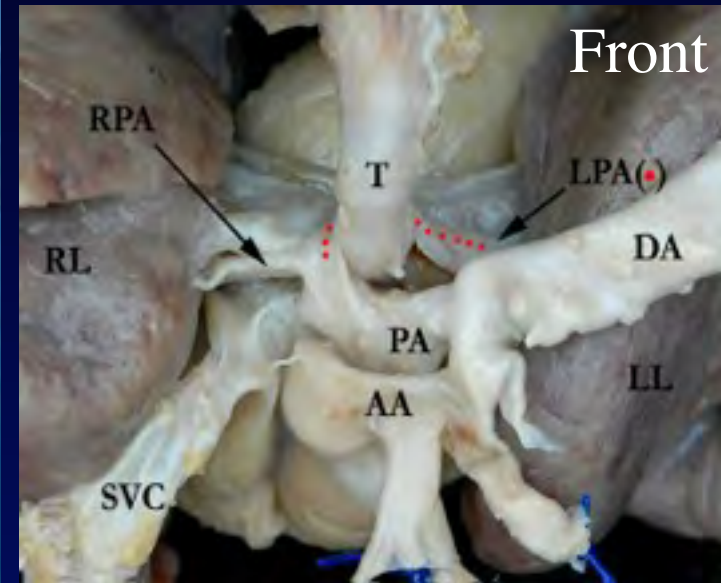
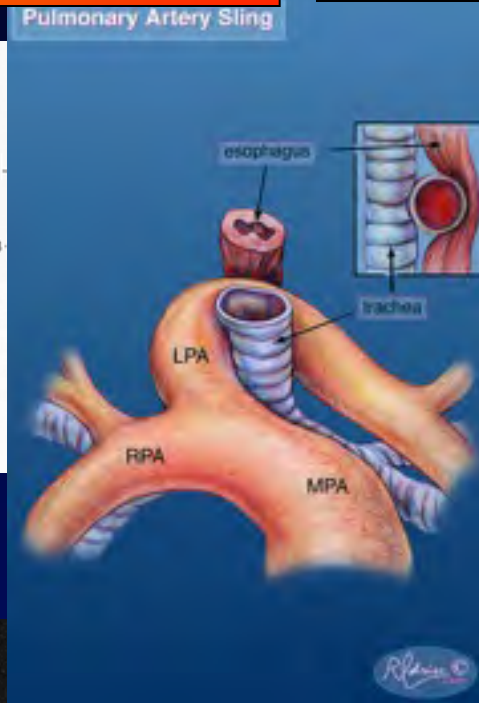
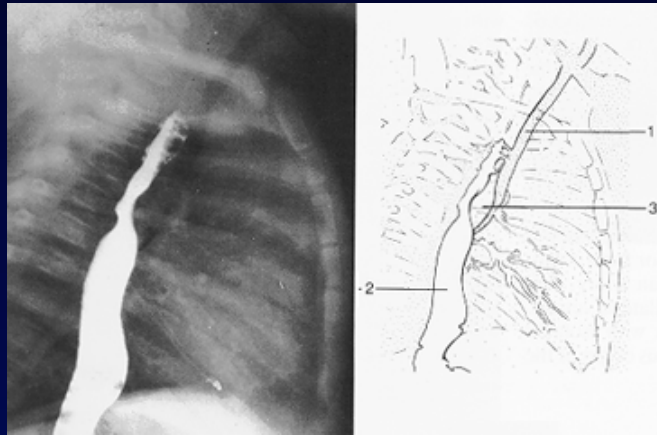
Right Arch and Duct



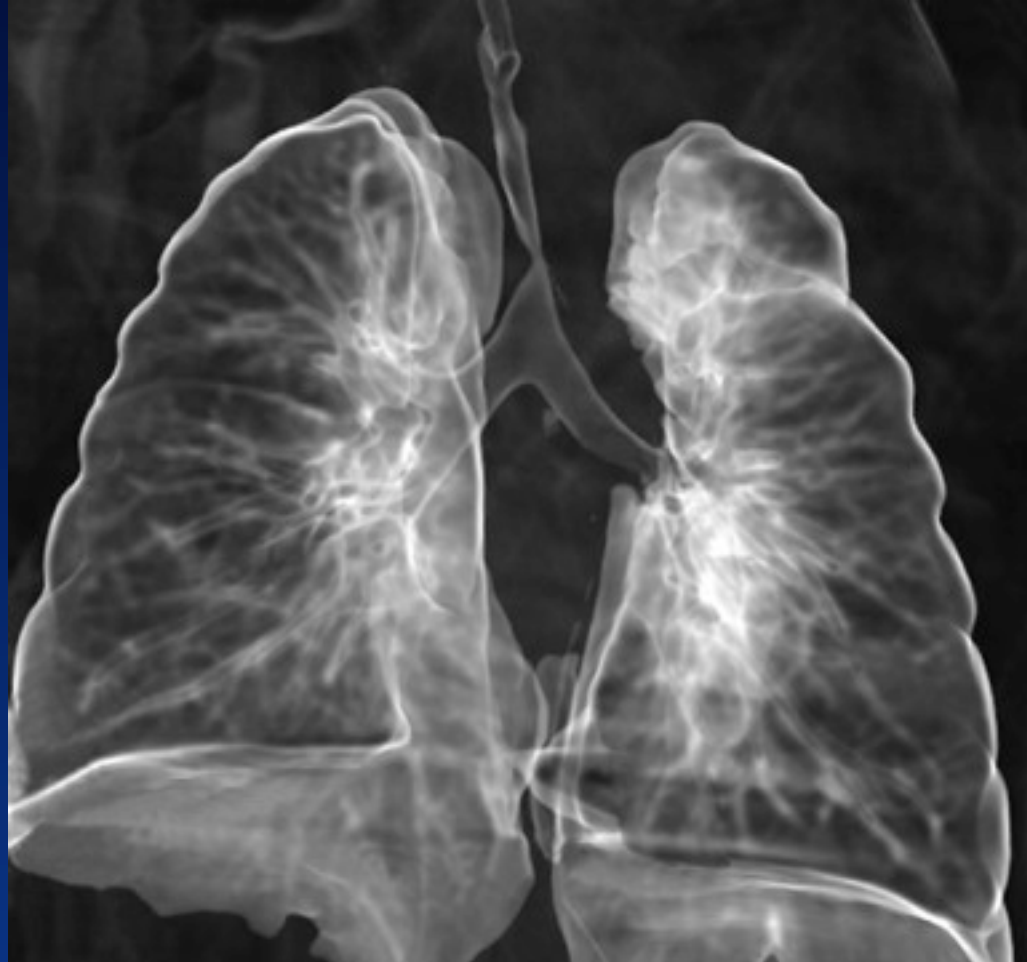
MAPCA's



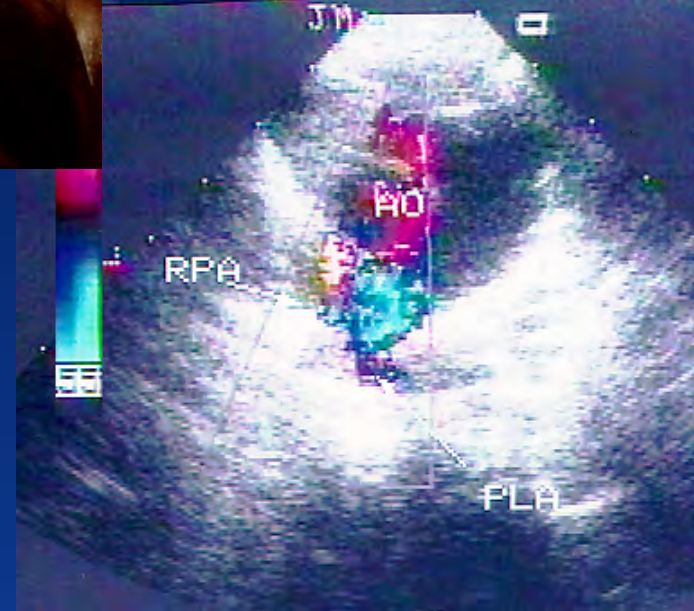
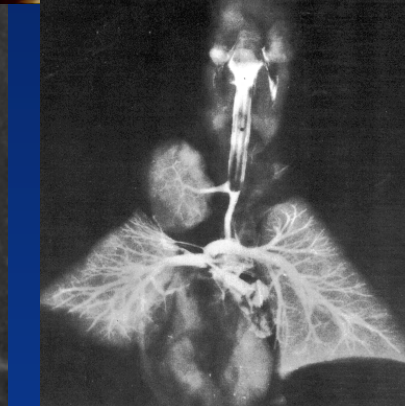
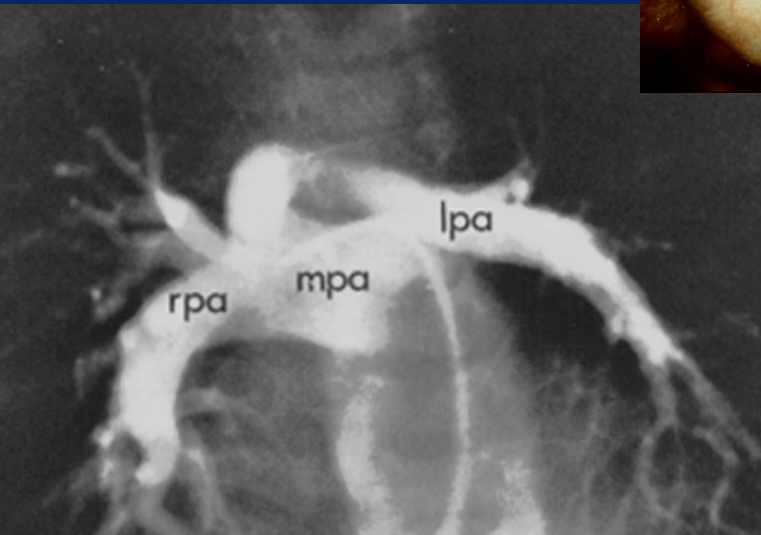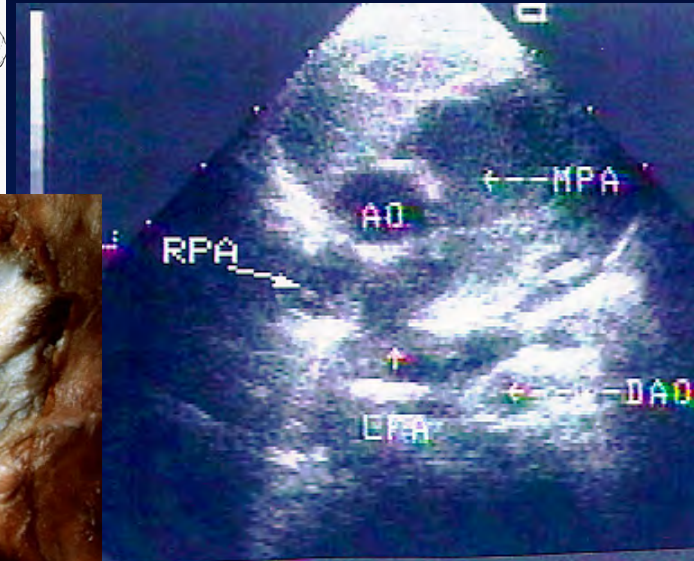
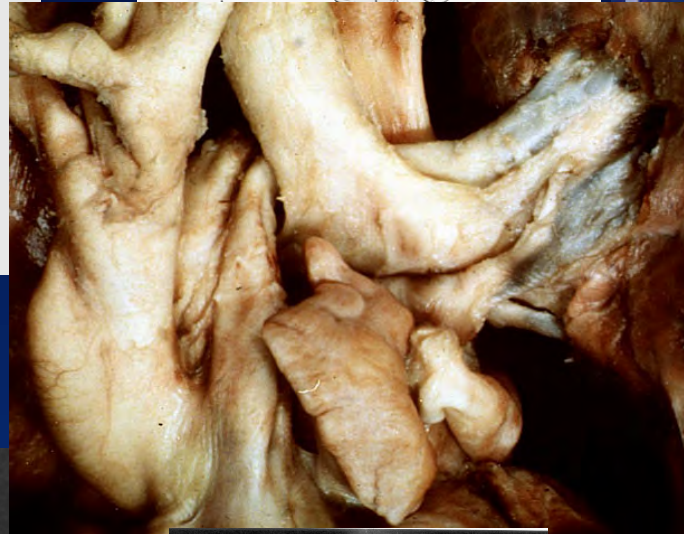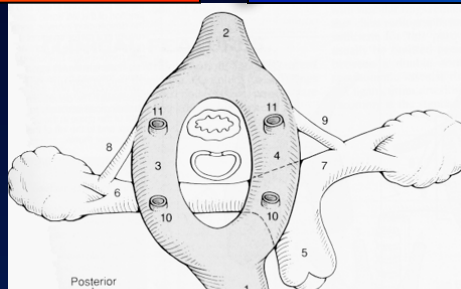
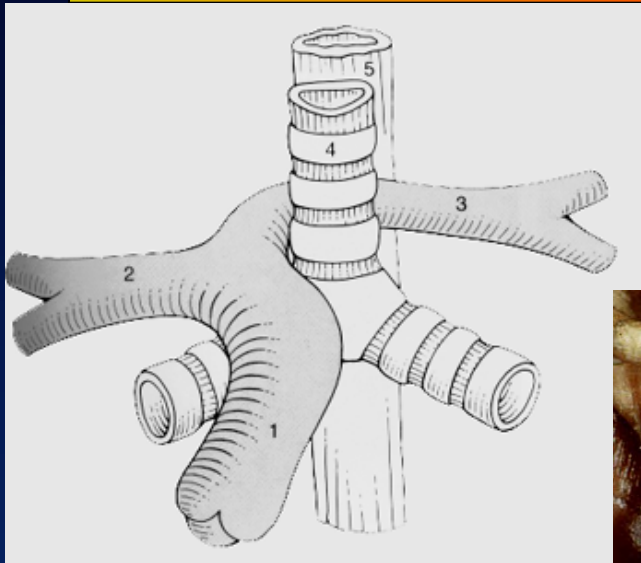
Pulmonary Artery Sling



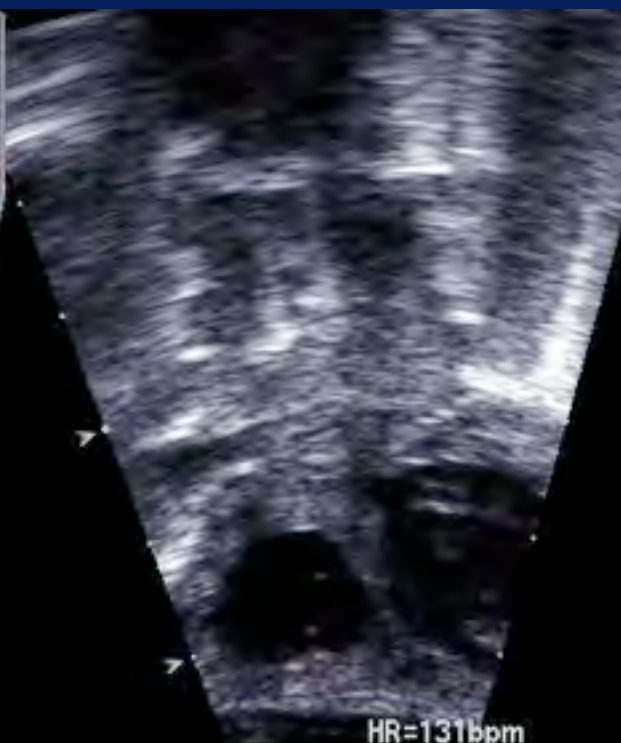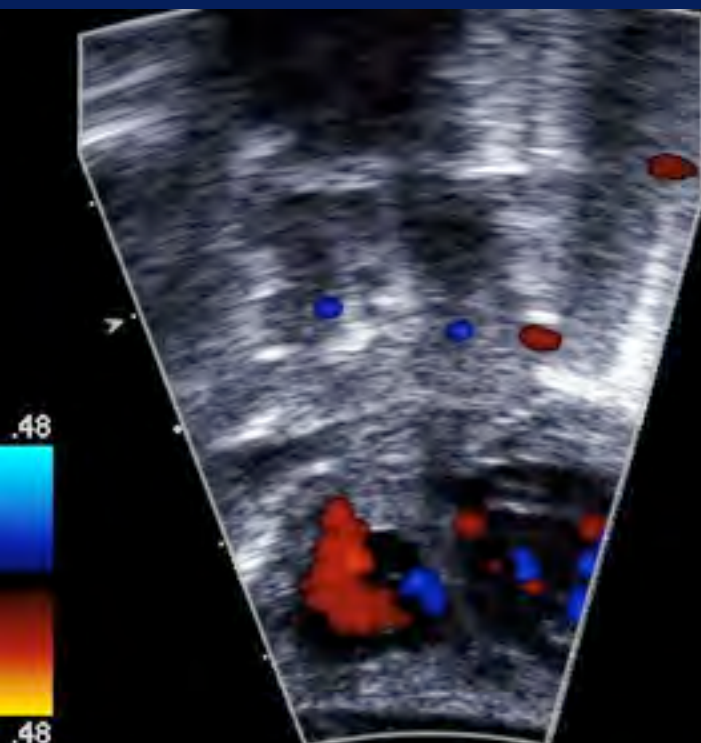
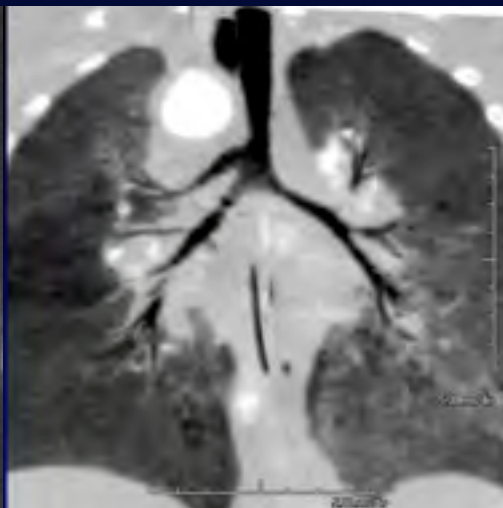
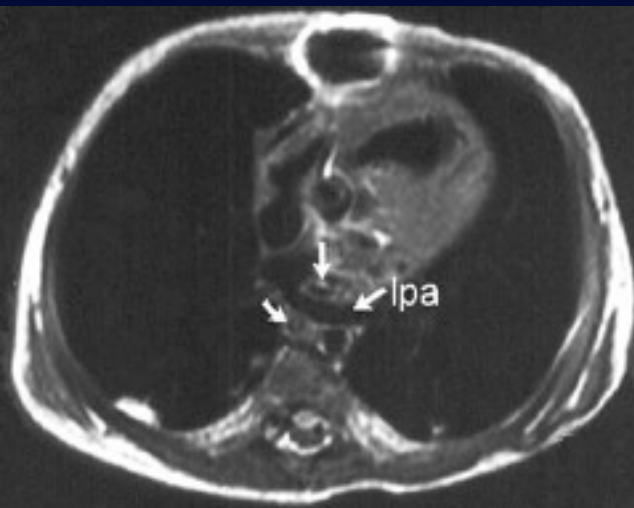
CT Bronchial Tomography



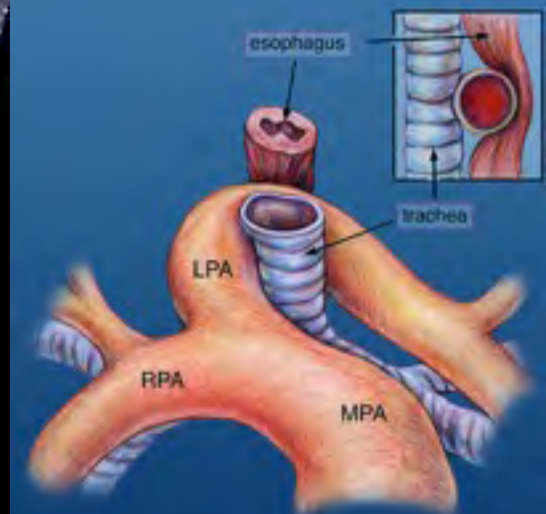
Pulmonary artery Sling ECHO



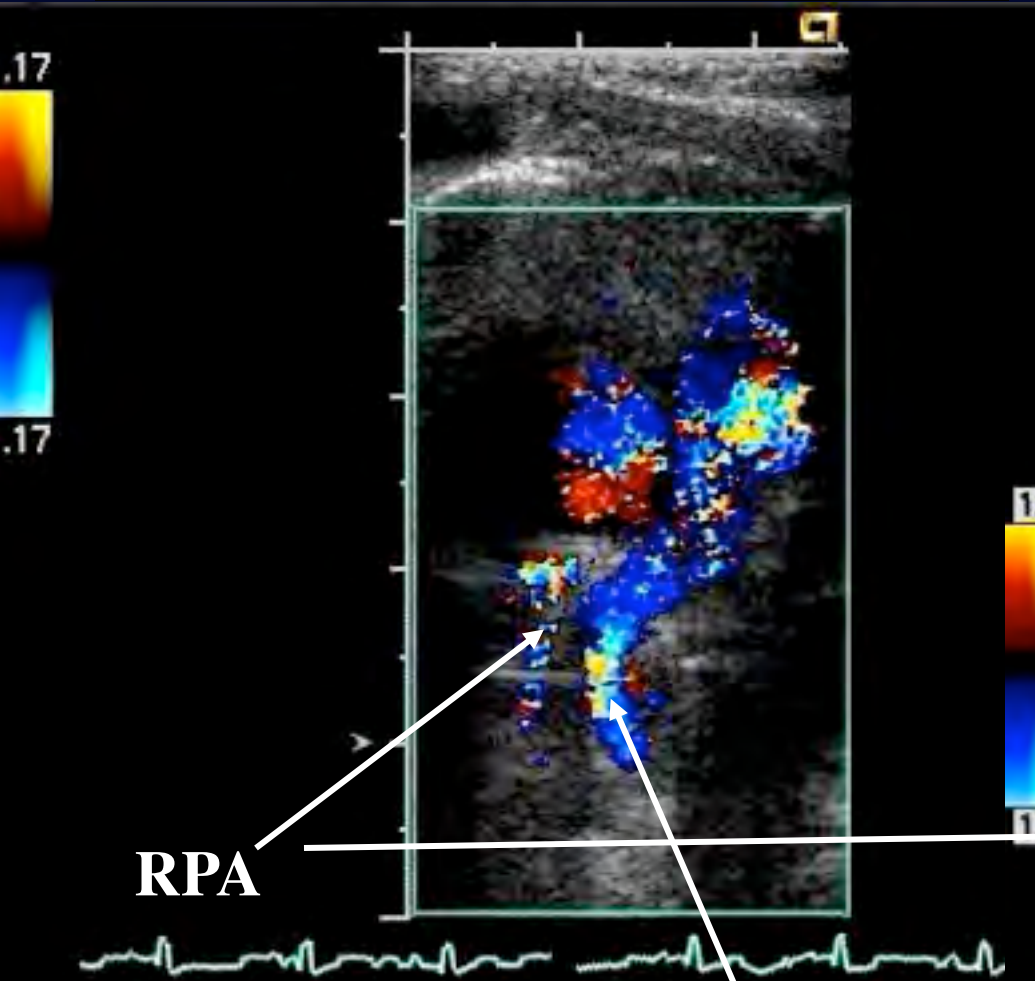
PA Sling



Pulmonary Artery Sling

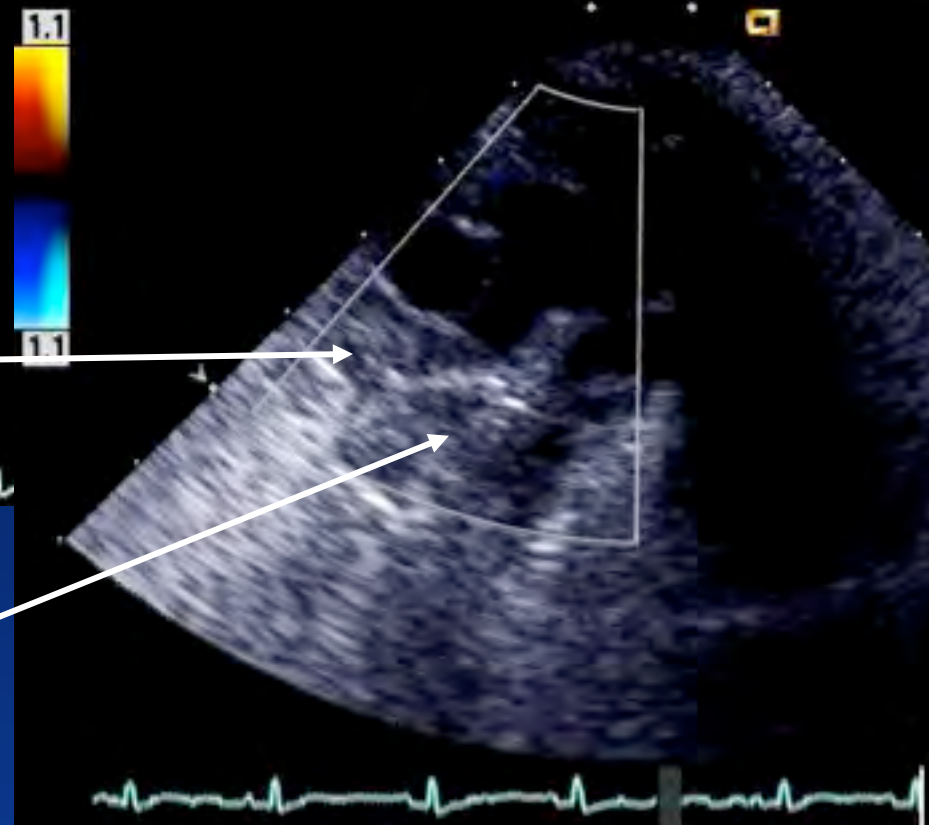
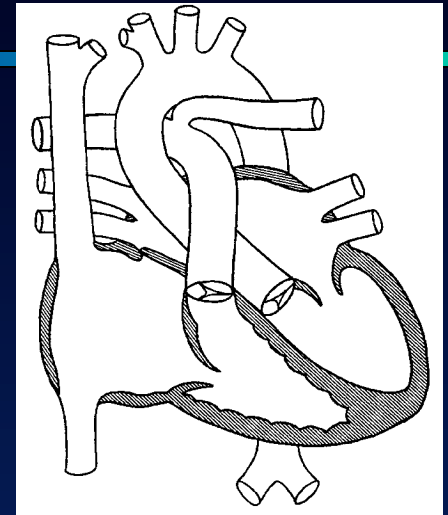


Pulmonary Artery Sling

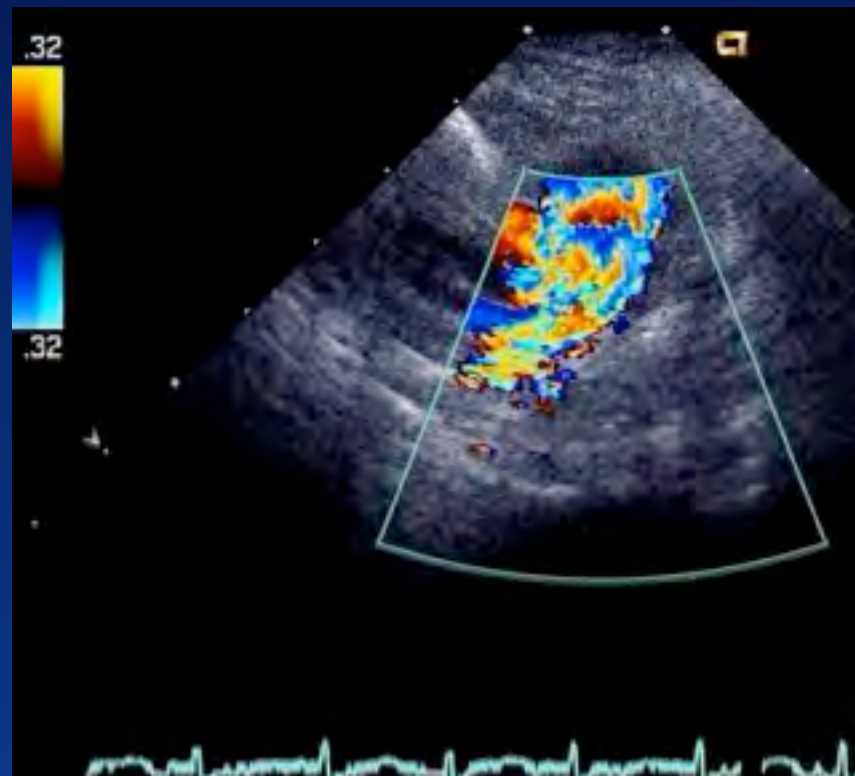
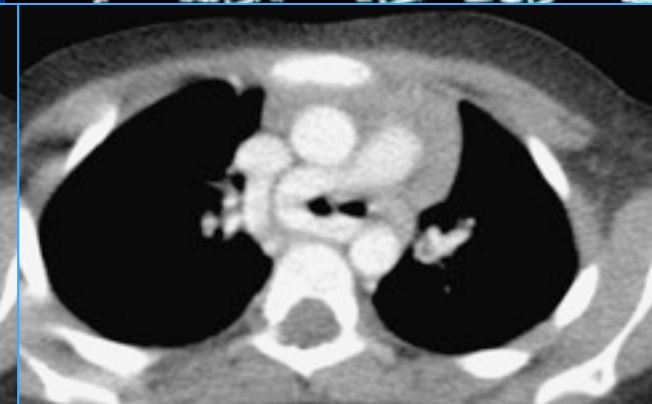
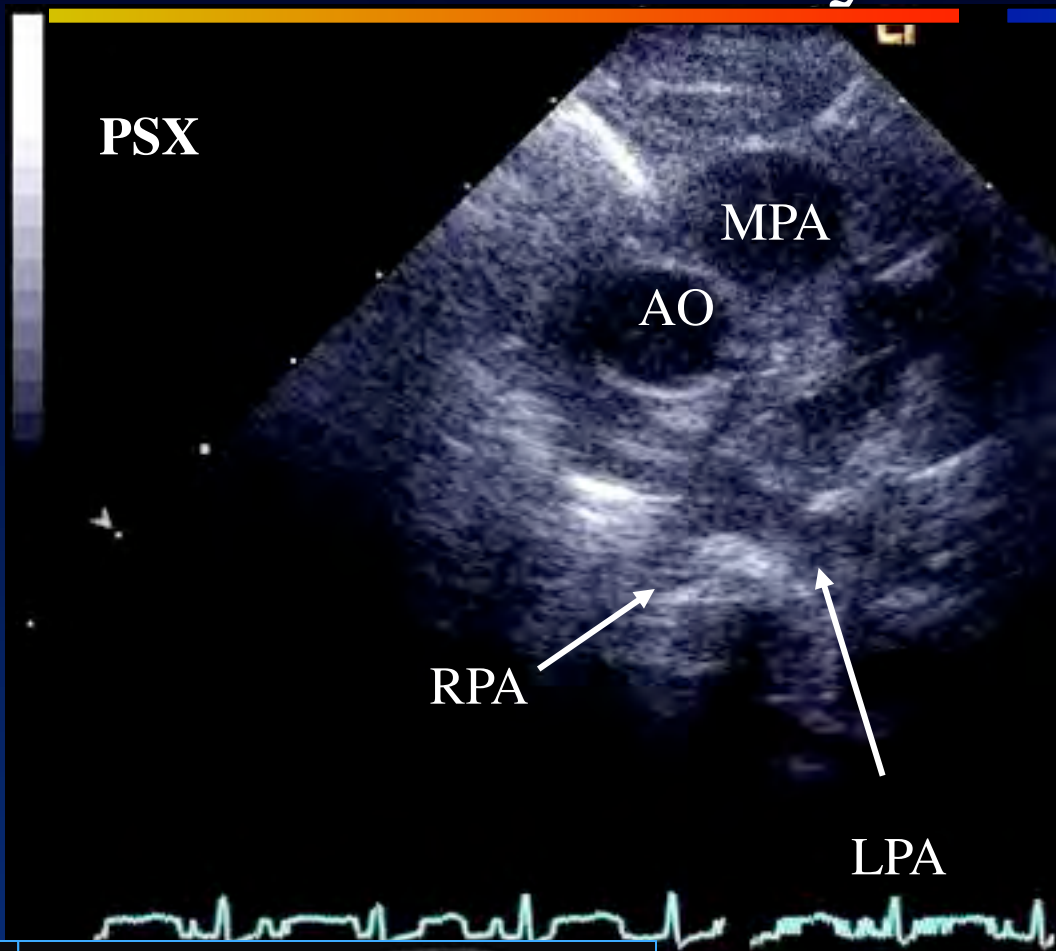


RPA

LPA



Pulmonary Artery Sling





Thank You!

